

Hip and Groin Pain in the Athlete



Seung Jin Yi, M.D.
Orthopaedic Surgery
Sports Medicine



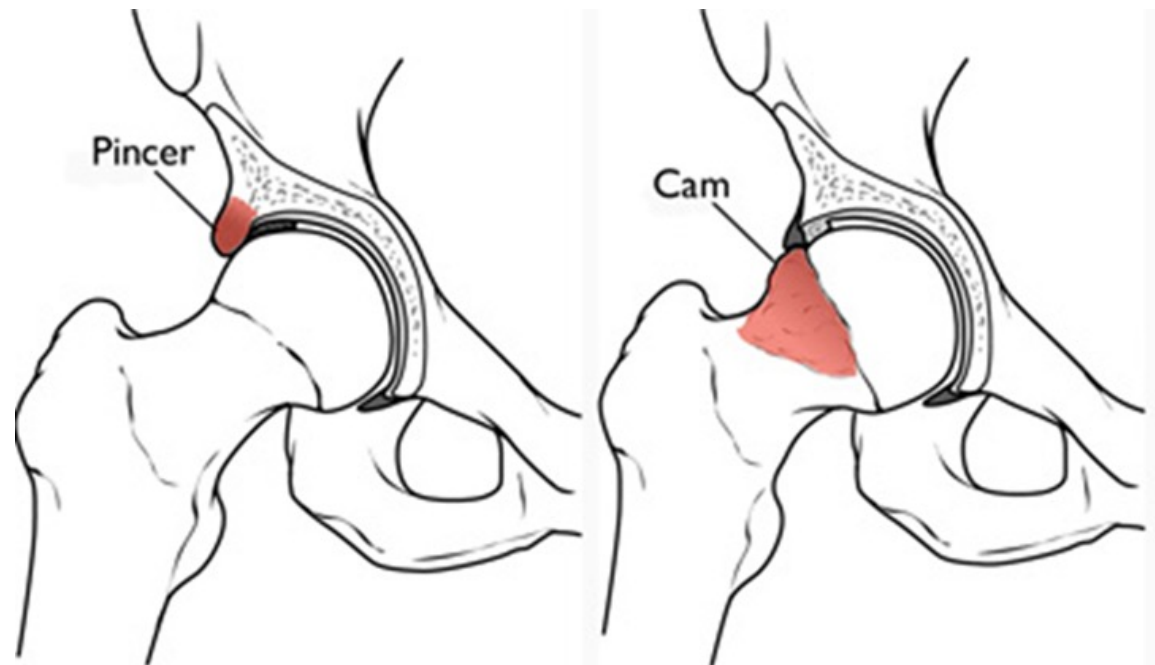
FLORIDA
ORTHOPAEDIC
INSTITUTE®

Keeping you active.

Femoroacetabular Impingement

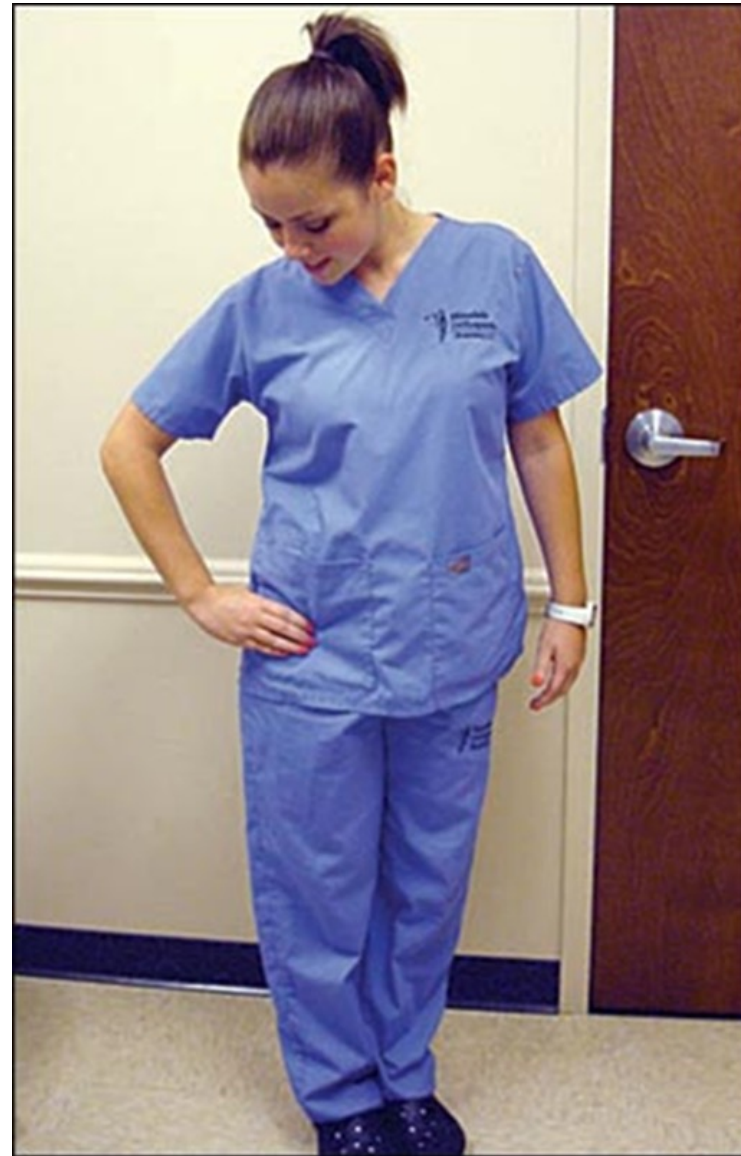Labral tear

- Hip pain with flexion activities
- Hip Impingement
 - femoral neck against anterior edge acetabulum
 - Cam
 - Pincer



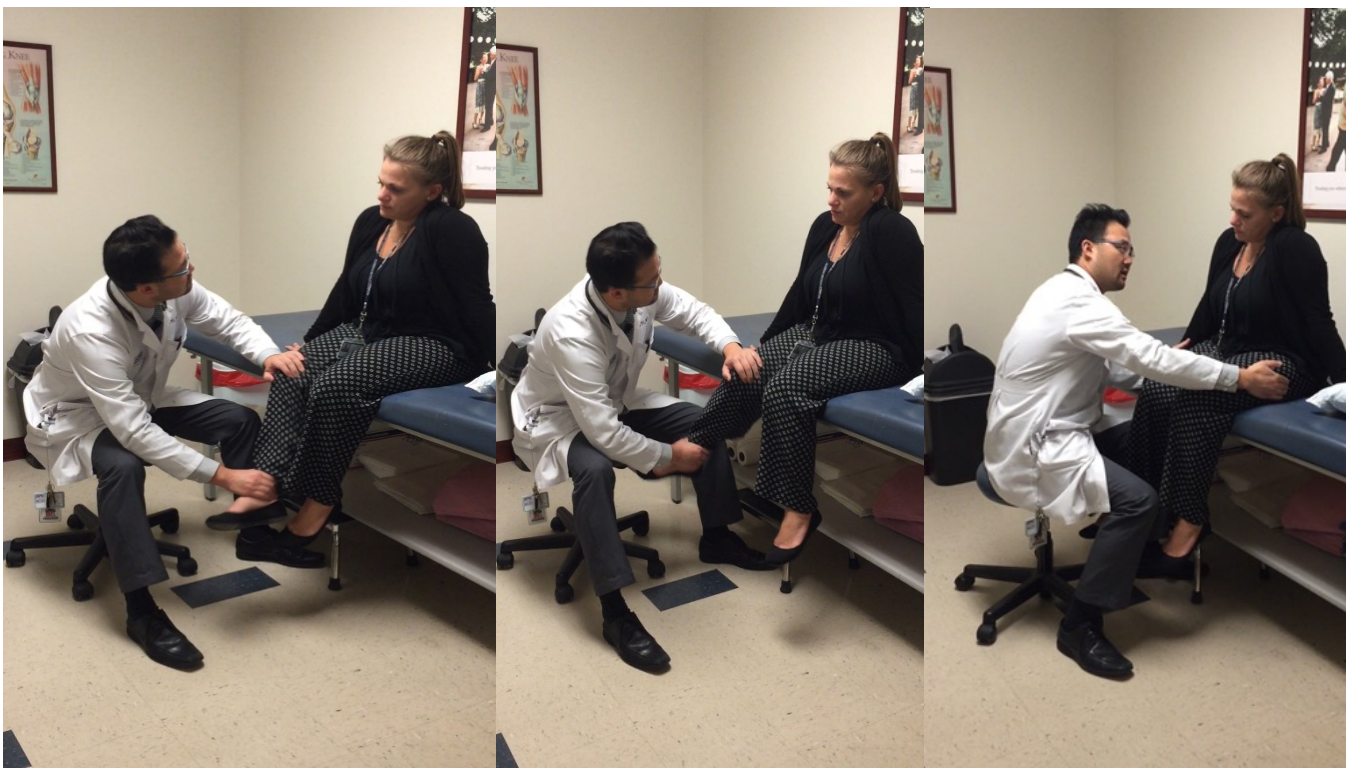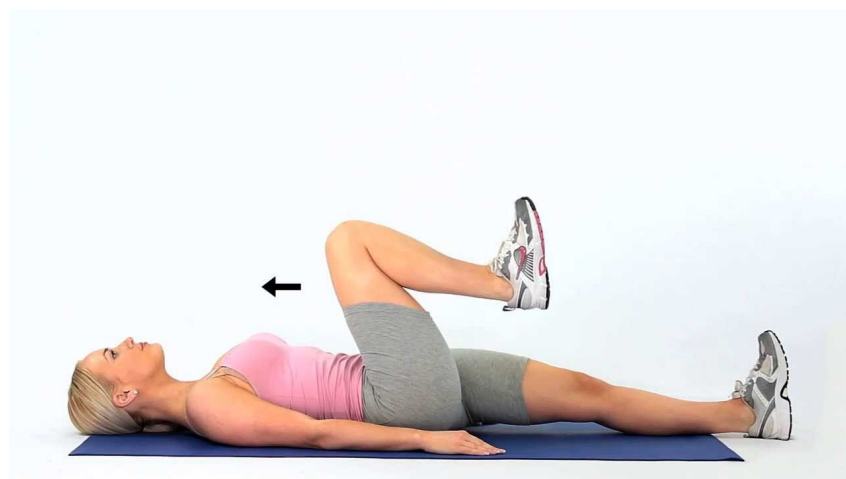Presentation

- C Sign



Physical Exam

- PE
 - Seated ER/IR hip: -
 - Greater troch palpation: -
 - Hip flexion impingement: +

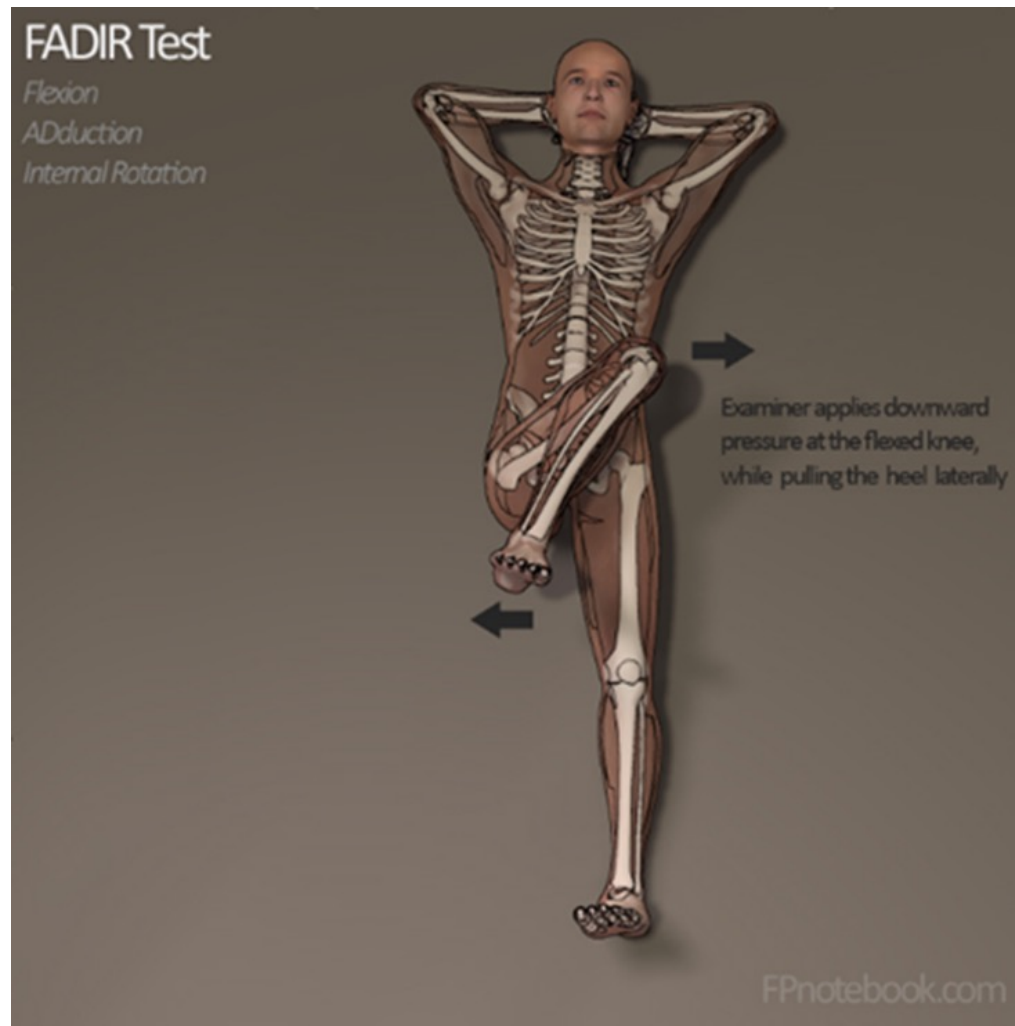

FLORIDA
ORTHOPAEDIC
INSTITUTE®

Keeping you active.

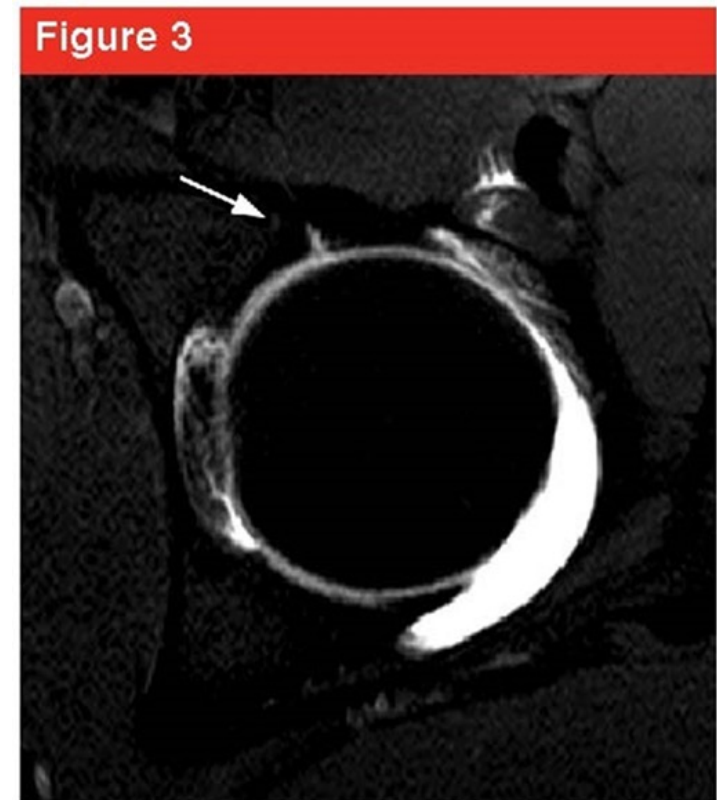
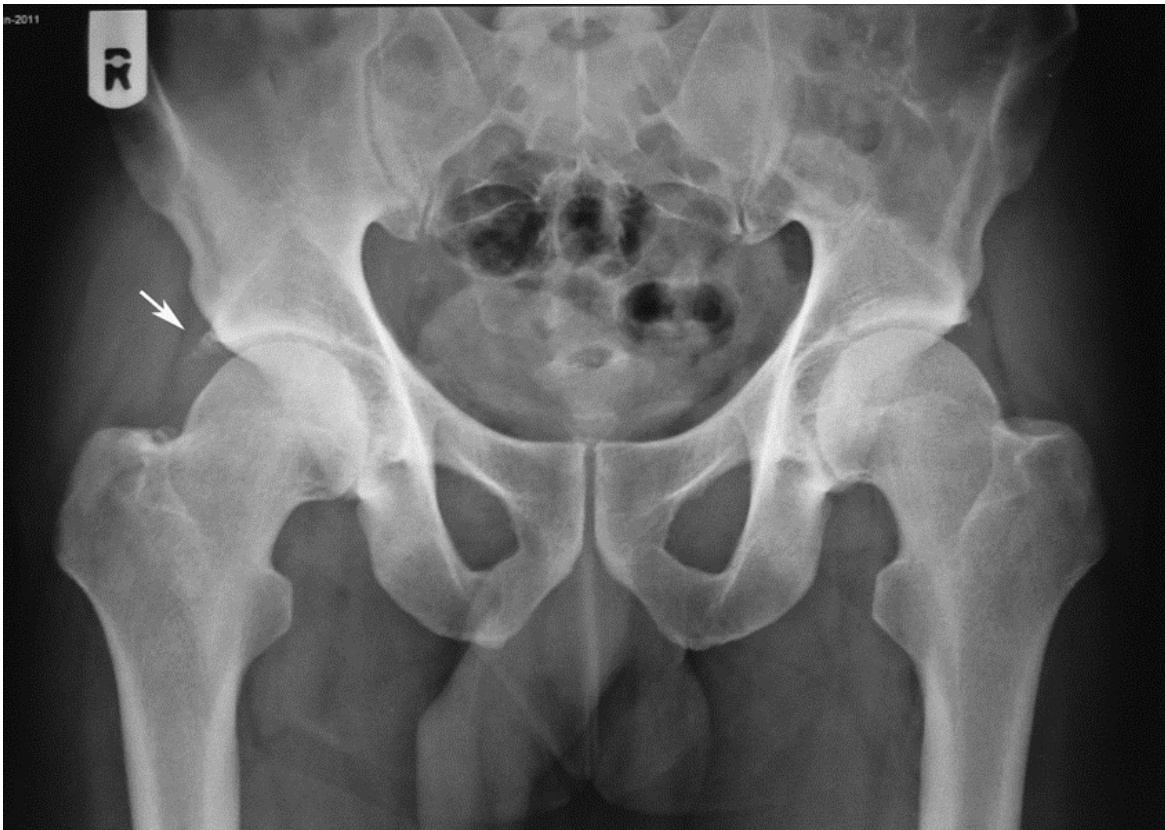Special Exam

- FADIR (Flexion Adduction Internal Rotation)



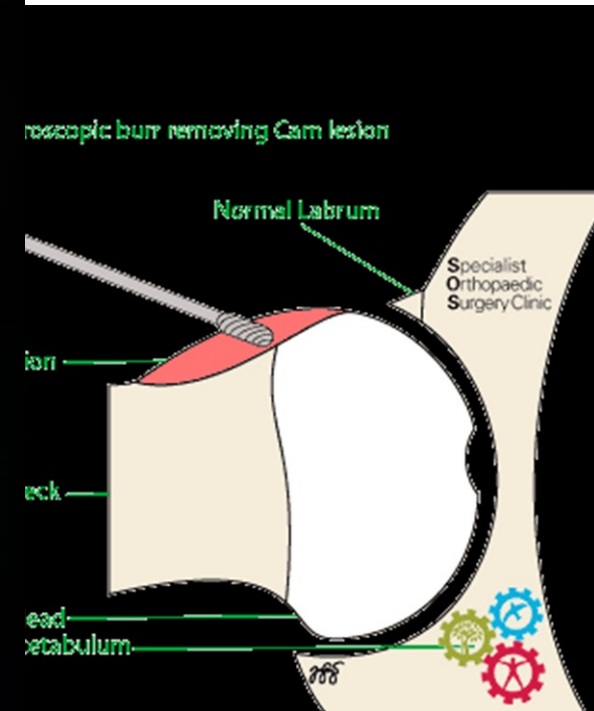
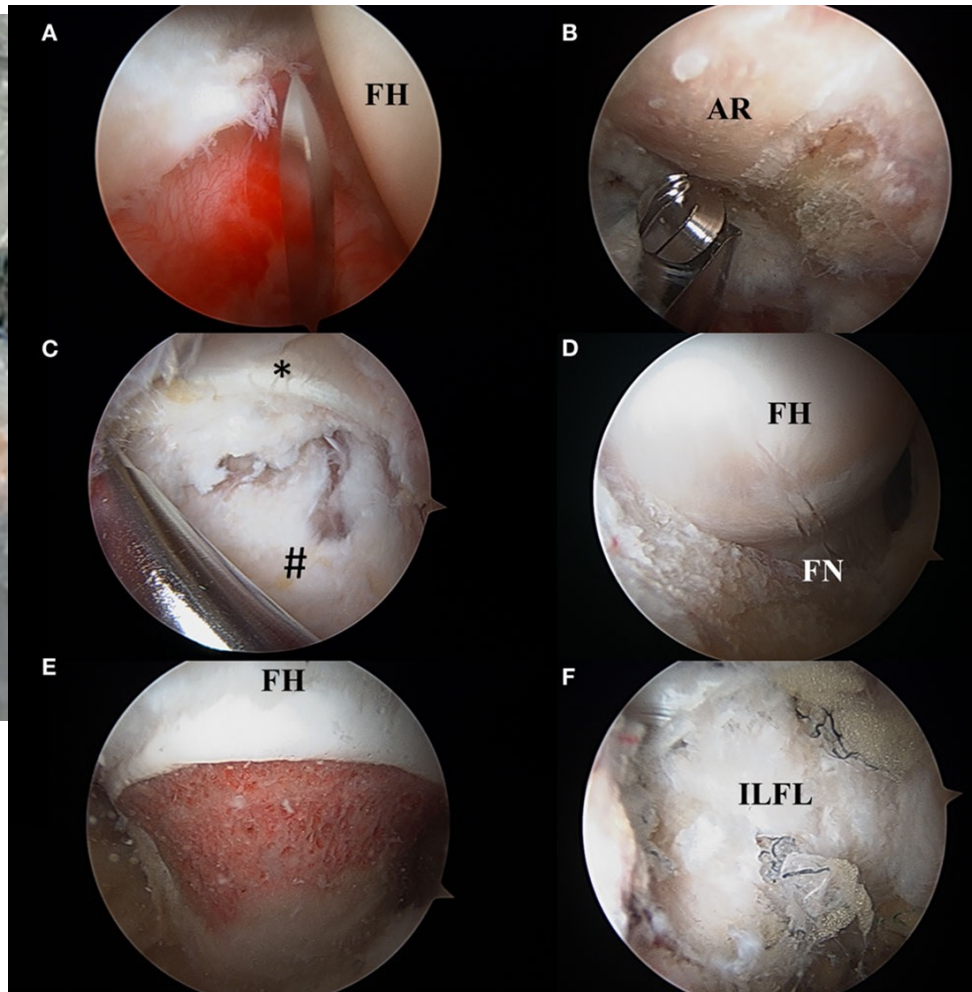
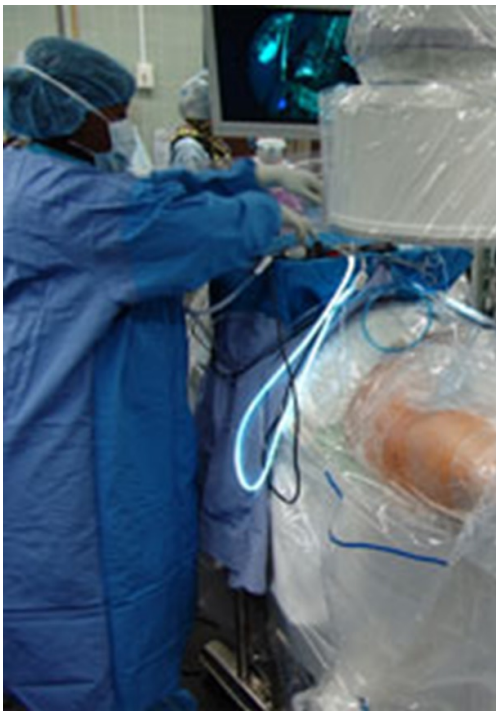Testing

- Xrays show Pincer/Cam Lesion
- MR arthrogram shows labral tear



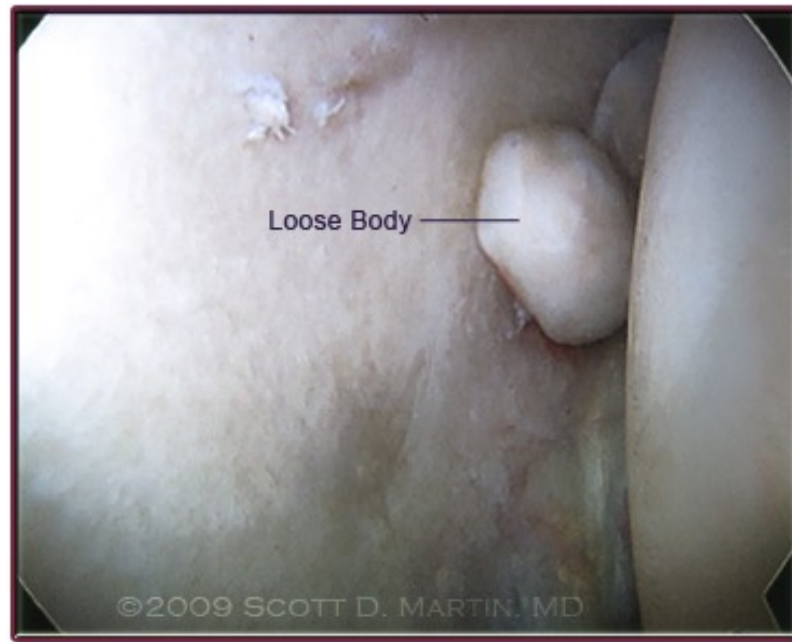- Treatment

- Physical Therapy for Hip stretching, abductor strengthening
- Labral tear repair and Acetabuloplasty, Femoroplasty



Coxa Saltans (Popping Hip)

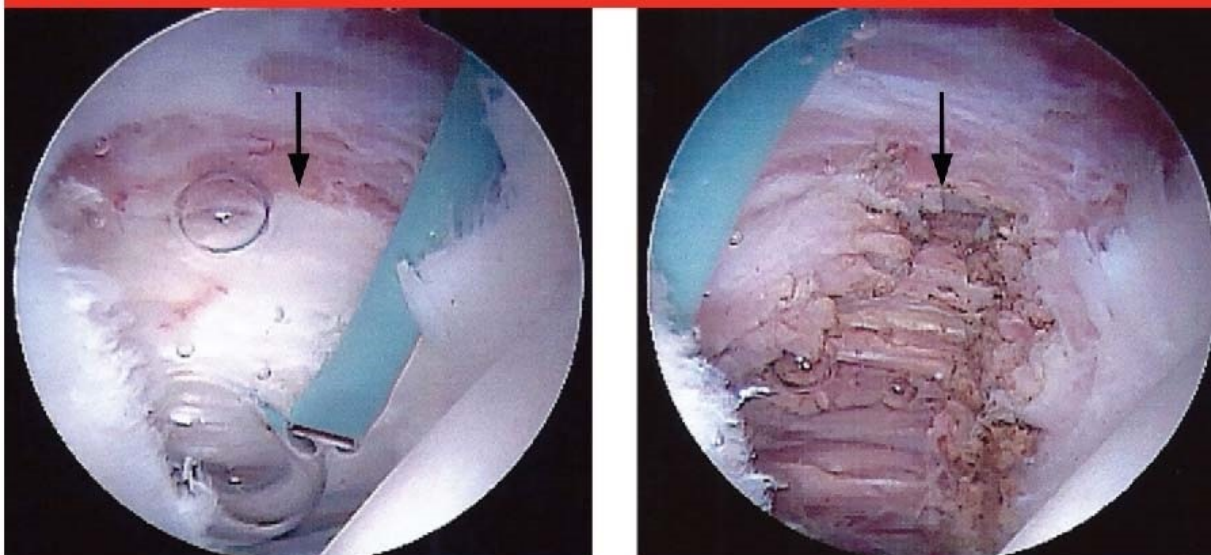
- Intra-articular
 - labral tears, loose bodies, or cartilage flaps



- **Internal (coxa saltans interna)**

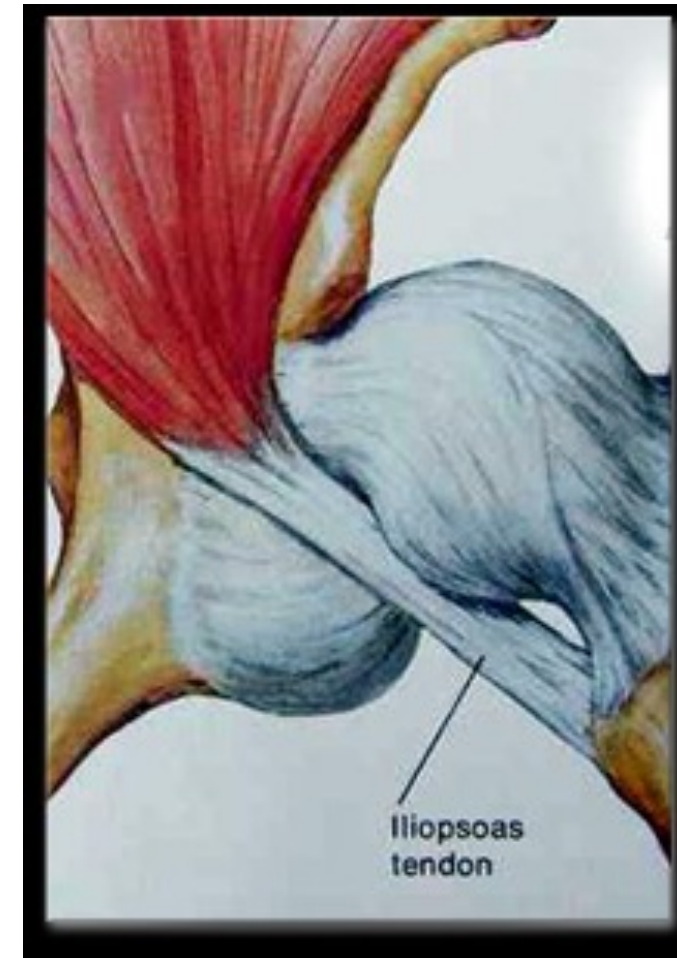
- Iliopsoas tendon snapping over iliopectineal eminence or femoral head
- rest, stretching, and NSAIDs
- corticosteroid injections
- surgical release

Figure 6



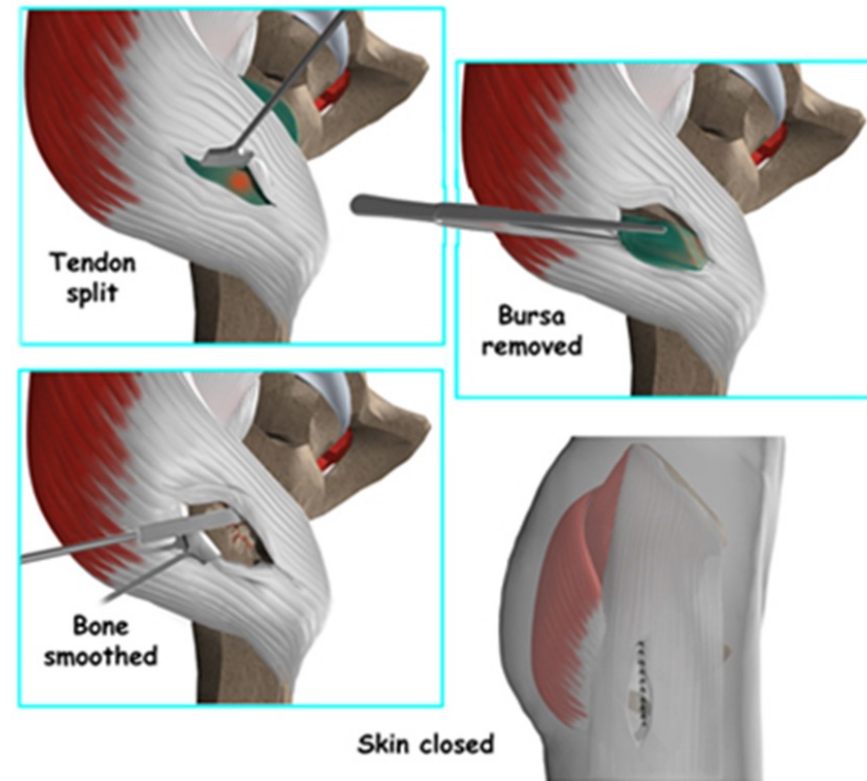
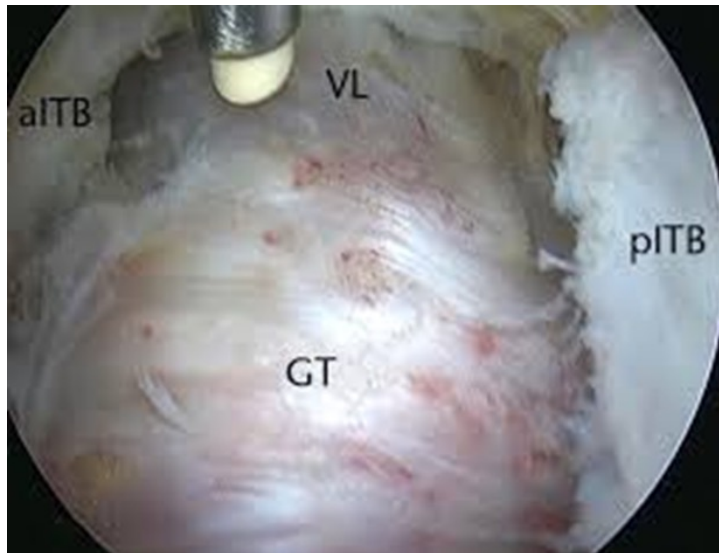
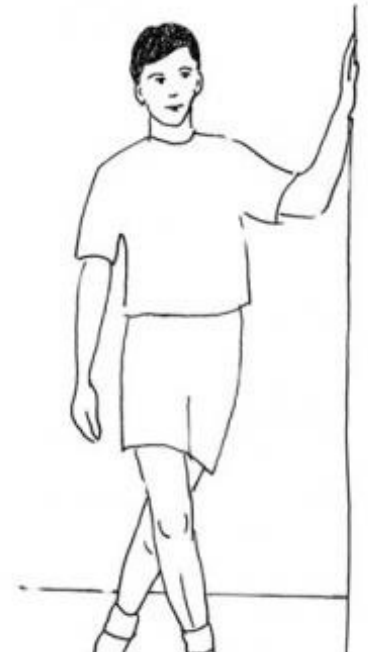
A

B



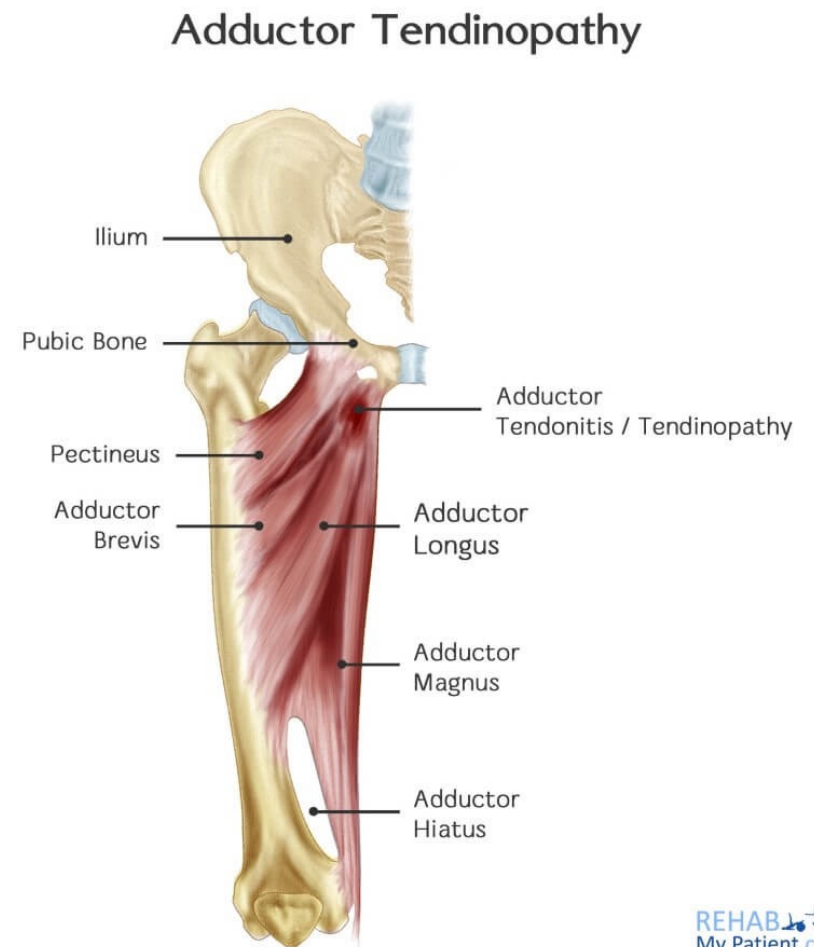
- **External (coxa saltans externa)**

- snapping of the IT band over the greater trochanter.
- going from flexed to an extended position
- stretching, physical therapy, NSAIDs, and corticosteroid injections
- Surgical release



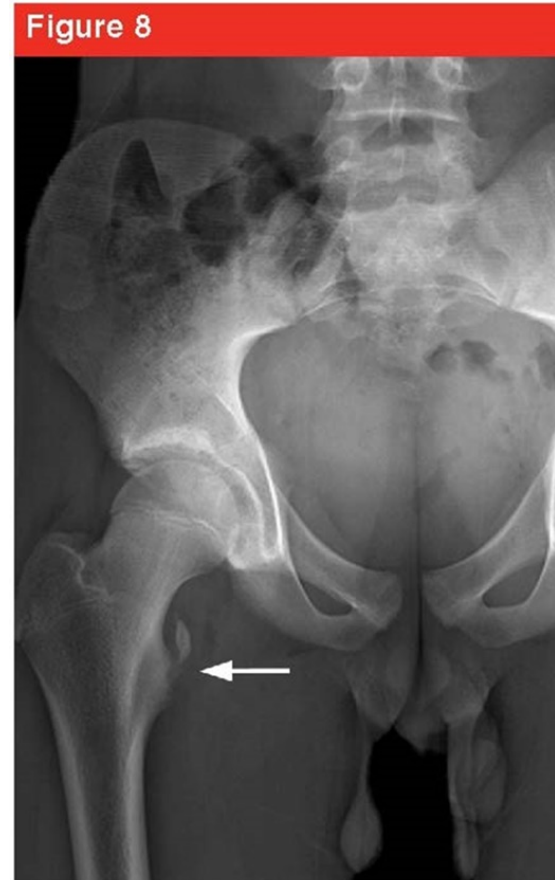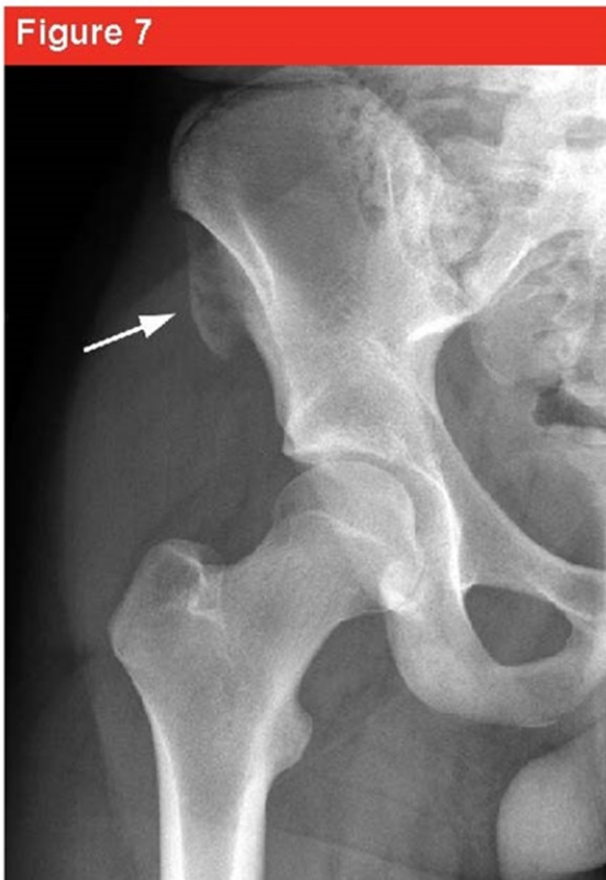Adductor Injuries

- muscular strains and avulsion injuries off the inferior pubic ramus
- Pain with resisted adduction and passive hip abduction
- rest, ice, anti-inflammatory medications, and physical therapy.
- Surgical intervention involving a large bony avulsions.



Apophyseal Avulsion Injuries

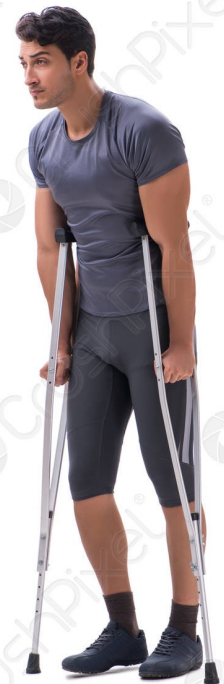- inherent weakness in open physis
- sudden forceful muscular contraction
- acute pain w/ sudden noncontact trauma
- TTP and pain with passive stretch



Apophyseal Avulsion Injuries

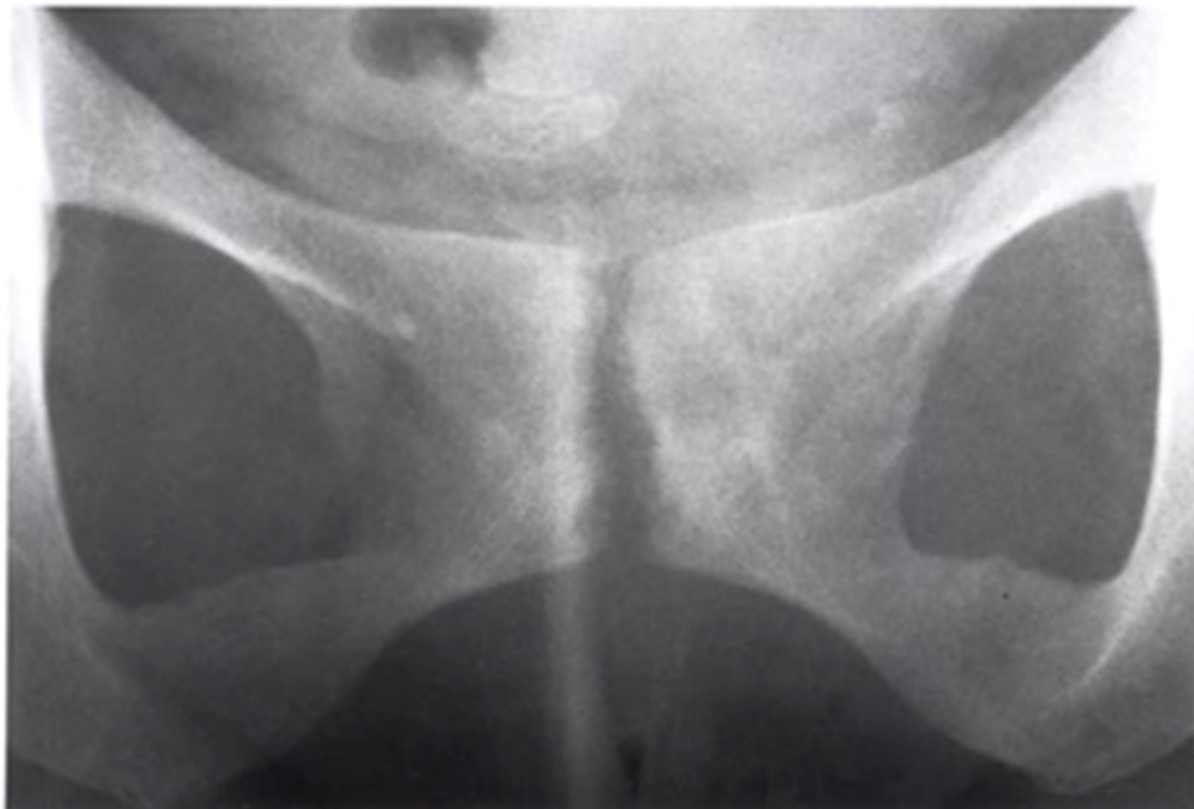Treatment

- rest, ice, use of NSAIDs, and protected weight bearing with crutches
- return to sports once strength and ROM @ preinjury levels



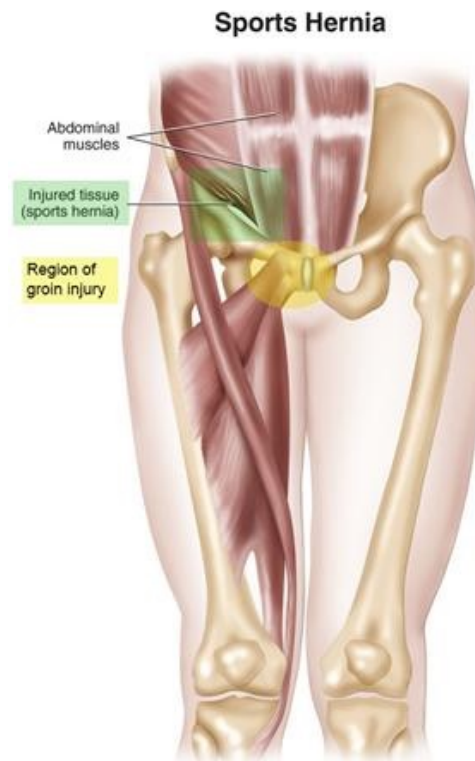
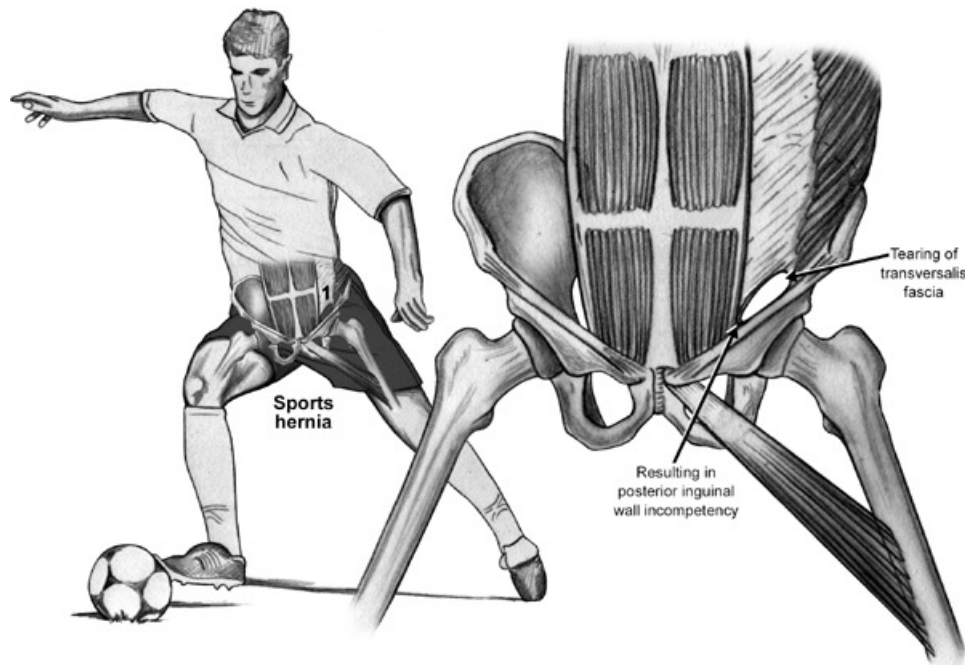
Osteitis Pubis

- inflammatory process about the pubic symphysis
- pain and discomfort over pubic symphysis
- osseous irregularity and widening
- rest, physical therapy, use of NSAIDs, and injections



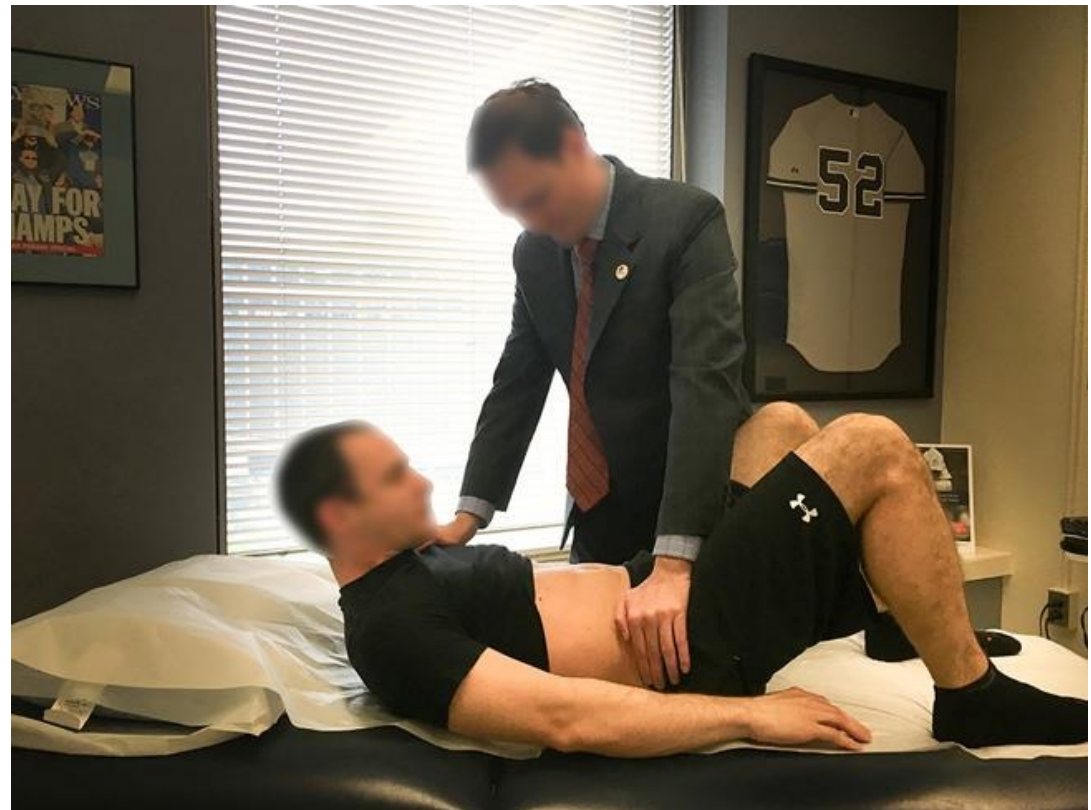Sports Hernias

- Lower abdominal pain and inguinal pain with exertion
- Abdominal hyperextension and thigh abduction injury



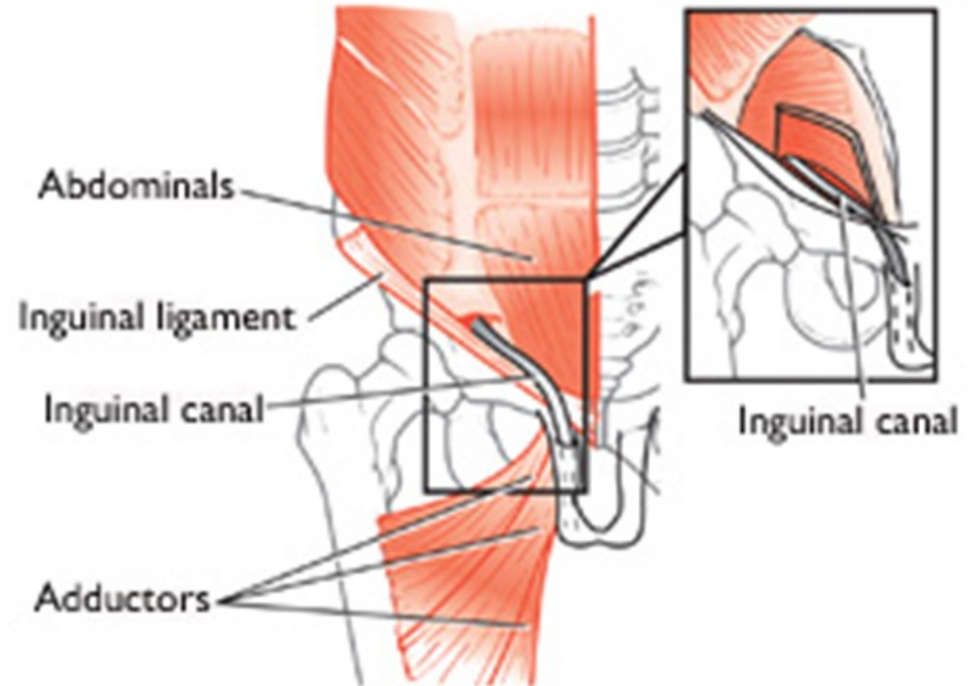
Exam

- Tenderness over inguinal region
- Pain with Valsalva and resisted situps



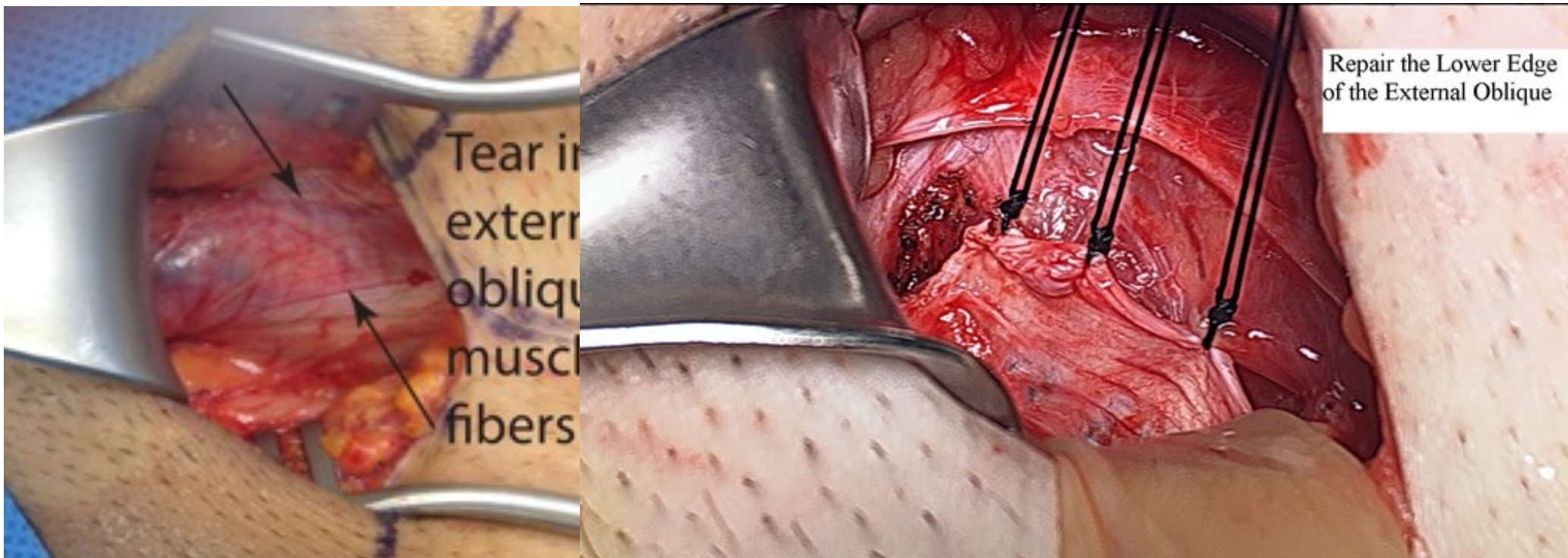
sports hernias

- Traditional hernias
 - occur in the inguinal canal through the natural opening
- Sports hernias
 - occur with a tear or weakening of the canal floor.



Treatment

- Rest, ice, activity modification, PT
- Surgery
 - Transversalis fascia repair, adductor/rectus recession
 - Decompression of genital branch of genitofemoral



Questions

