



Debate #2: Massive Cuff Tear- Muscle Transfer Lower Trap vs Partial Repair

Matthew J. Teusink, MD
Assistant Professor

Department of Orthopaedic Surgery
University of Nebraska Medical Center





Disclosures

Consultant- DJO Surgical
Honoraria – Springer SBM



Debaters



Grant Garrigues, MD
Lower Trapezius Transfer



John D. Kelly, IV, MD
Partial Repair



Case

- 44 year old RHD laborer
 - Injured shoulder at work when truck tire he was repairing exploded
 - Right shoulder dislocation and right forearm fractures
 - Initially thought to have brachial plexopathy, EMG normal
 - 1 year later presents with right shoulder weakness and limited ROM
 - Minimal pain

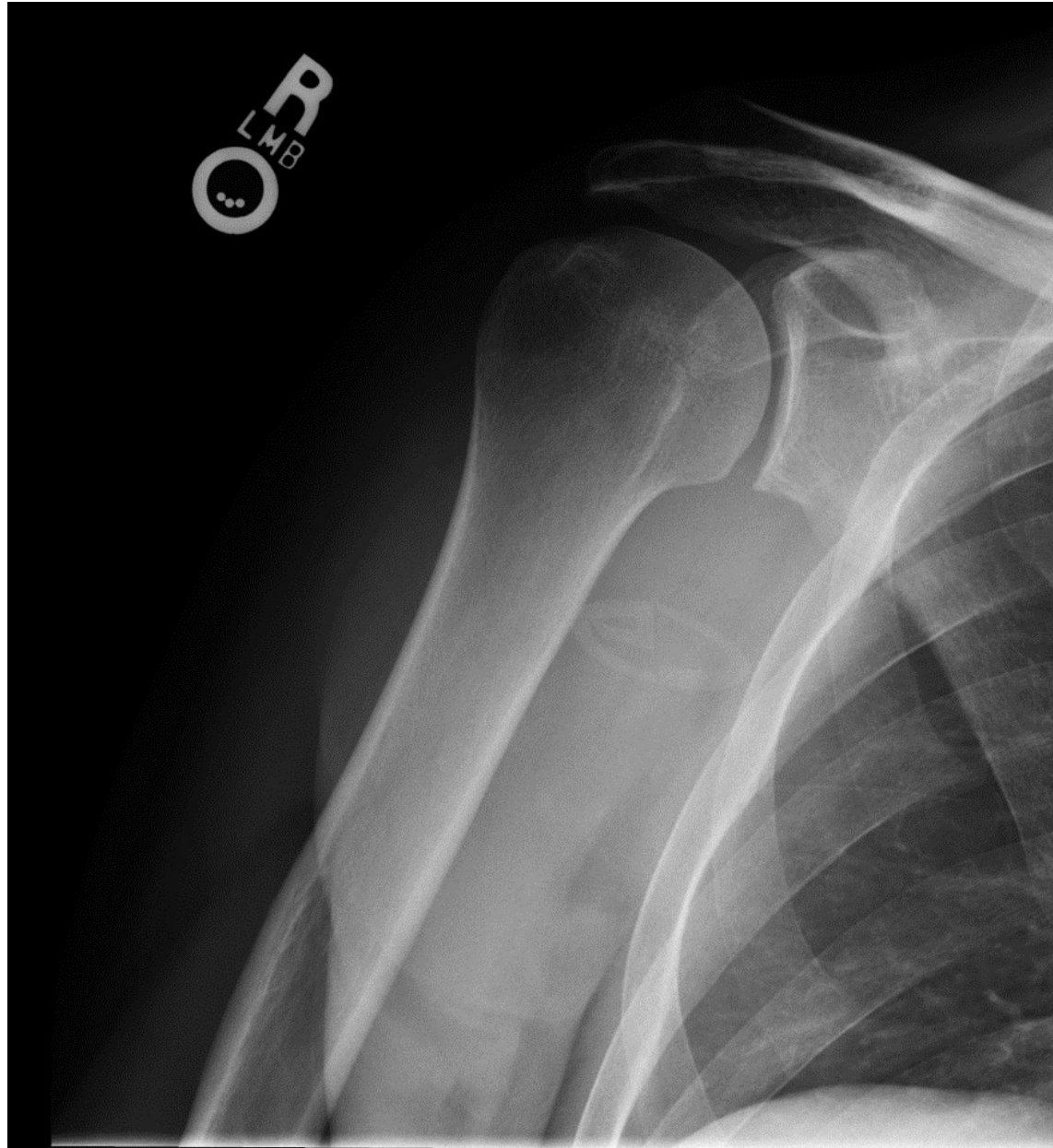

Case

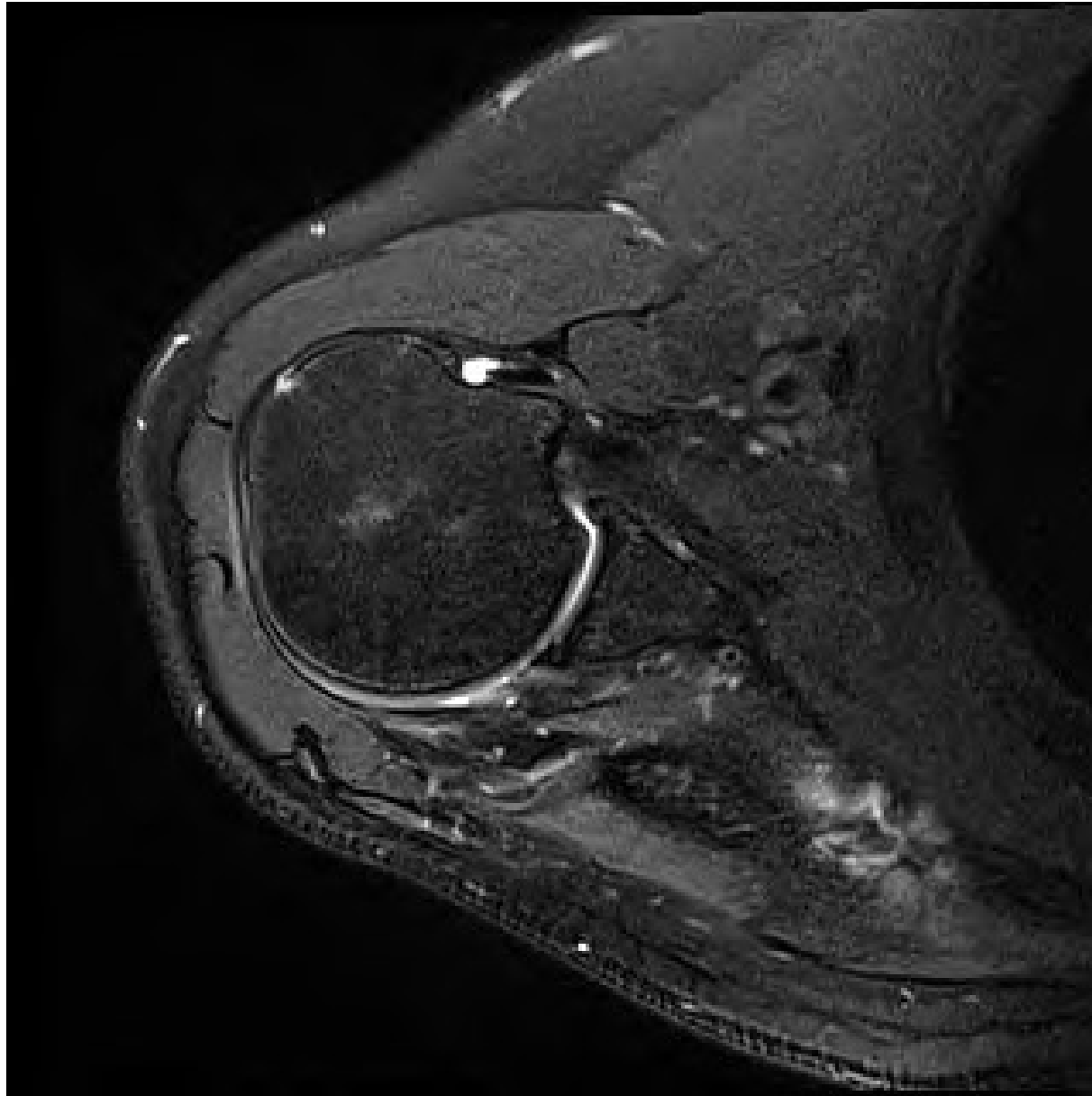
- Exam
 - Mild atrophy of deltoid, supraspinatous and infraspinatous fossa
 - Active elevation 120, passive elevation 140
 - Active ER 10, passive ER 30
 - IR to L1
 - 4/5 strength supraspinatus, 4/5 ER at side
 - Negative Hornblowers
 - NVI distal



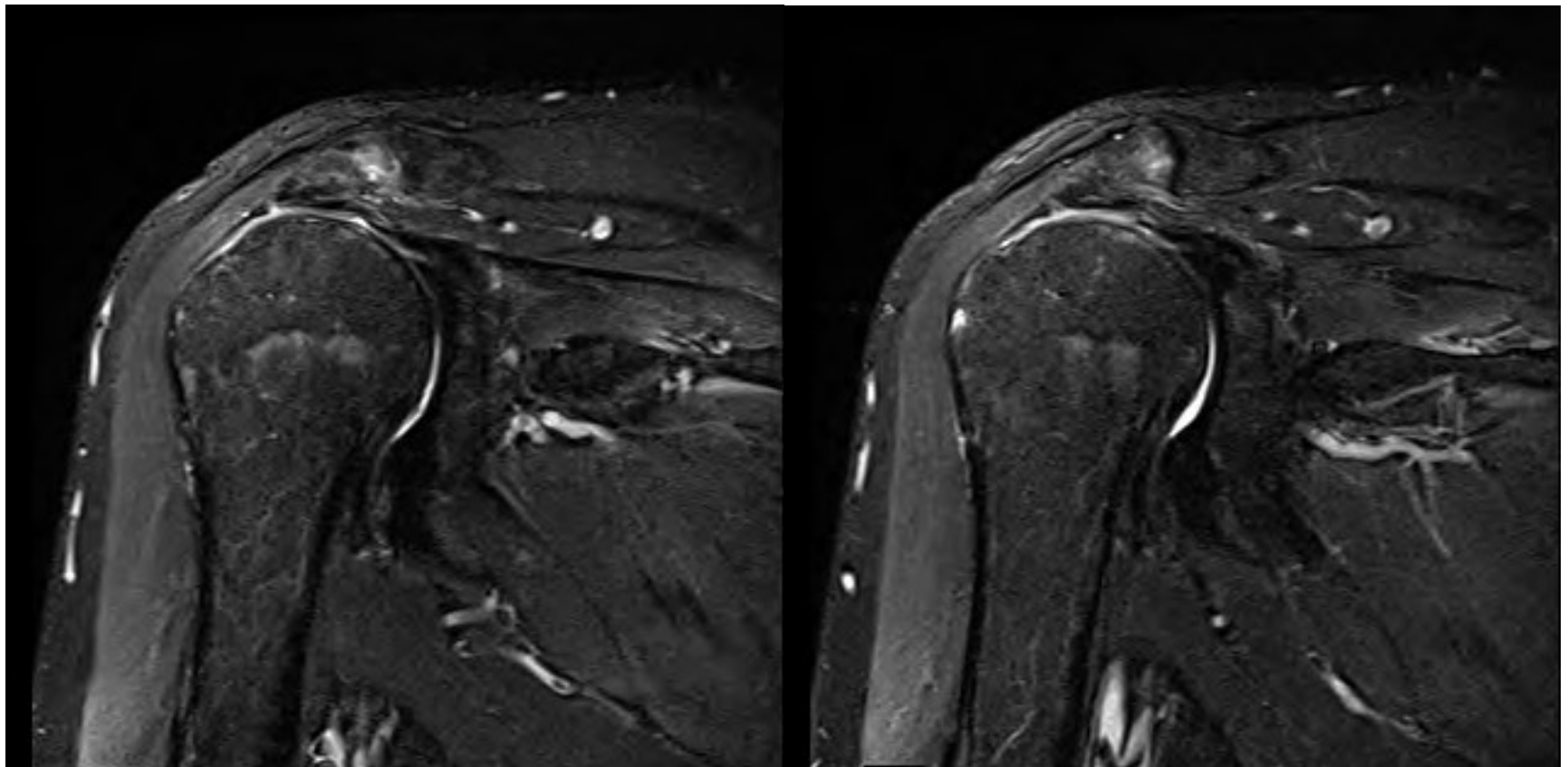
Imaging



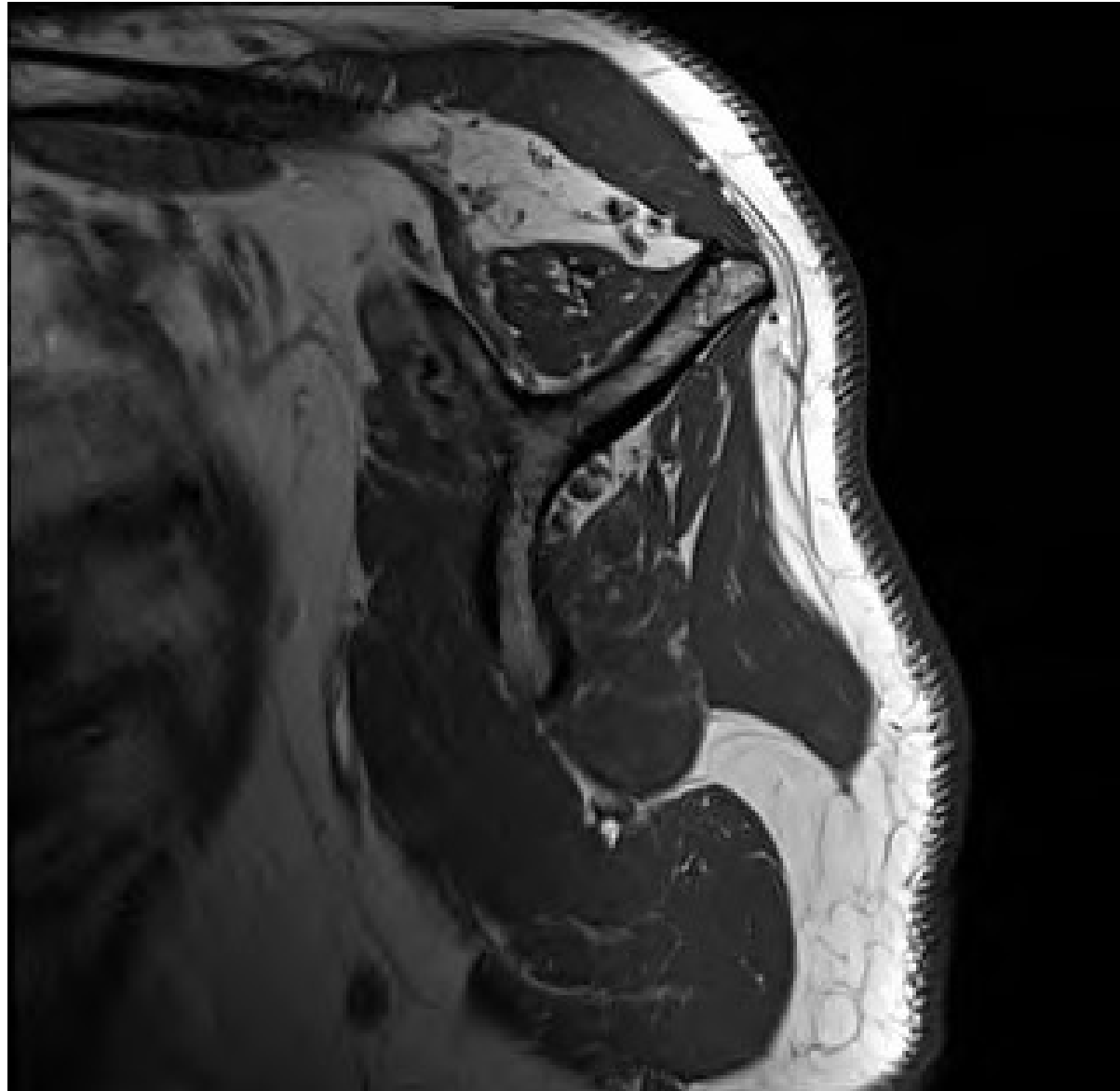
Imaging



Imaging



Imaging



Lets Get it On!

