

26TH ANNUAL
TAMPA
SHOULDER COURSE
ARTHROPLASTY & SPORTS



Tampa Marriott Waterside Hotel | Tampa, FL

Case #2

Massive Rotator

Cuff Tear

George S. Athwal, MD, FRCSC
Professor of Surgery

ROTH | MCFARLANE
HAND & UPPER LIMB CENTRE
ST. JOSEPH'S HEALTH CARE LONDON

26TH ANNUAL
TAMPA
SHOULDER COURSE
ARTHROPLASTY & SPORTS



EPIC BATTLES



Schulich
MEDICINE & DENTISTRY


HULC Shoulder



EPIC BATTLES



EPIC BATTLES

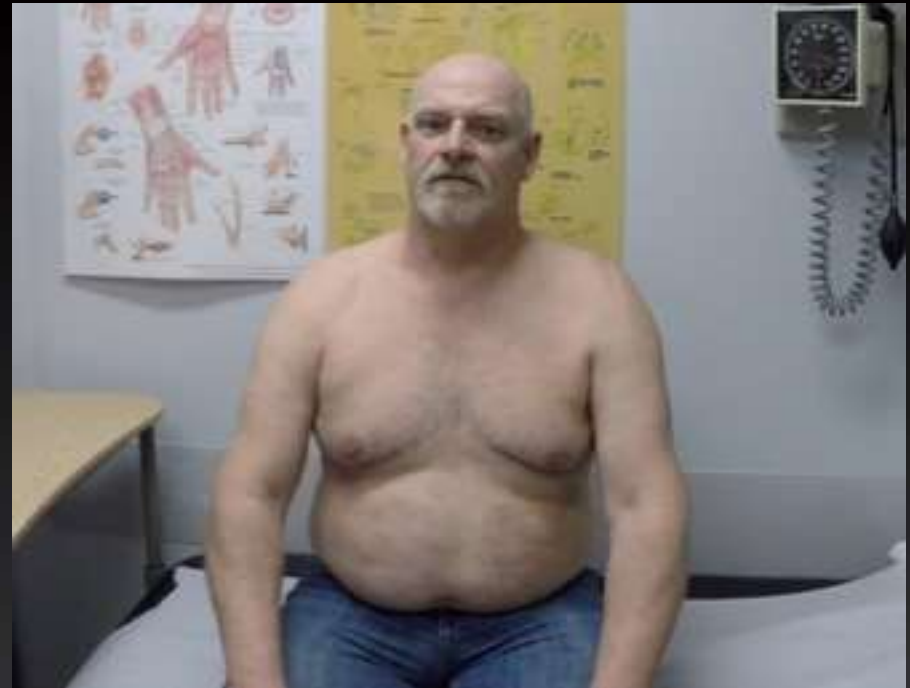

Debridement
Biceps Tenotomy/Tenodesis
Partial Rotator Cuff Repair
Interposition Graft
Superior Capsular Reconstruction
Subacromial Balloon
Latissimus Dorsi Tendon Transfer
Lower Trapezius Transfer
Reverse Shoulder Arthroplasty



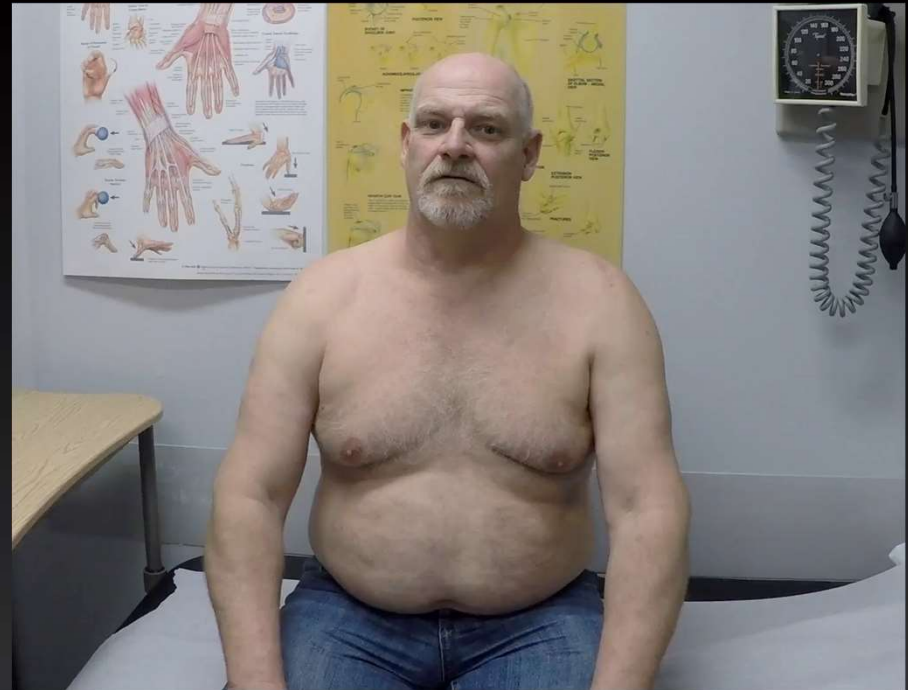54 YEAR OLD MALE

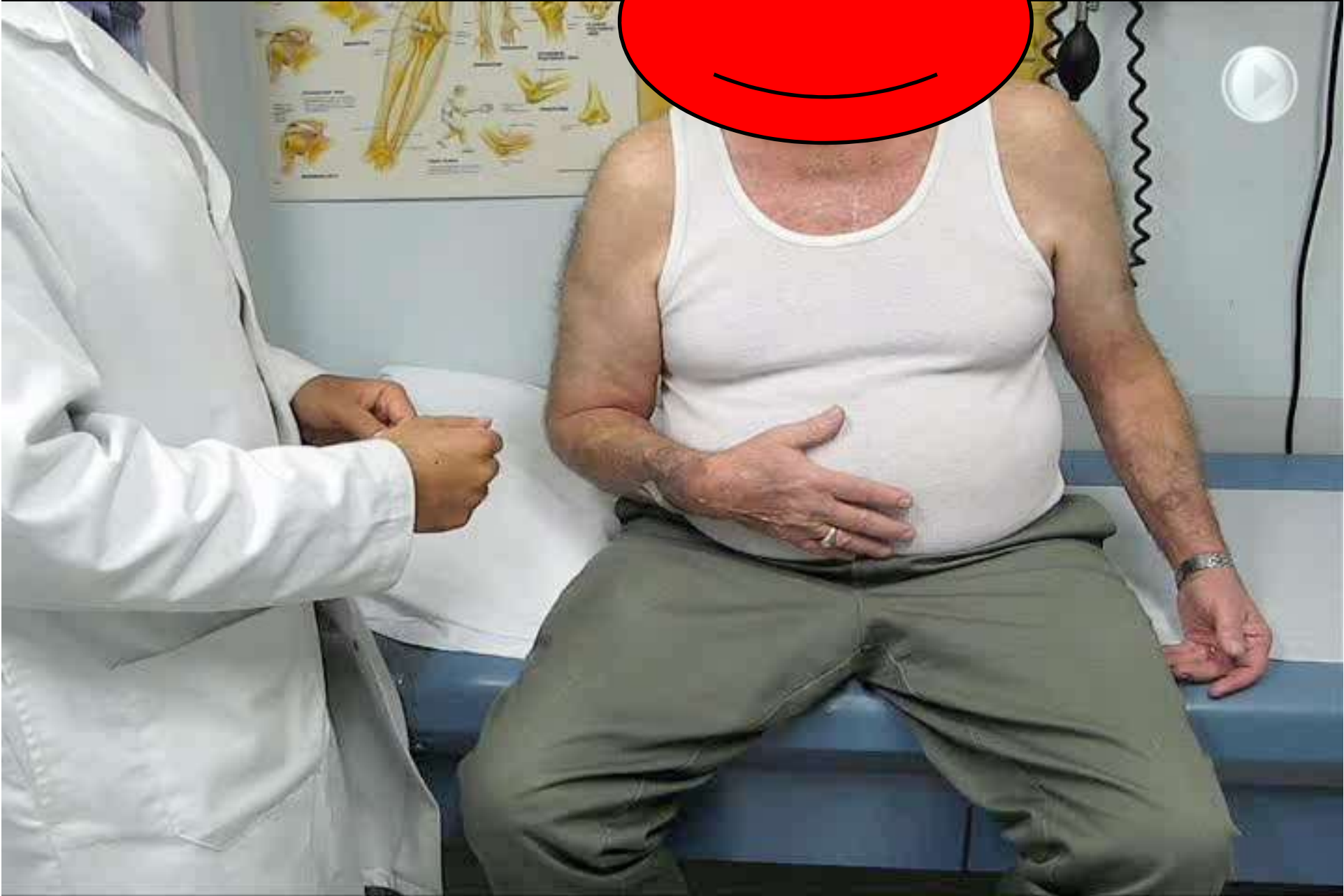- Rt shoulder pain
- Prior RCR repair
- CC:
 - Pain
 - Lack of function
- Past Medical
 - HTN & Cholesterol
 - DM
 - Smoke

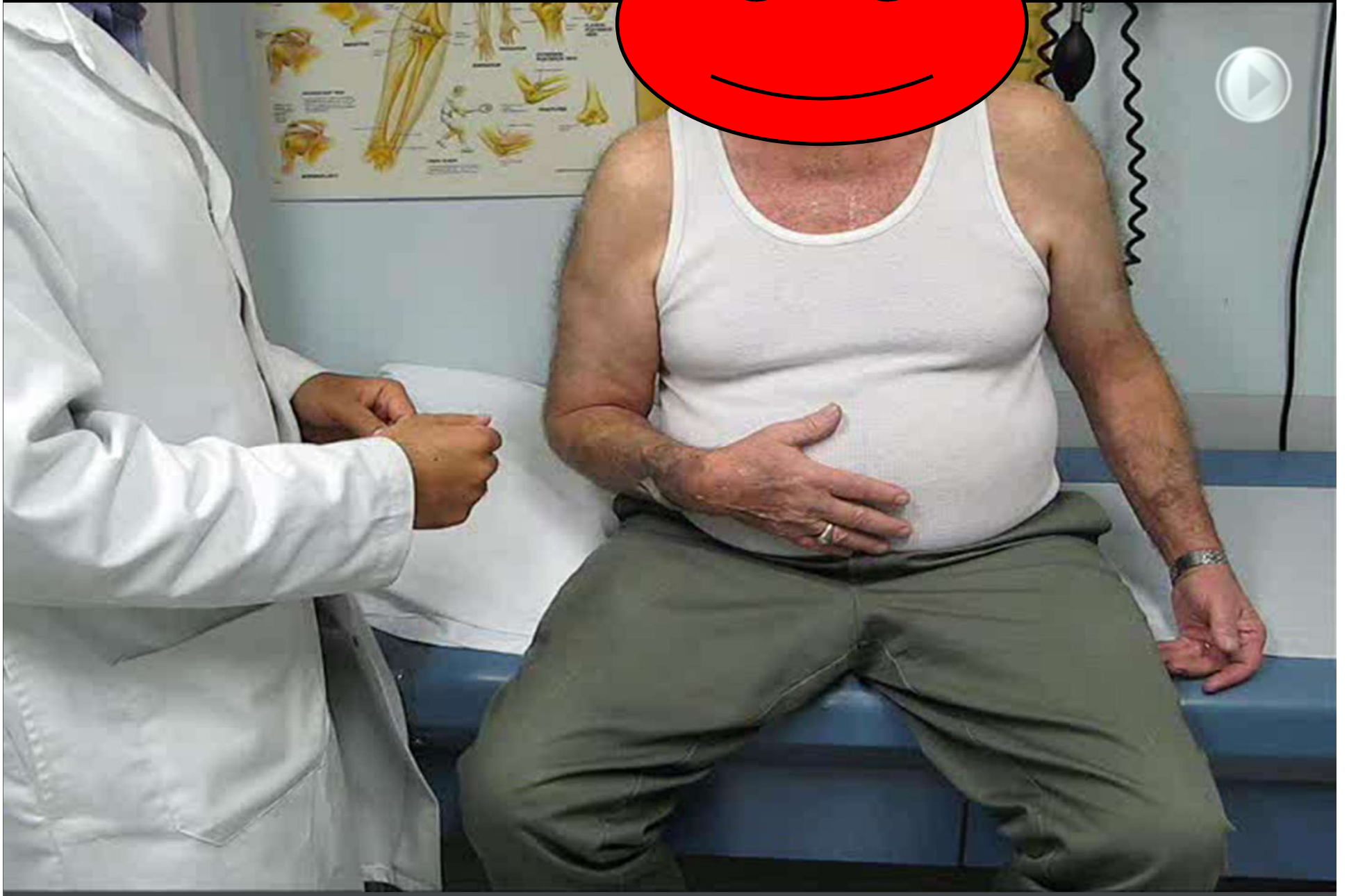

PHYSICAL EXAM

- Atrophy
- aFE: 100°
- aER: 0°
- (+) ER Lag
- ?

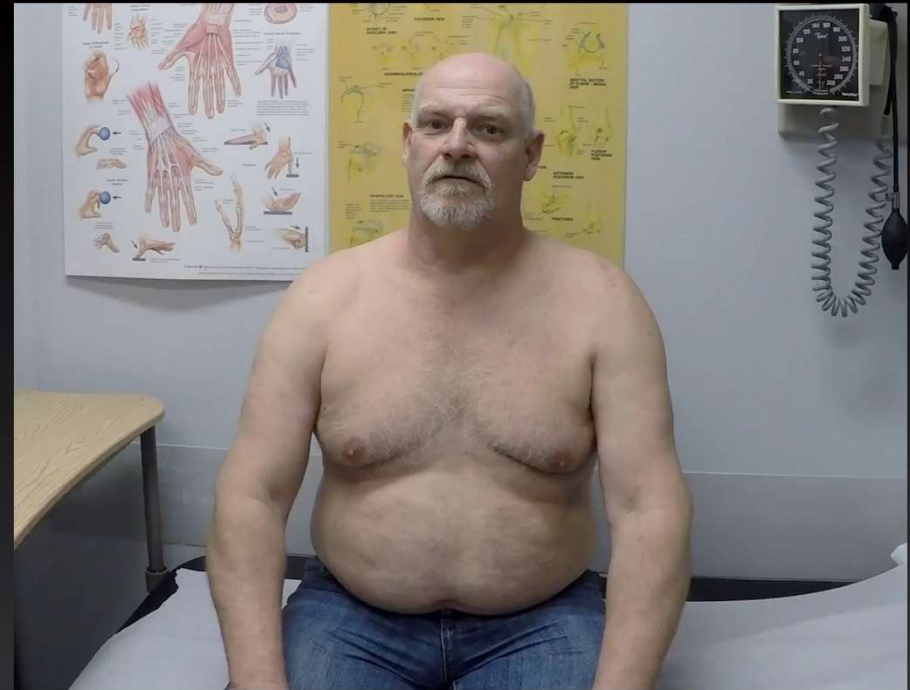

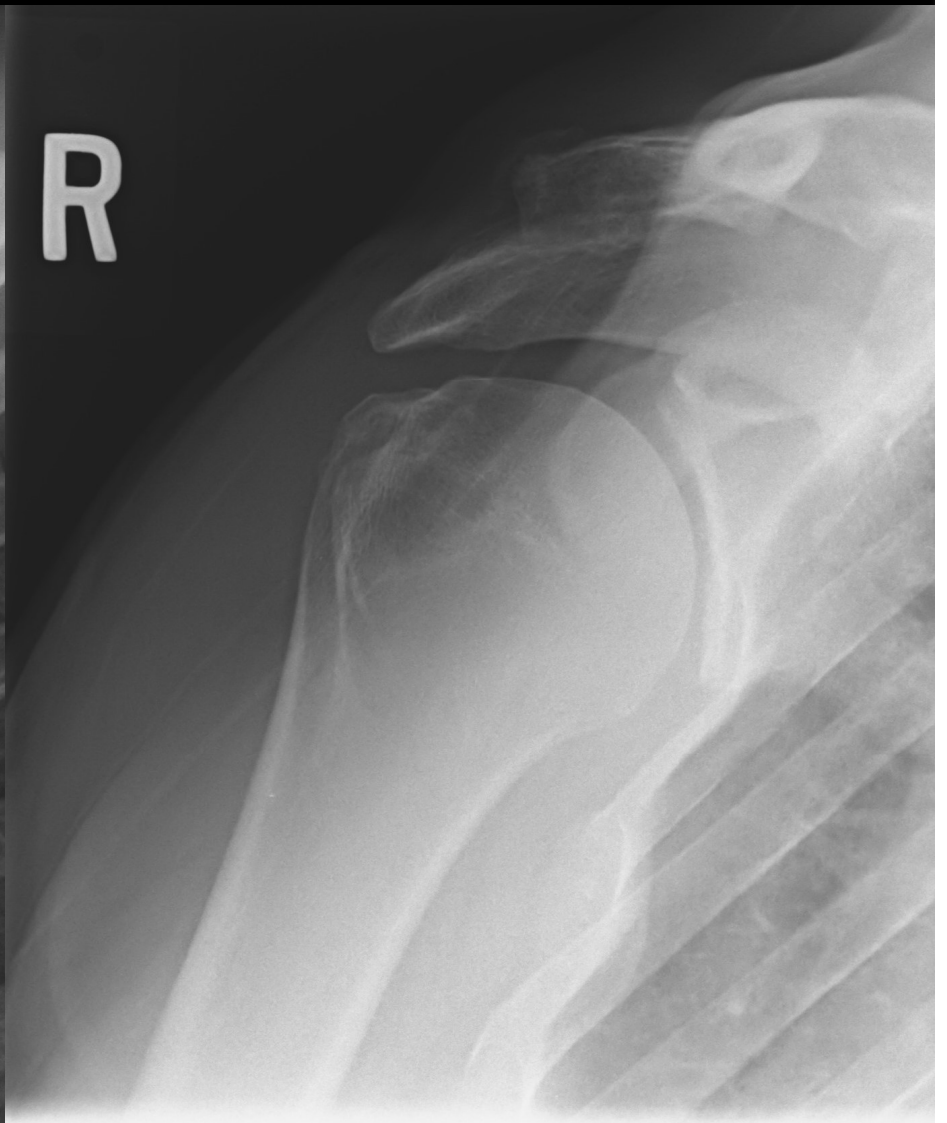
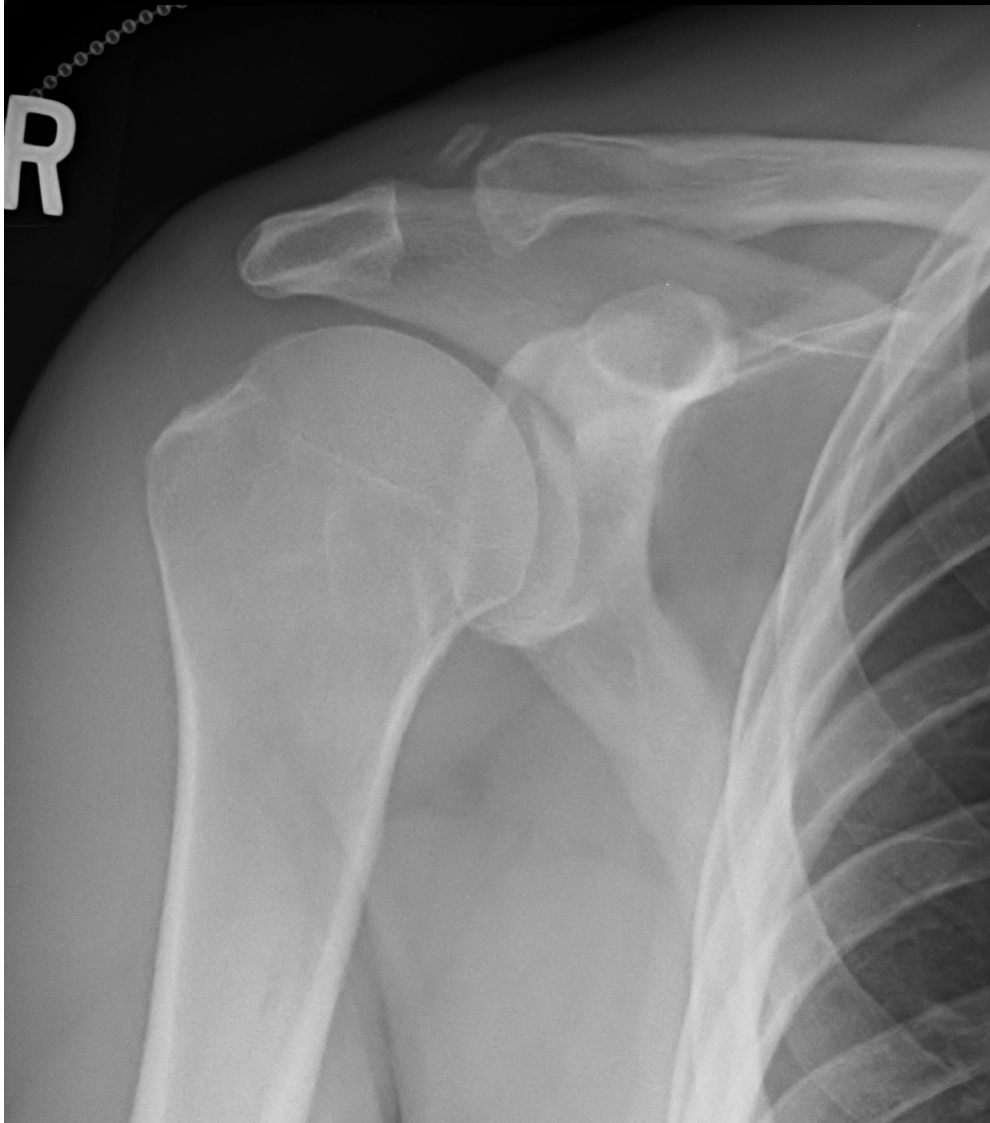



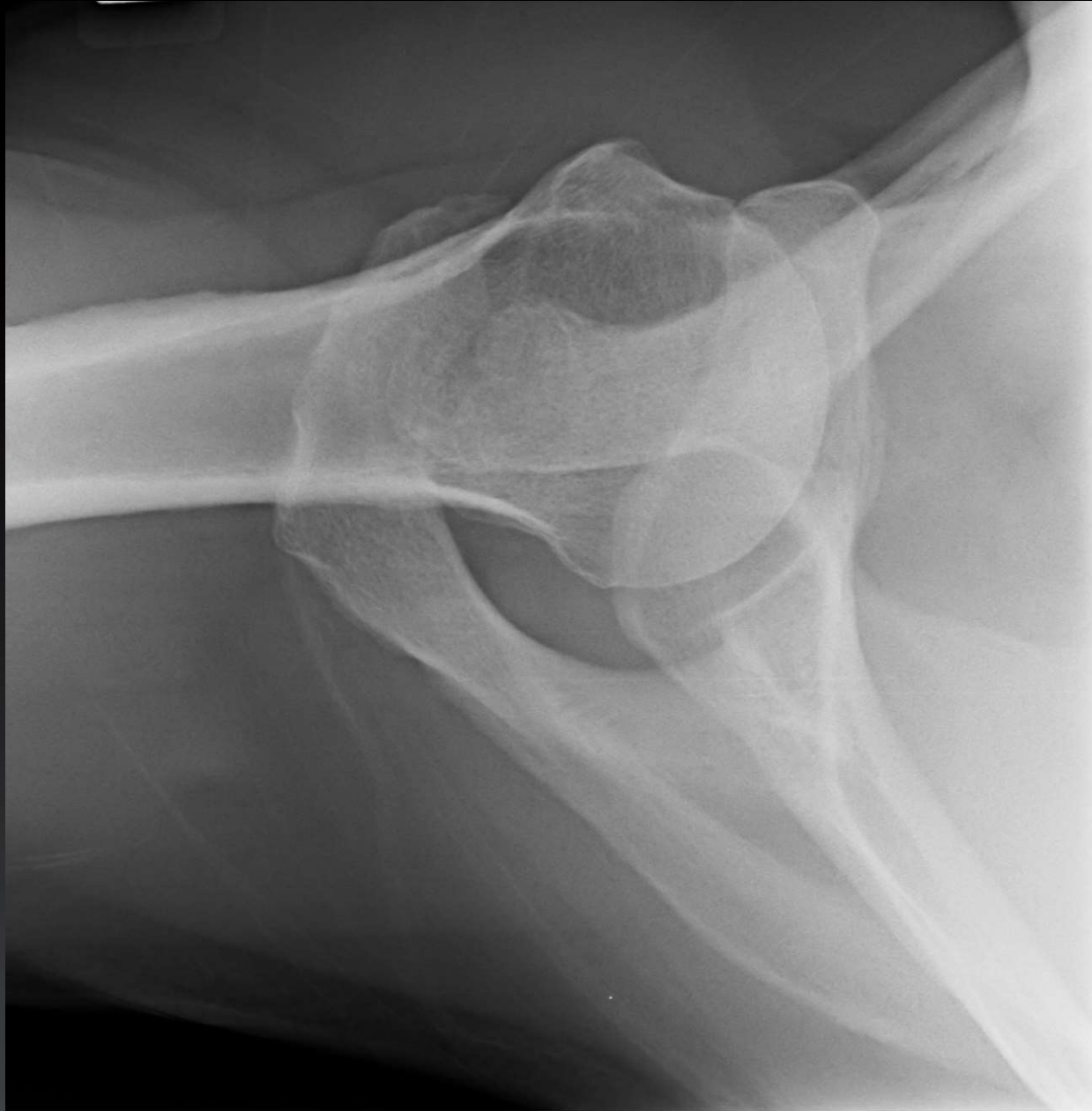
PHYSICAL EXAM

- Atrophy
- aFE: 100°
- aER: 0°
- (+) ER Lag
- (-) Lift Off
- (-) Belly Press







Schulich
MEDICINE & DENTISTRY



C Shoulder

IRMAN, JOHN (M/54y)
6229
IC: 001894502
IB: 1962-11-19
1 EXT UNILATERAL SERIES
3R PD FS + COR T2 FS
4
15/44

HAL

336229
ACC: 001894502
DOB: 1962-11-19
MR EXT UNILATERAL SERIES
COR PD FS + COR T2 FS
Sb.4
Im.13/44

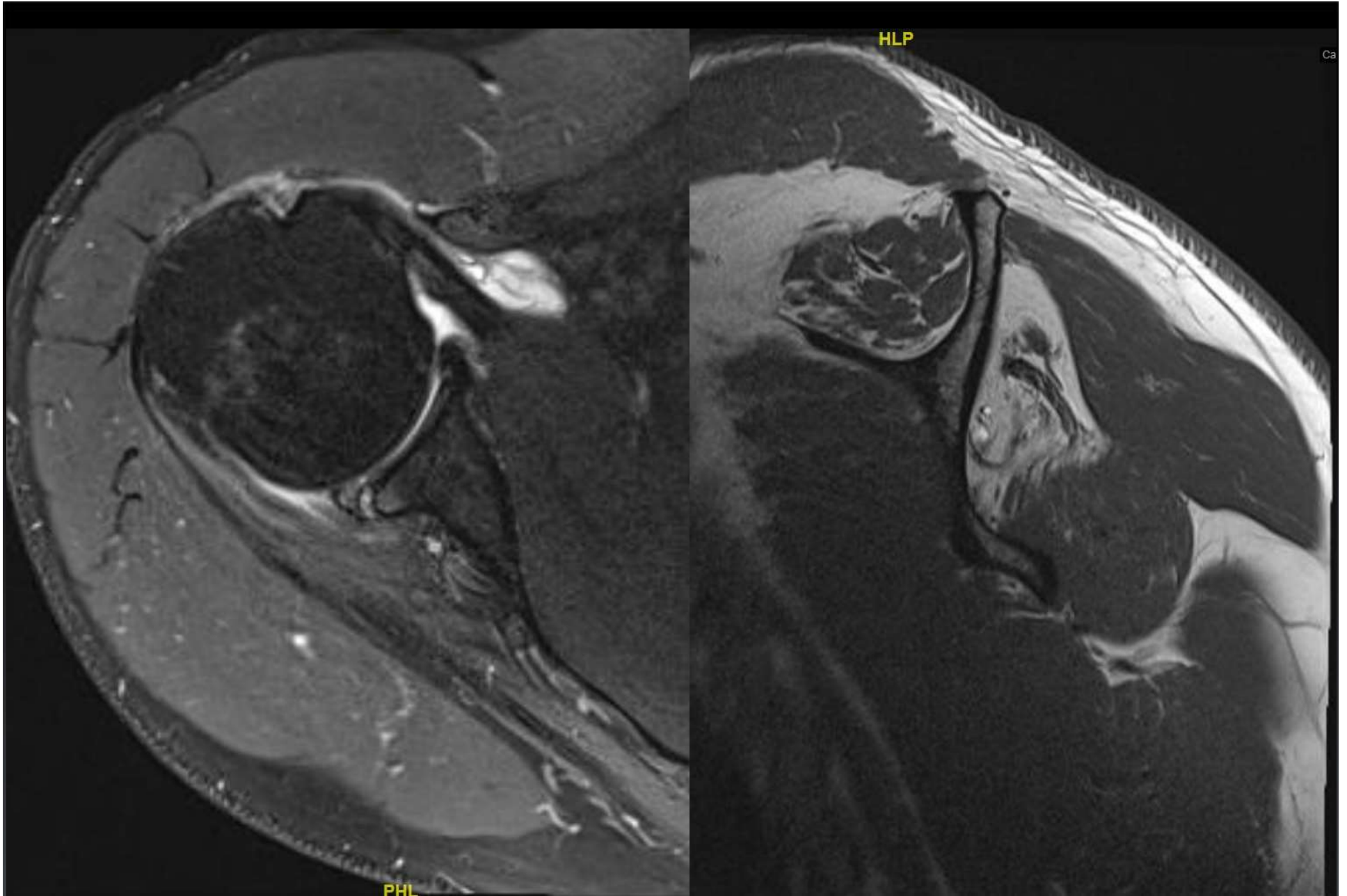
Cambridge Memor
02

A

RA


ssy.14.1

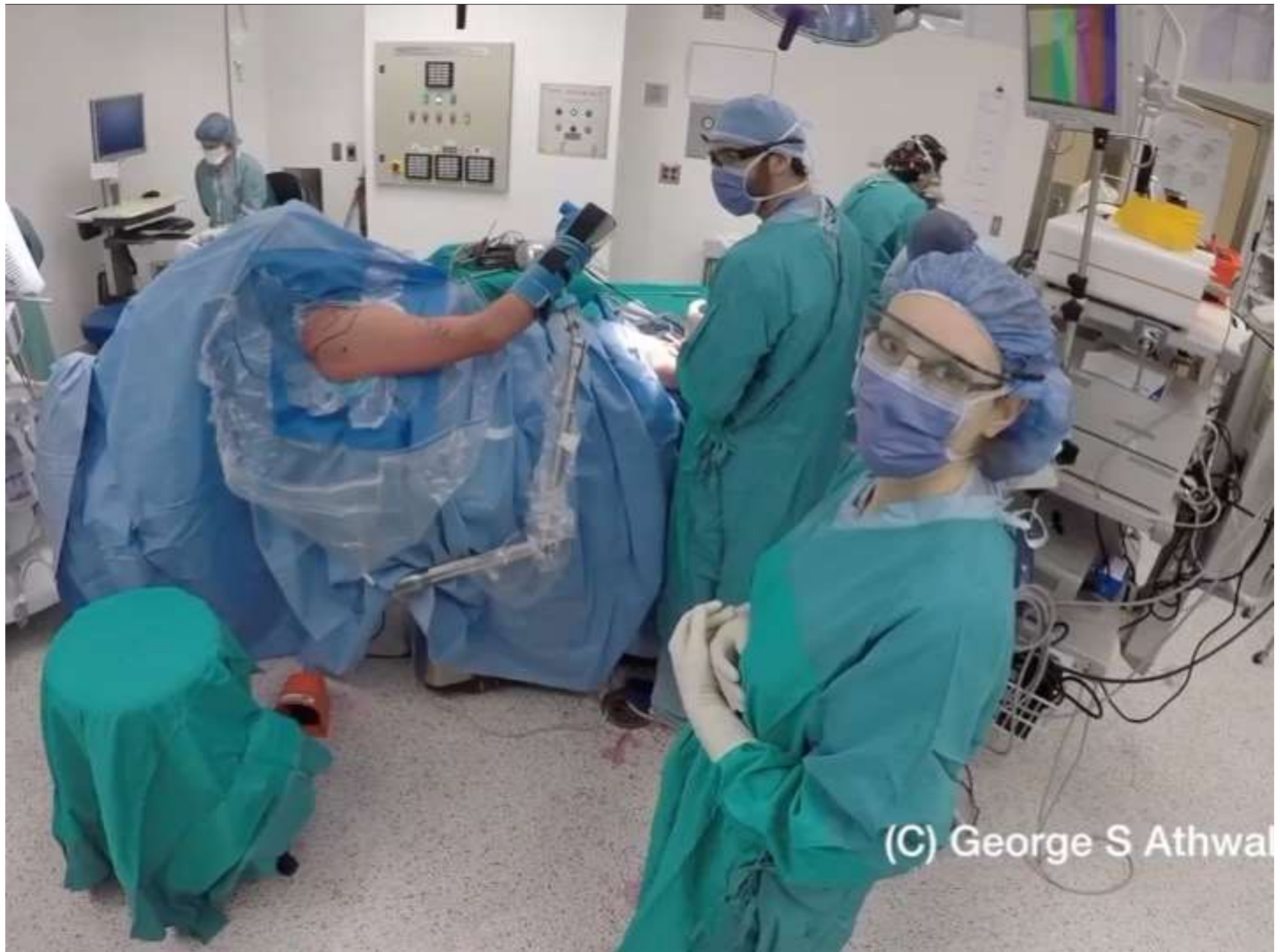FPR



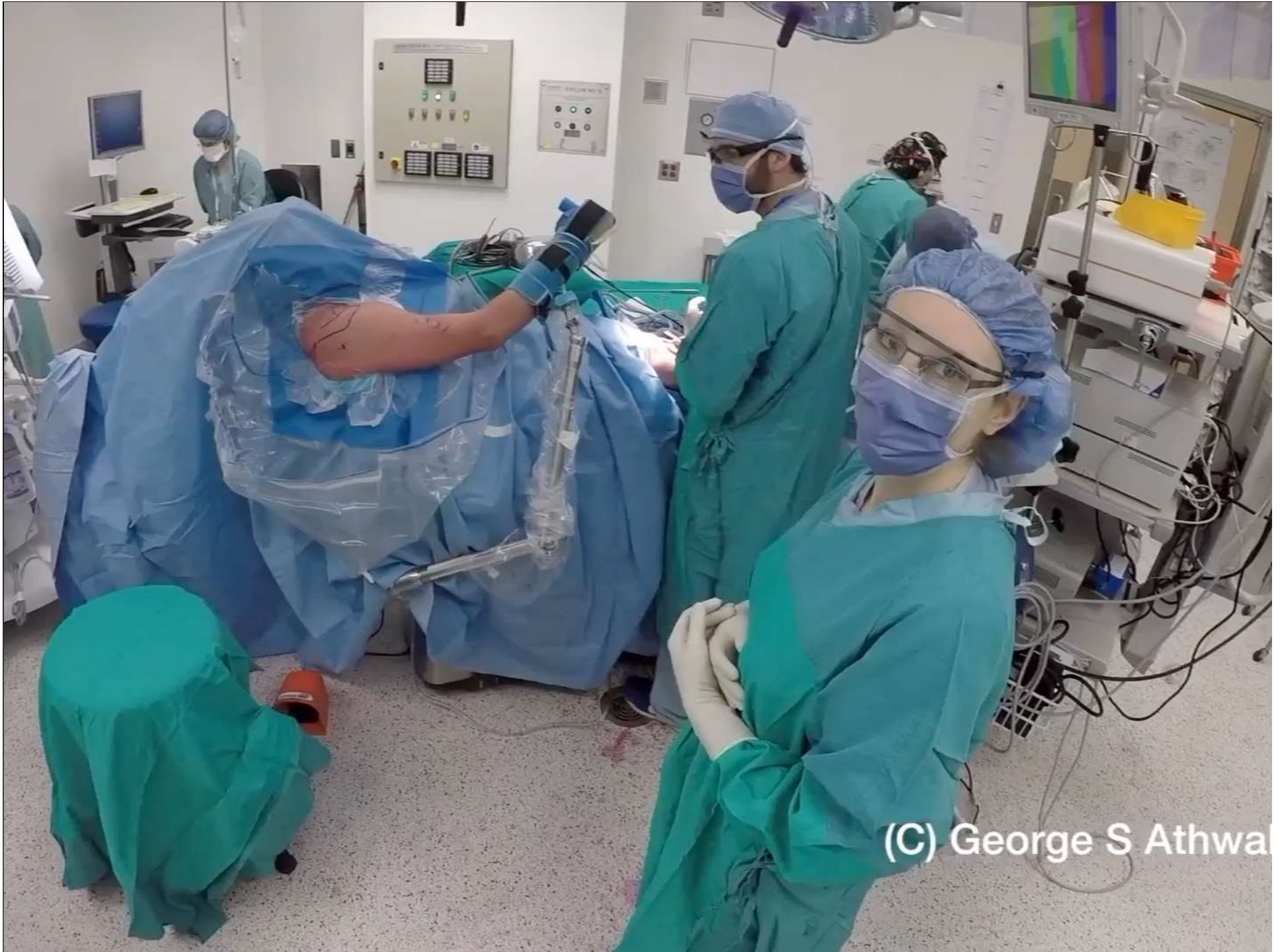
OPTIONS

Debridement
Biceps Tenotomy/Tenodesis
Partial Rotator Cuff Repair
Interposition Graft
Superior Capsular
Reconstruction
Subacromial Balloon
Latissimus Dorsi Tendon
Transfer
Lower Trapezius Transfer
Reverse Shoulder Arthroplasty





(C) George S Athwal



(C) George S Athwal

1 Year Post-Op

