

Smashed Distal Humerus Fracture: Repair versus Replace

Robert Z. Tashjian, MD

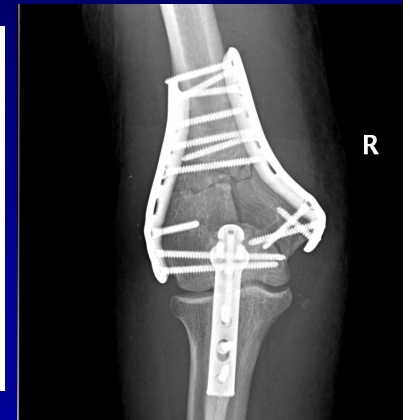Professor, Department of Orthopaedics, University of Utah
Ezekiel R. Dumke, Jr. Presidential Endowed Professor

26th Tampa Shoulder Course, Tampa, FL

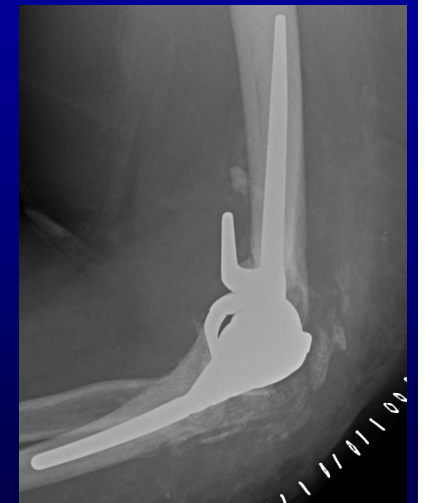

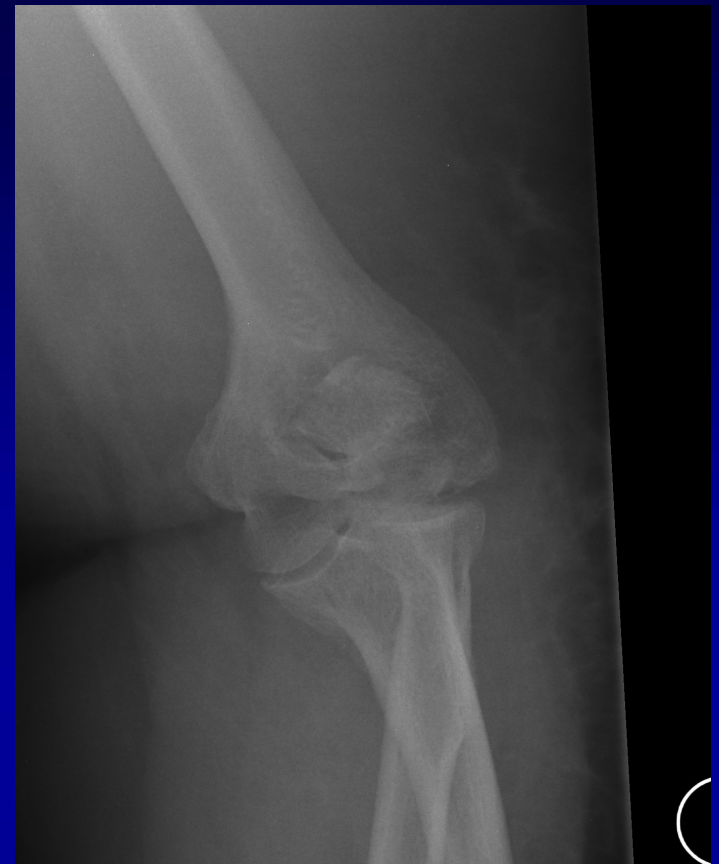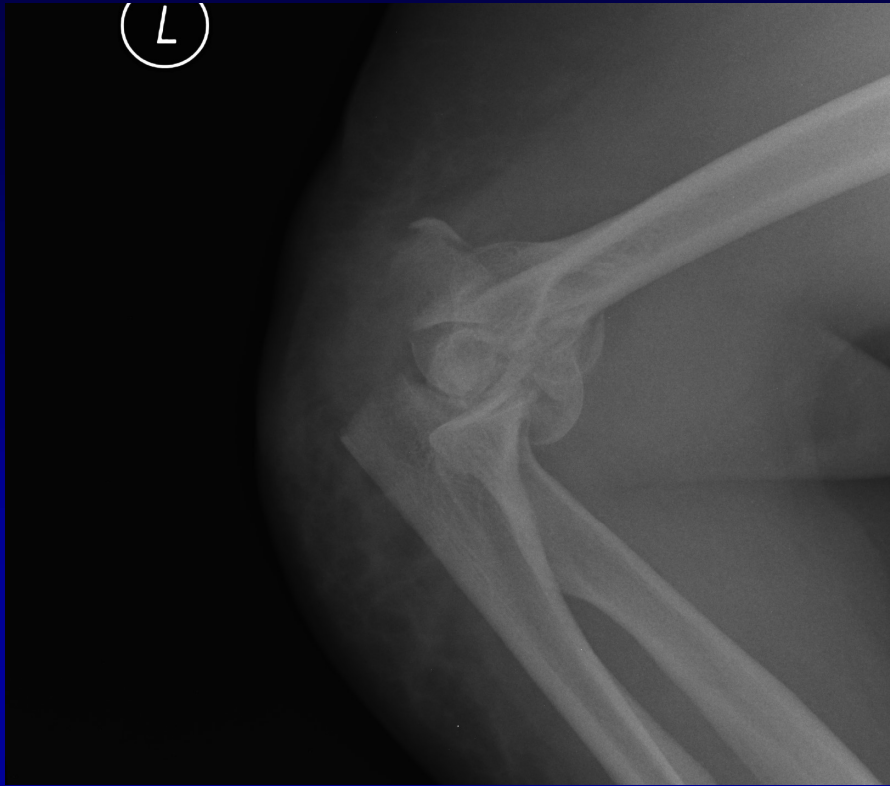
Fix or Replace?

- Comminuted intraarticular distal humerus fx
 - Repair – Mighell
 - Replace - Harter
- Factors influencing decision of tx
 - Age
 - Activity
 - Comorbidities
 - Prior surgery
 - Bone quality
 - Fracture pattern
 - Shear pattern or C3?



VS.





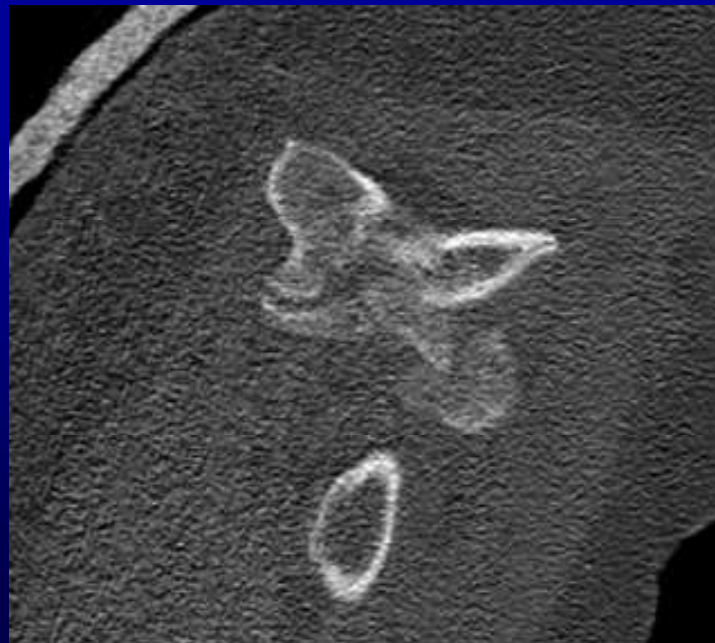
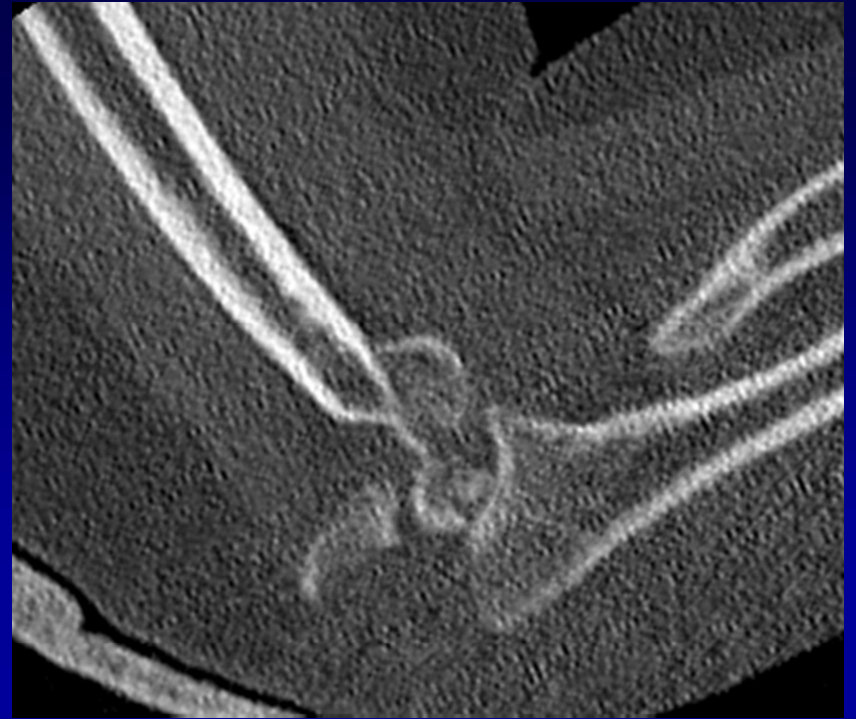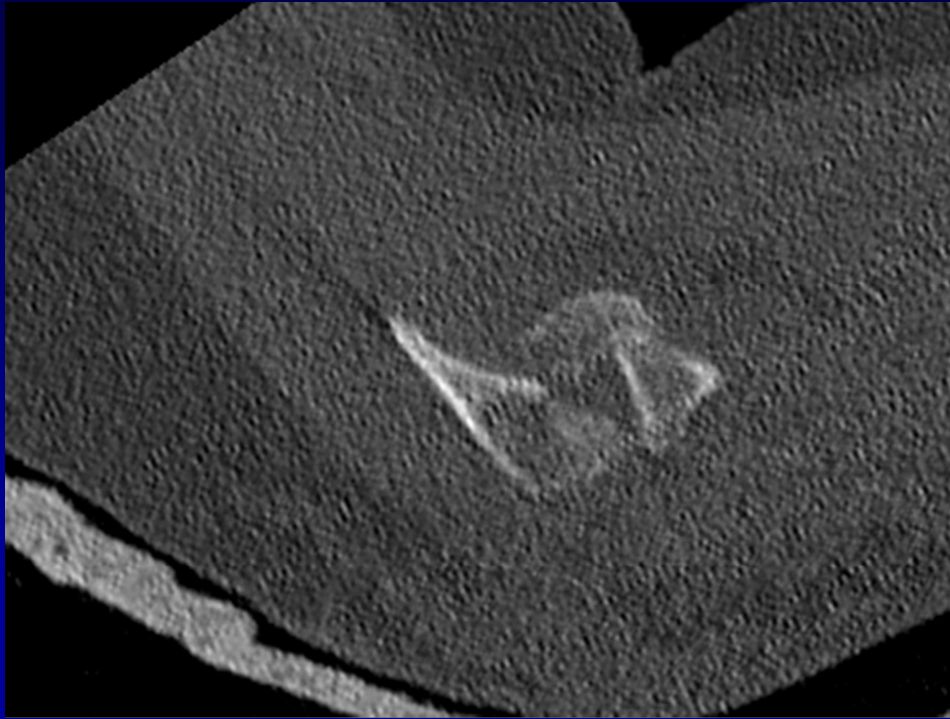
68 RHD year old female

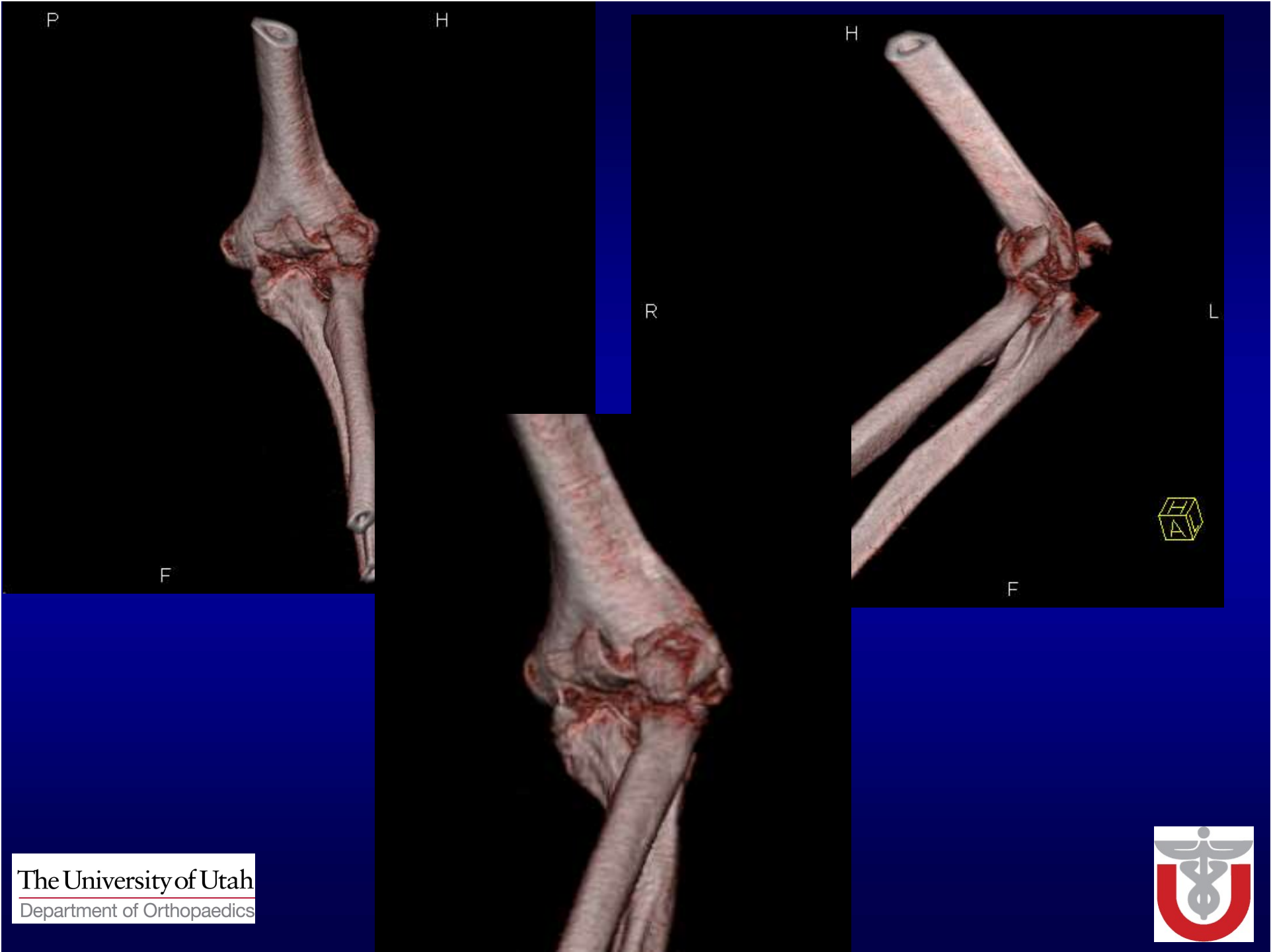Fell at home – isolated L distal humerus and L olecranon fracture

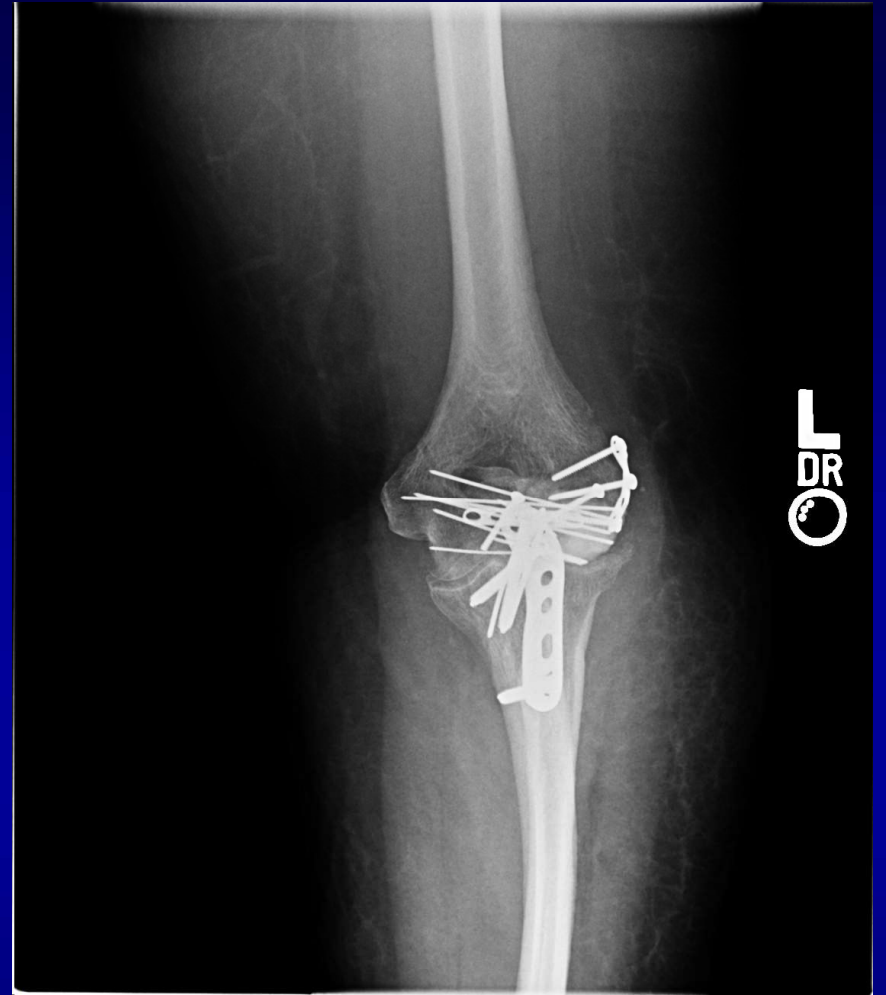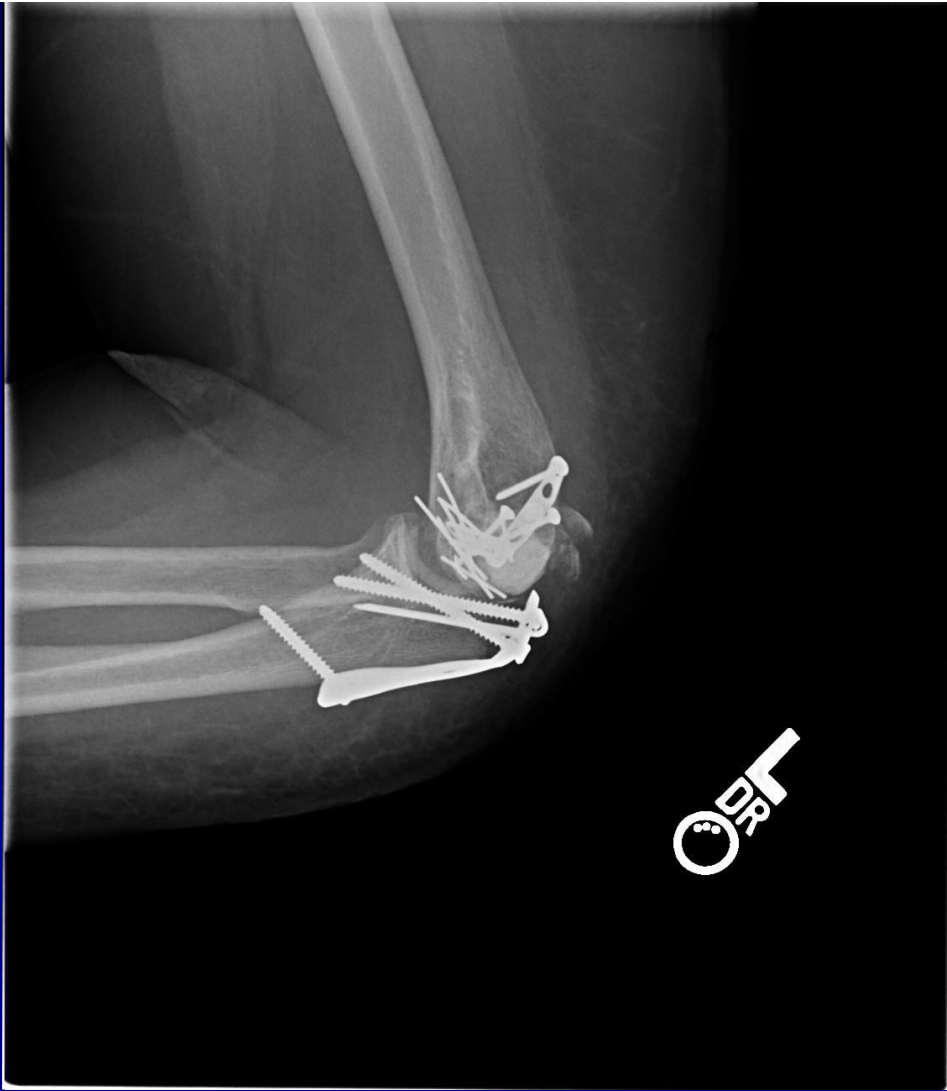Low demand

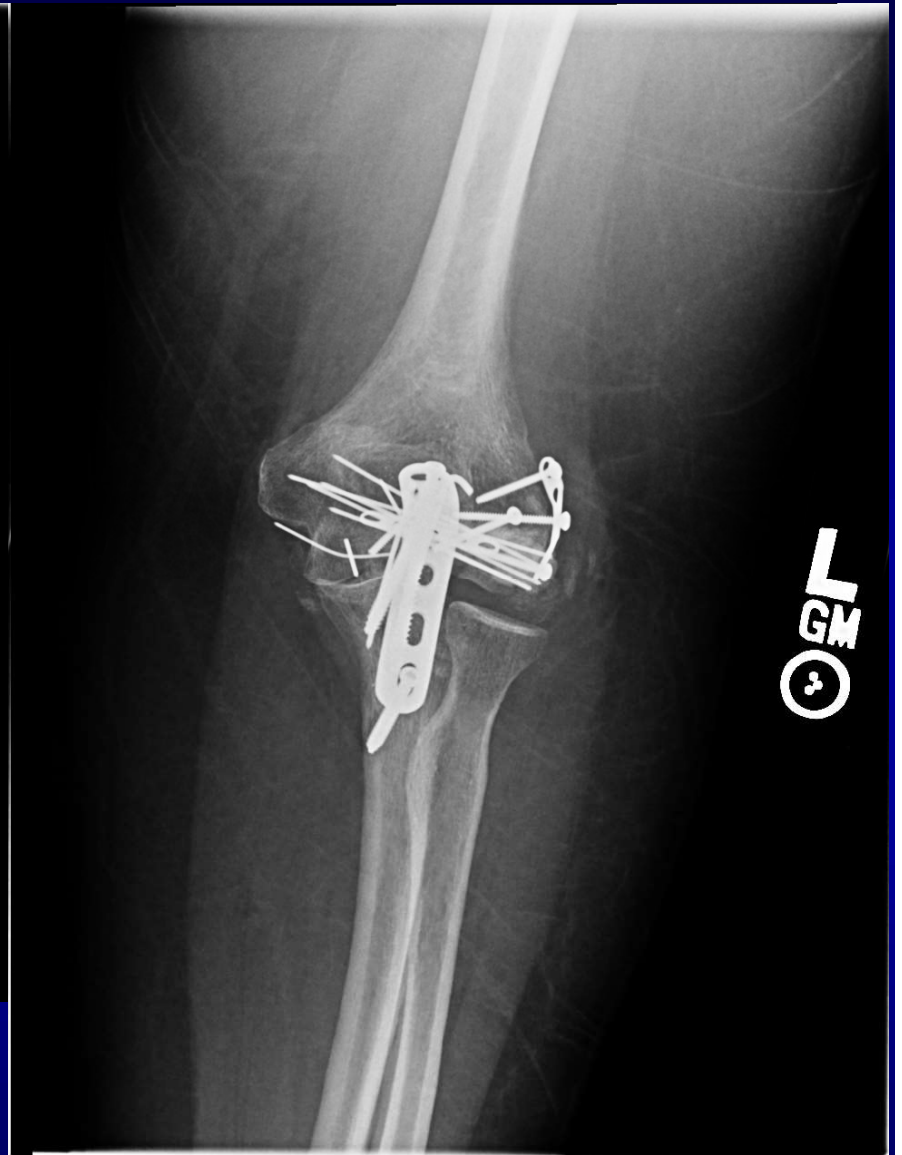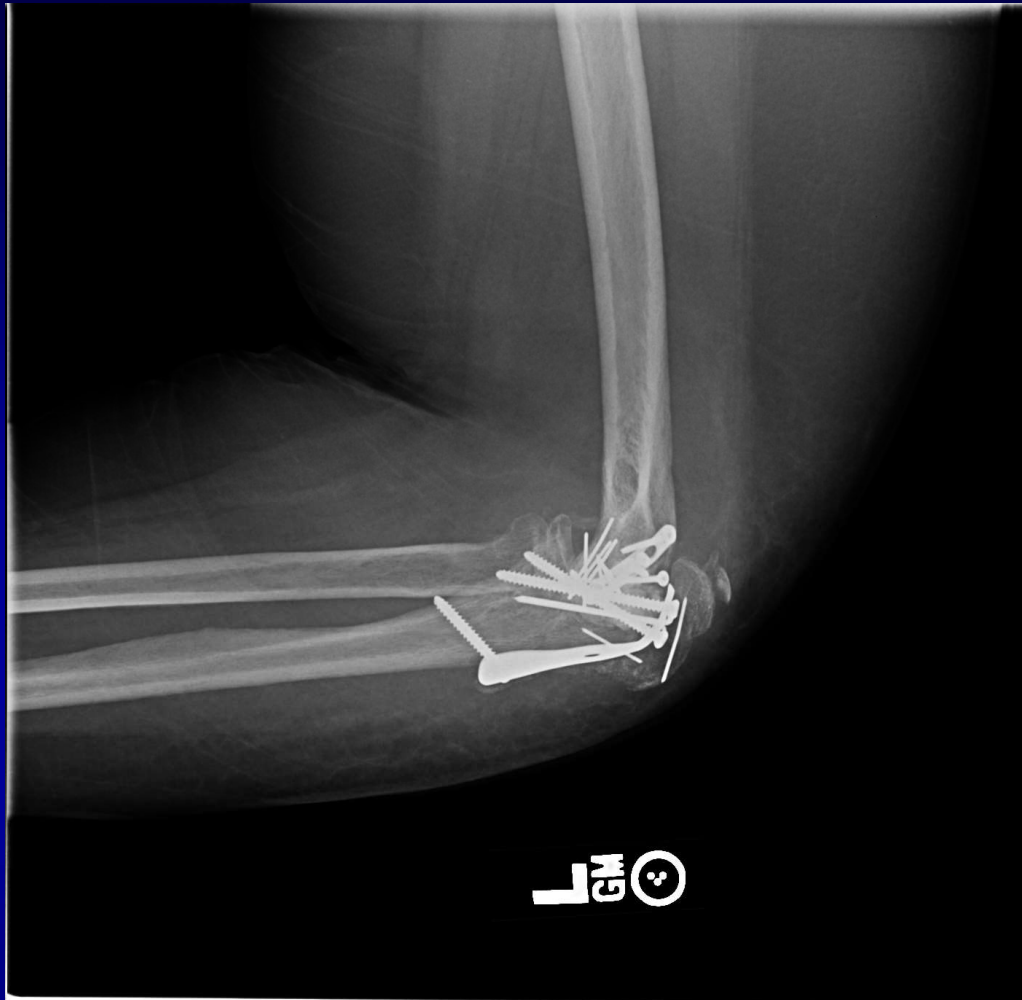PMHx – Diabetes, hypertension

BMI 39



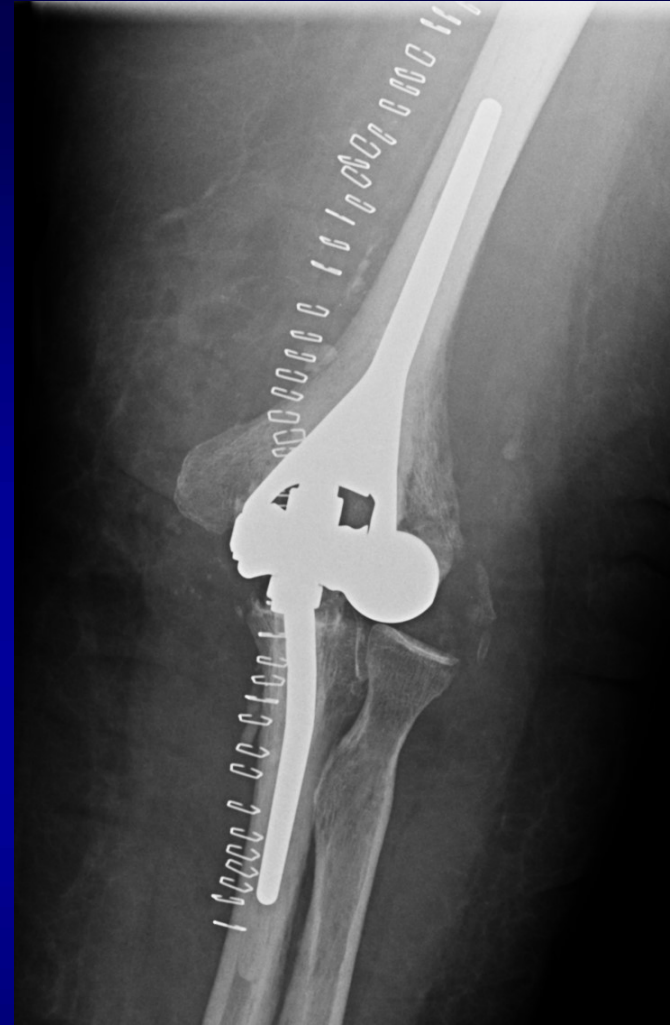
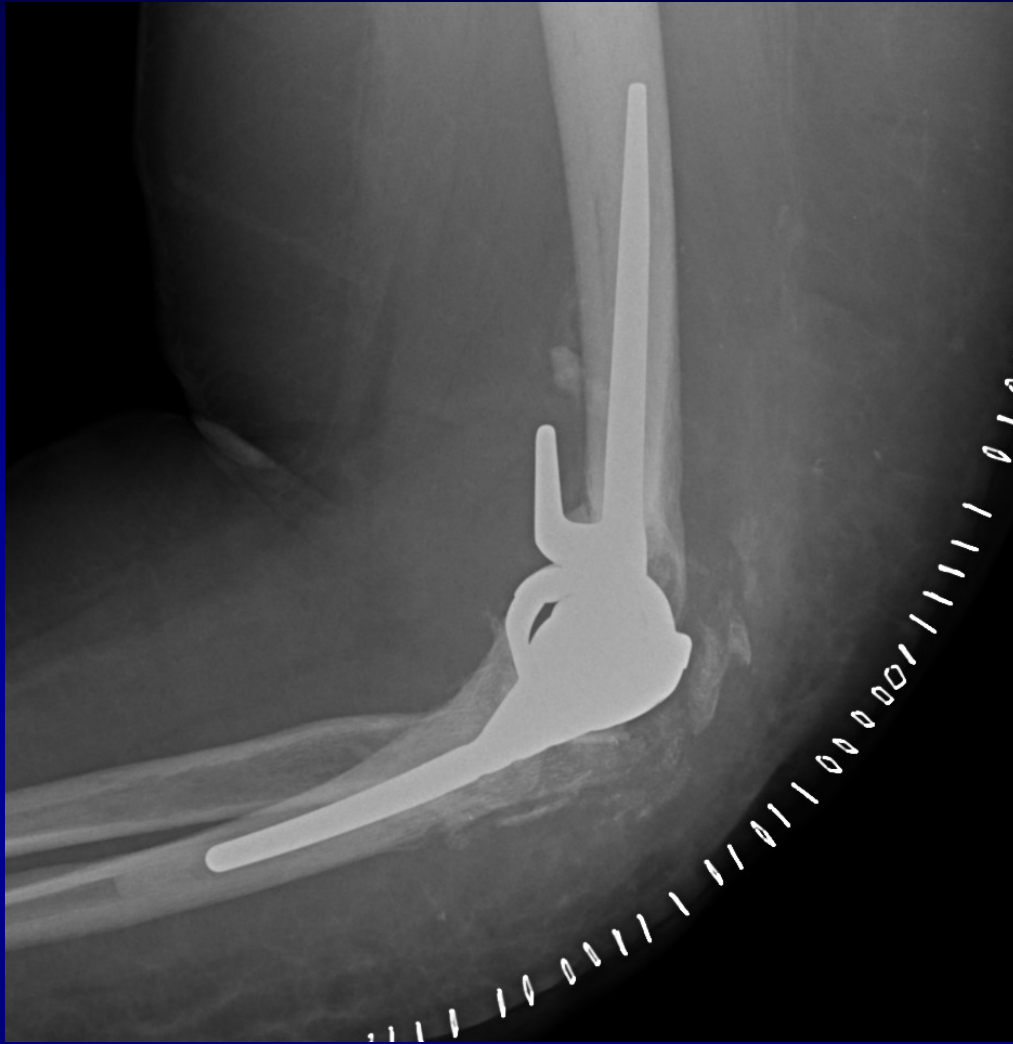





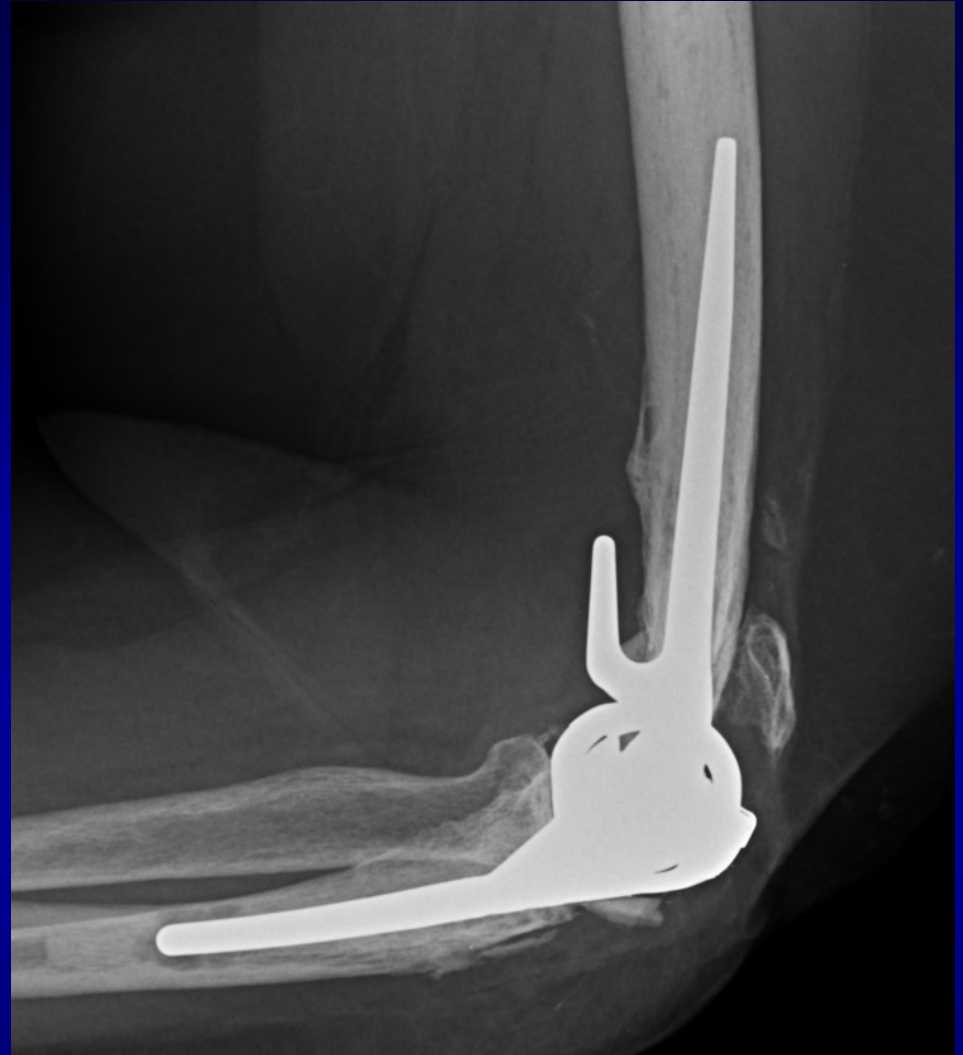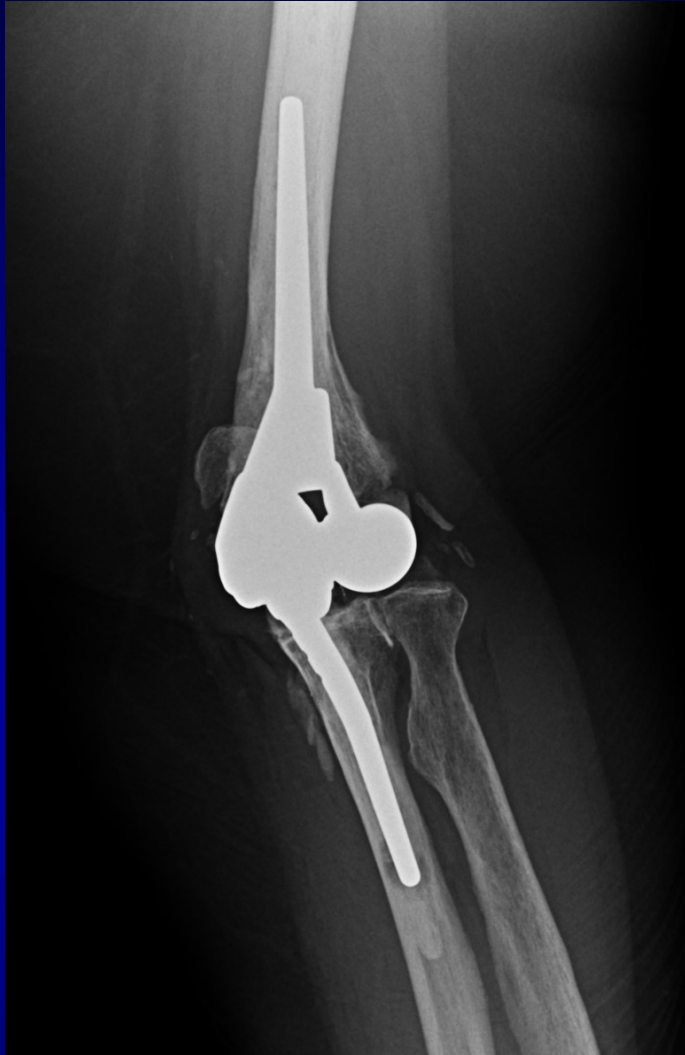3 months postoperative





Linked TEA
Repaired LCL and MCL
Maintained radial head
Repaired olecranon fragment w/suture tension band





9 years postop

Lacks 20 degrees of extension and some weakness

No pain

Returned to clinic b/c of proximal humerus fx on opposite side



THANK YOU

The University of Utah
Department of Orthopaedics

