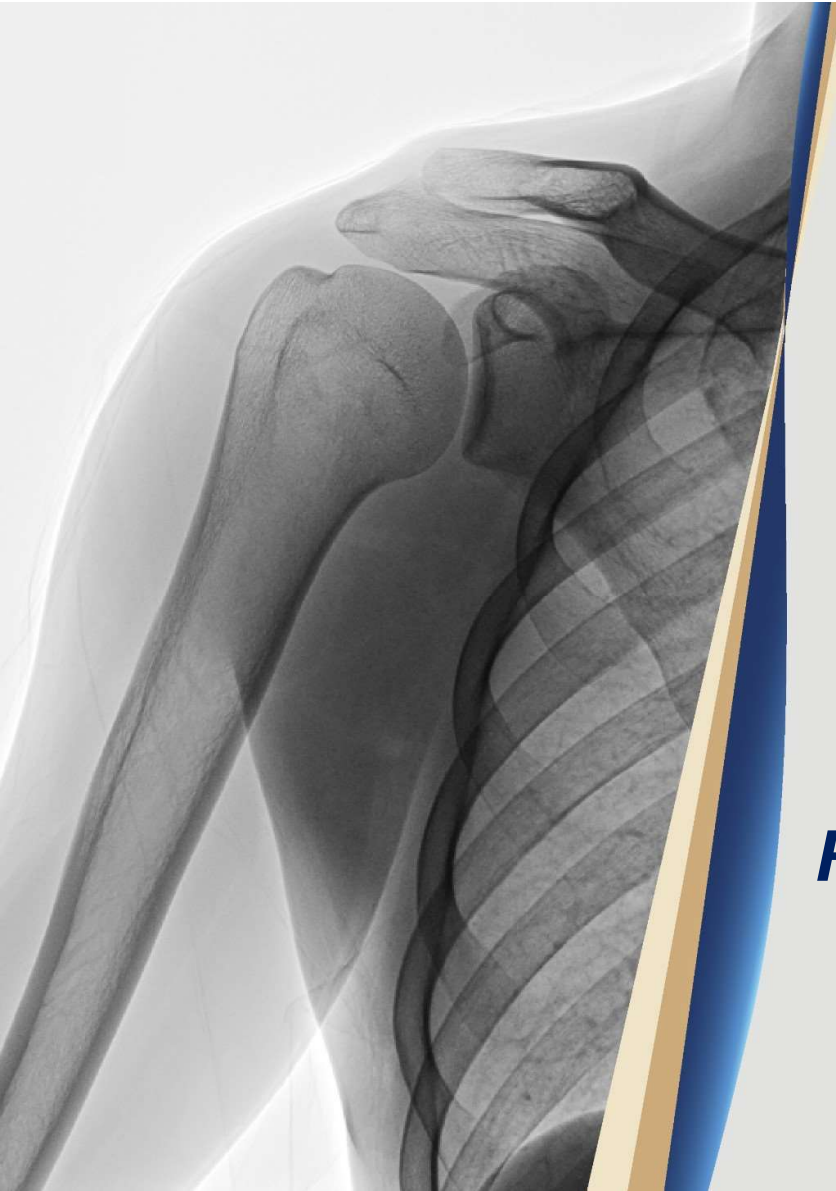



ROTHMAN
ORTHOPAEDIC INSTITUTE



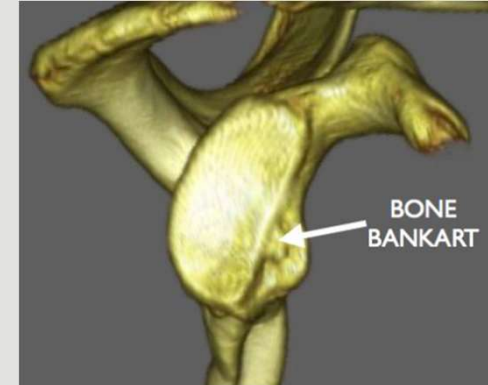
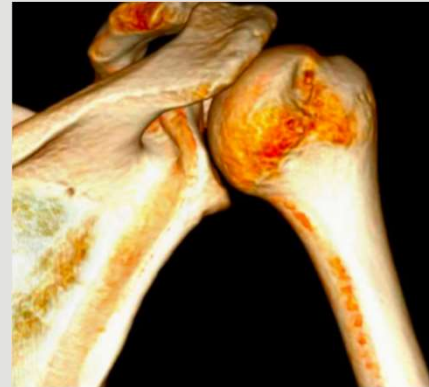**Sidney Kimmel
Medical College**
at Thomas Jefferson University

Debate #2
**Hill-Sachs Lesion in a
Recurrent Instability Patient**
Remplissage vs. Restoration of Bone

Humeral Bone Loss

“Hill-Sachs Lesion”

- **Hill-Sachs Lesion**
 - Size and location
- **Glenoid Bone Loss**
 - Glenoid bone loss narrows articular arc
- **Engagement**
 - Size of Hill-Sachs/Bony Bankart
 - Degree of ABER
 - Glenoid Track (On/Off)



ROTHMAN
ORTHOPAEDIC INSTITUTE



**Sidney Kimmel
Medical College**
at Thomas Jefferson University

Argument for: Bankart Repair with Remplissage

Jeffrey S. Abrams, MD



ROTHMAN
ORTHOPAEDIC INSTITUTE



**Sidney Kimmel
Medical College**
at Thomas Jefferson University

**Argument for:
Restore the Bone with
Allograft or Autograft**

Anthony Miniaci, MD



ROTHMAN
ORTHOPAEDIC INSTITUTE



**Sidney Kimmel
Medical College**
at Thomas Jefferson University

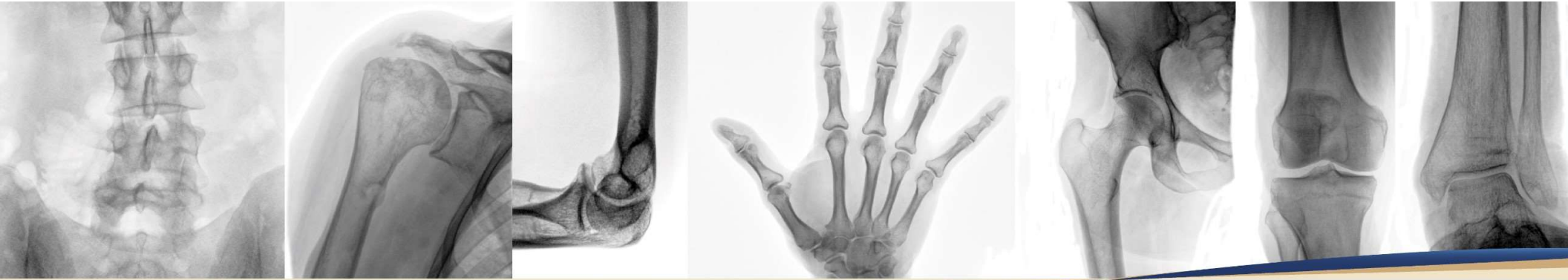Let's Rumble



ROTHMAN
ORTHOPAEDIC INSTITUTE



**Sidney Kimmel
Medical College**
at Thomas Jefferson University



THANK YOU.



ROTHMAN
ORTHOPAEDIC INSTITUTE



**Sidney Kimmel
Medical College**
at Thomas Jefferson University