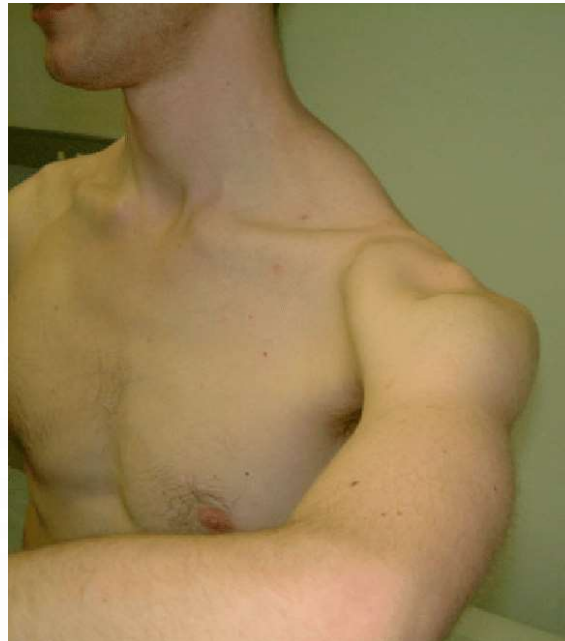

Case #4: The Patient with Recurrent Posterior Instability



Saturday, February 1, 2020, 9:15am-9:30am

John E. Kuhn, MD

Kenneth D. Schermerhorn Professor of Orthopaedics
Chief of Shoulder Surgery

Panelists

- Grant Garrigues, MD
- Joshua Dines, MD
- Robert Tashjian, MD
- Anthony Miniaci, MD



Fun Facts

- Posterior Instability=10% of surgically treated Instability Patients
- Increasing in Frequency
- Increased Retroversion is Statistically Associated with the Development of Symptoms and Failures of Surgery



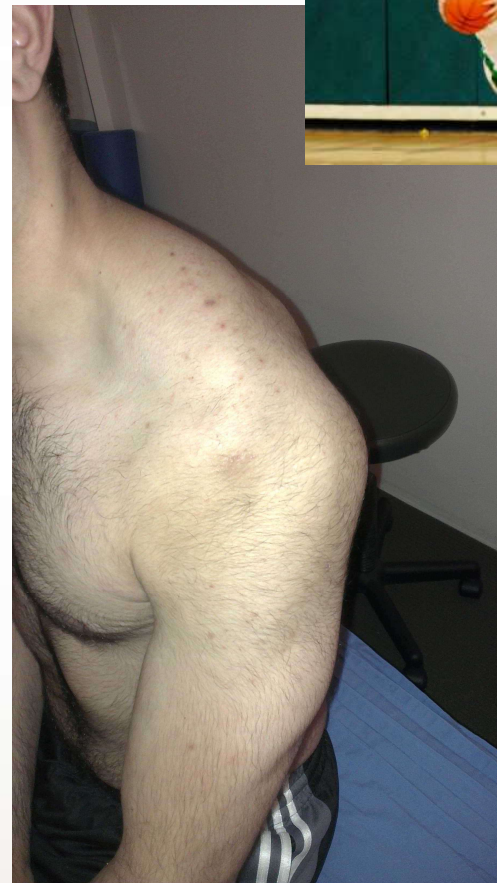Before the Case Define our Terms

- *Define Instability*
- *Define Subluxation vs Dislocation*
- *Define Multidirectional Instability*



Case 1-History

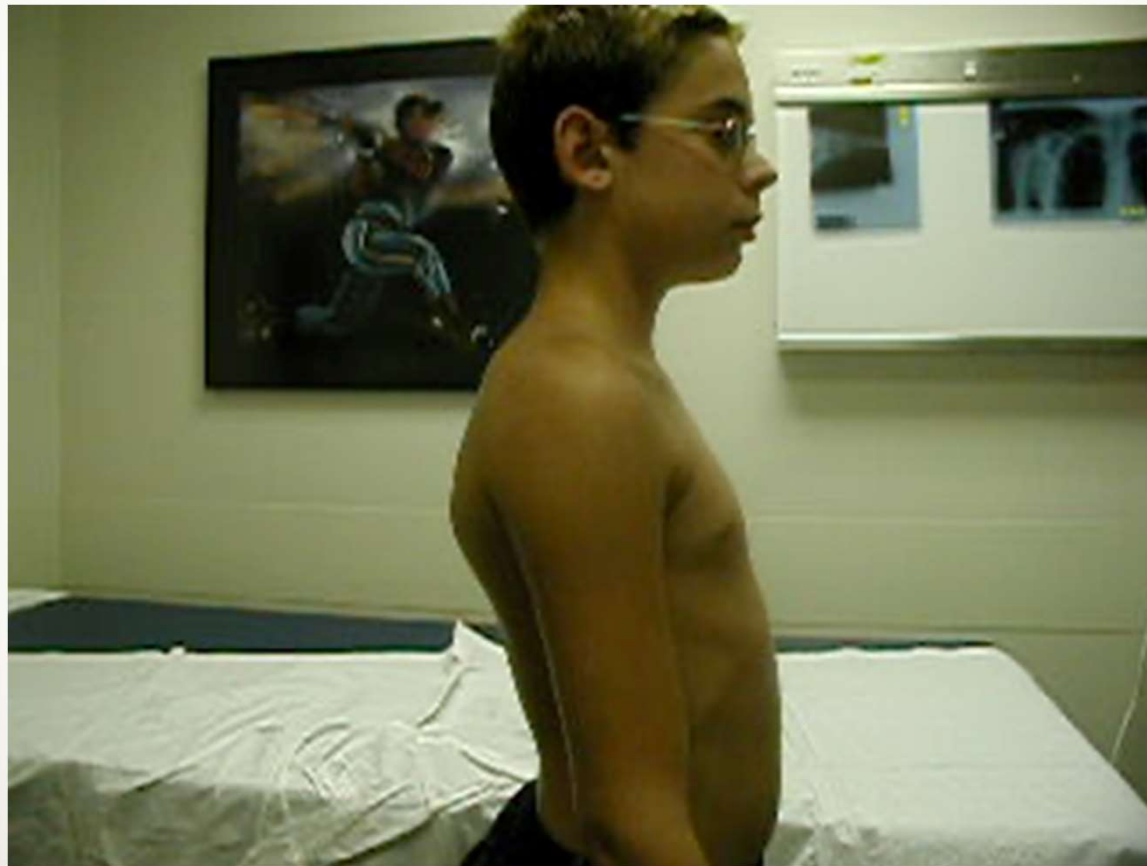- 23 Year old Male
- Recreational Basketball Player
- Pain with forward Elevation of the Arm
- Shoulder is Slipping Out and In
- He can Demonstrate what is Happening



History

With Regard to the History, What Other Features do you Find Important to Understand Posterior Instability?

Voluntary Instability



Physical Exam

- Pain with Forward Elevation and Internal Rotation
- Reproduction of Symptoms with Posterior Translation of the Humeral Head
- Positive Jerk Test
- Positive Kim Test

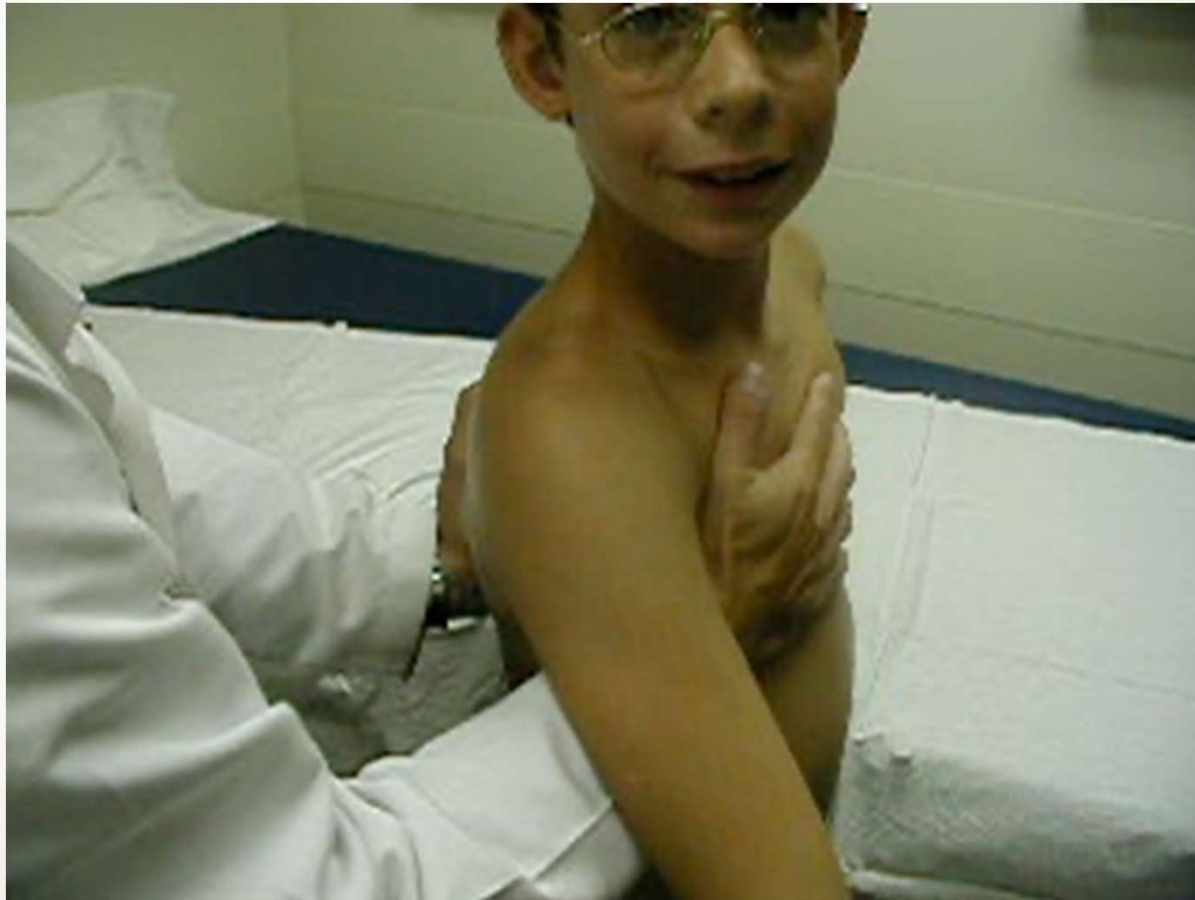Physical Exam

What Other Exam Features do you Find Important to Understand Posterior Instability?

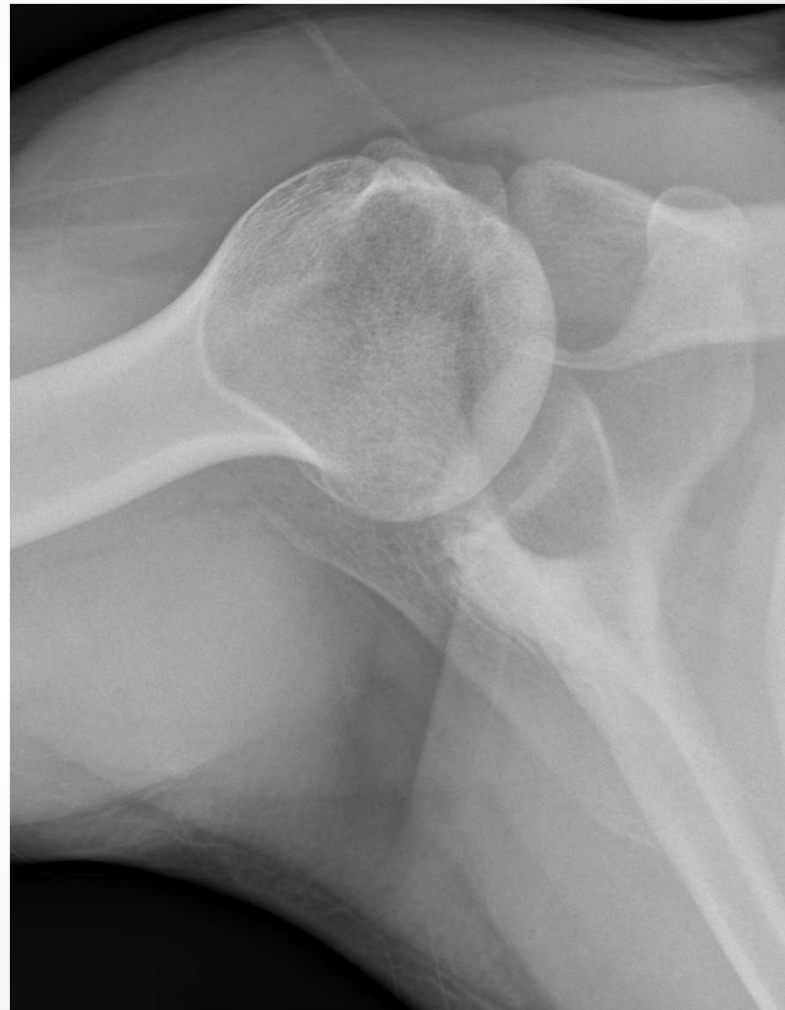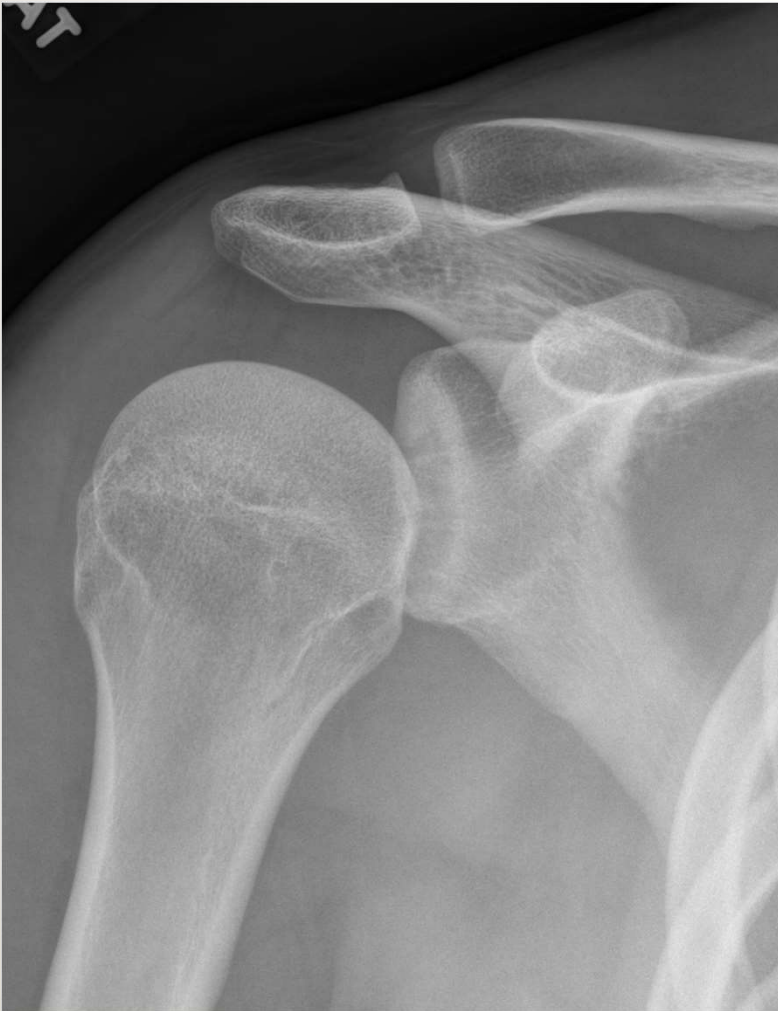How Helpful is Grading Translation?

Scapula?

Role of the Scapula

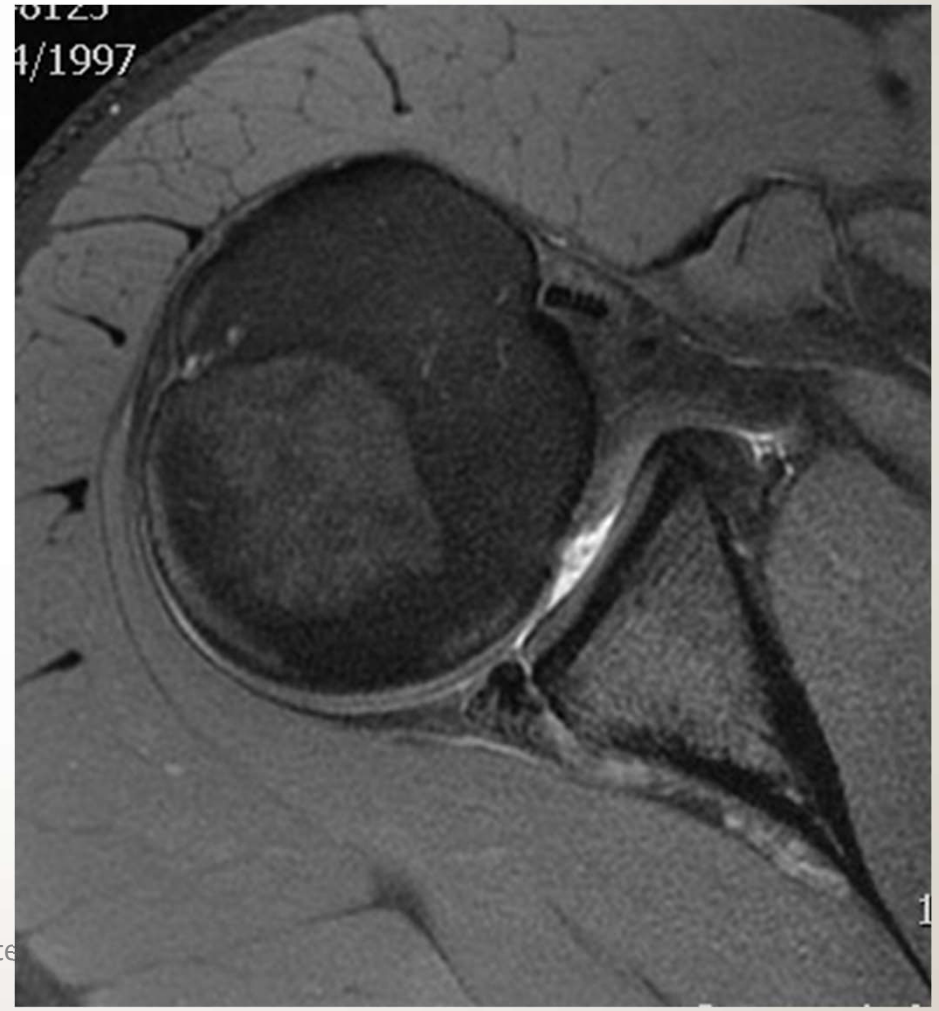
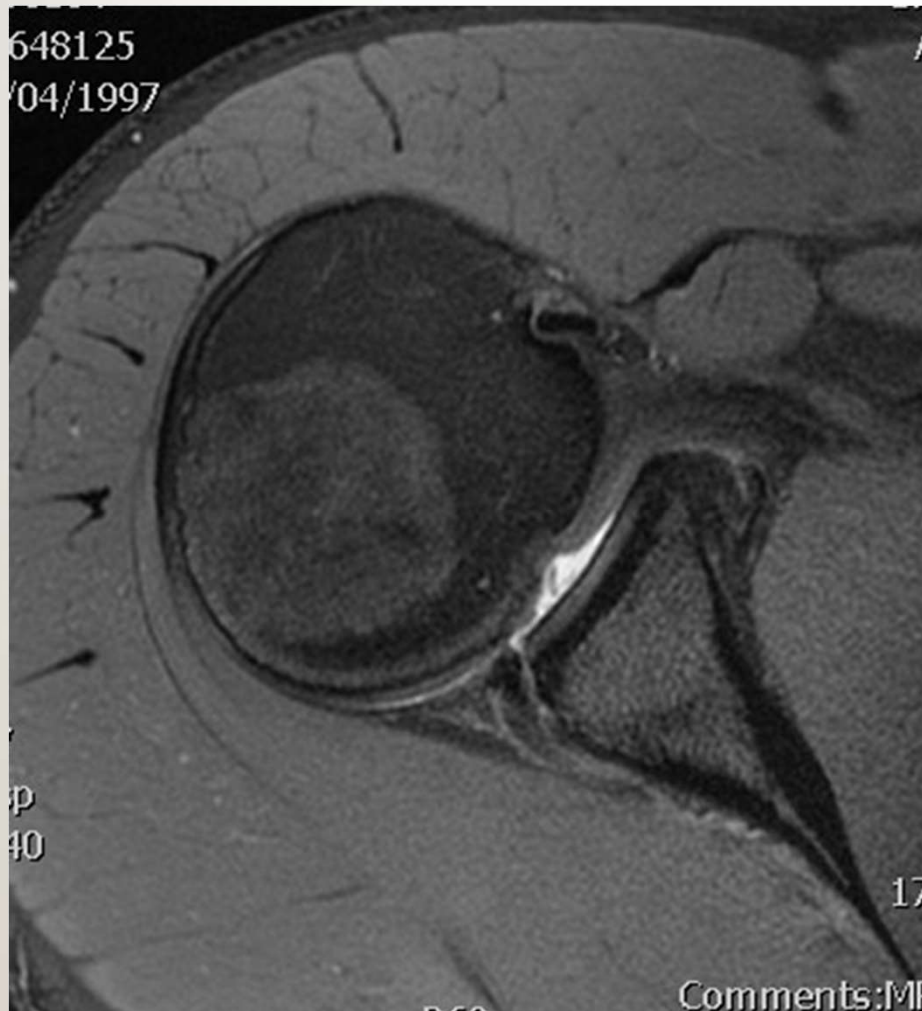

Radiographs



What do you look for on Plain Radiographs? Vanderbilt Sports Medicine

MRI Scan



Approach?

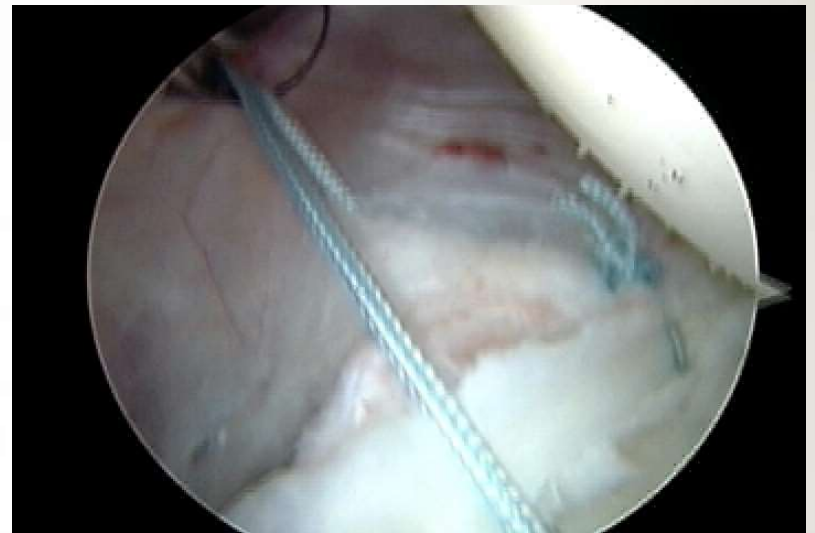
Will Rehabilitation Work?

Indications for Arthroscopic Repair?

Who would get an Open Repair?

Arthroscopic Posterior Bankart Repair

- 3 Anchors
- Repaired Labrum
- Reefed Capsule into Labrum
- Did Superior Shift of Capsule

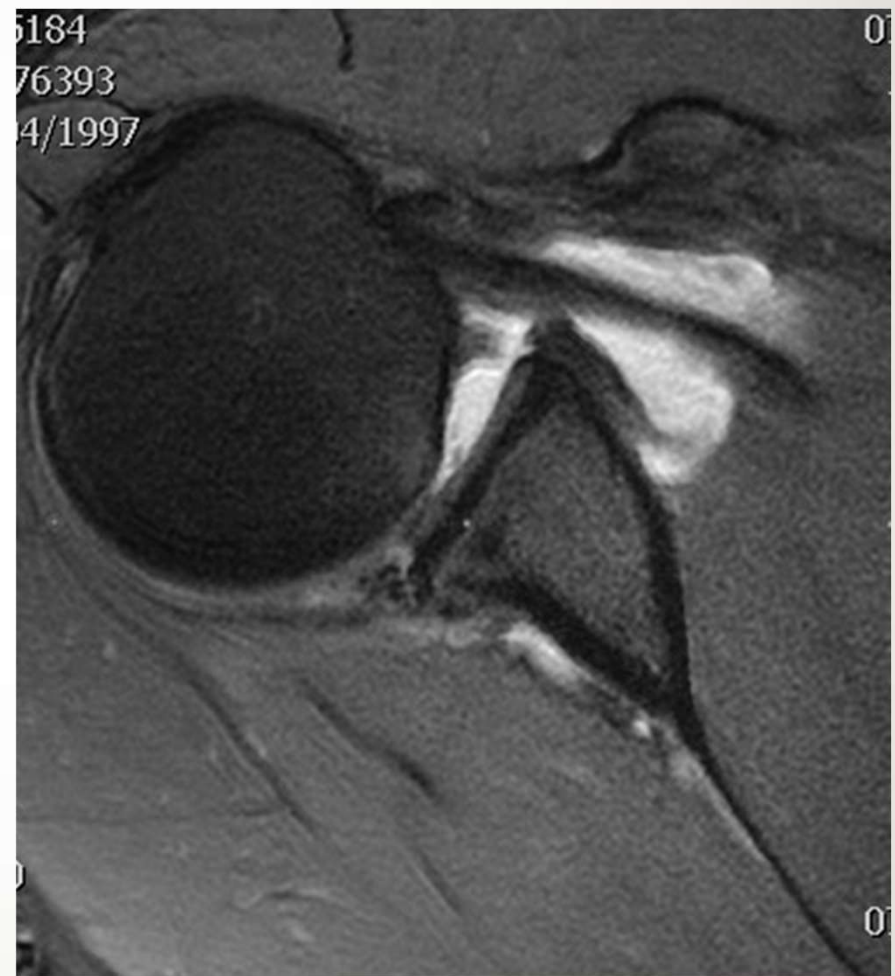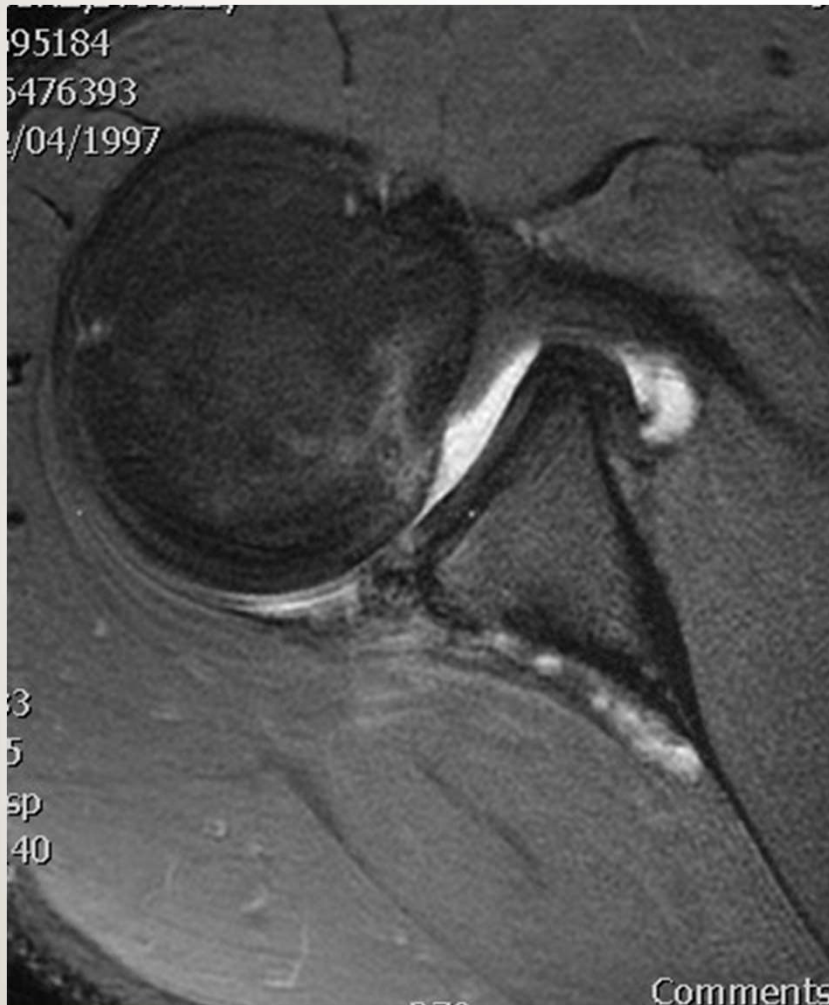


Follow Up

- Did well for 1.5 years
- Symptoms returned after a Bicycle Injury



New MRI



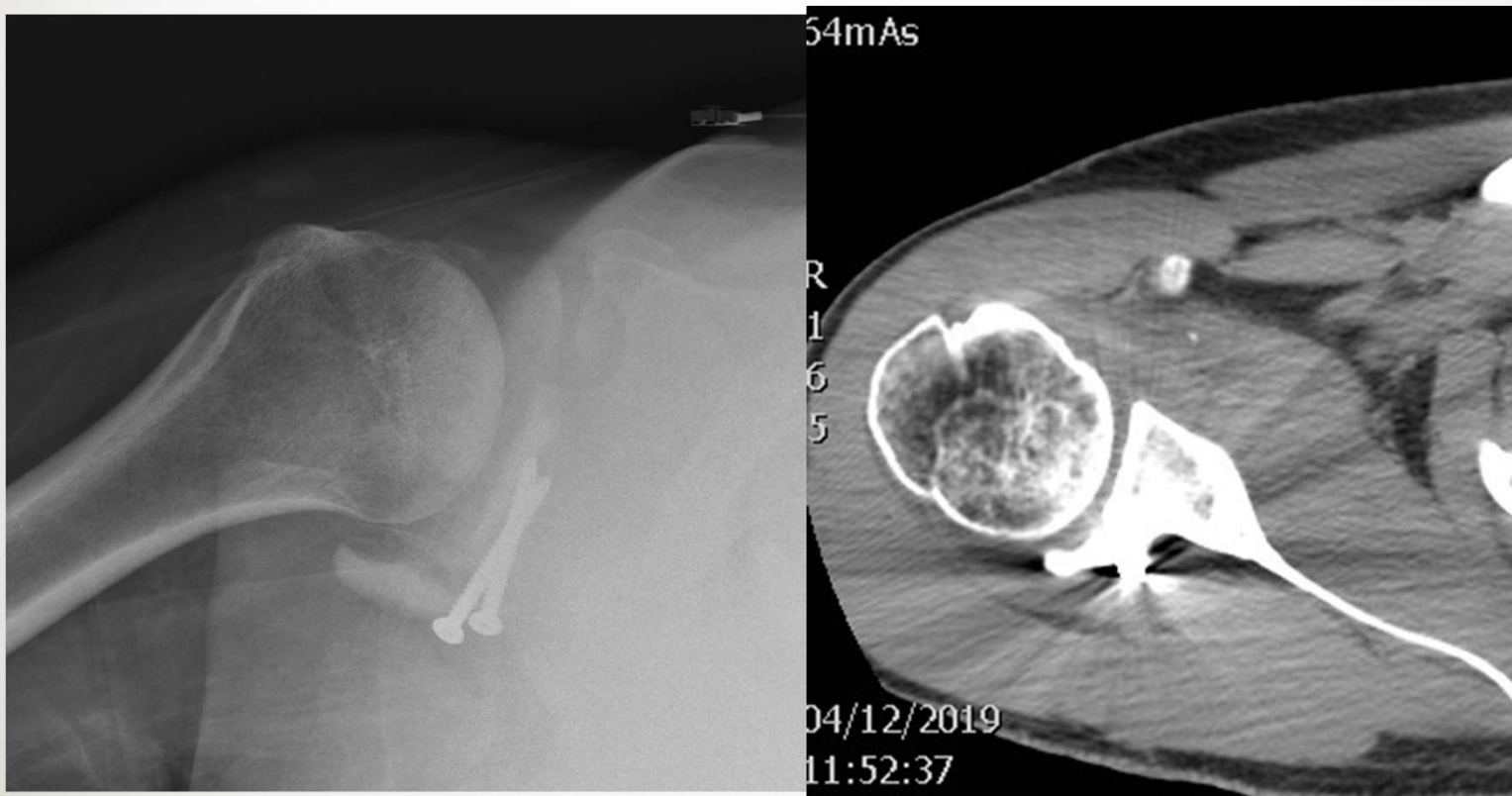
Why did it Fail?

- Most Repairs to Well

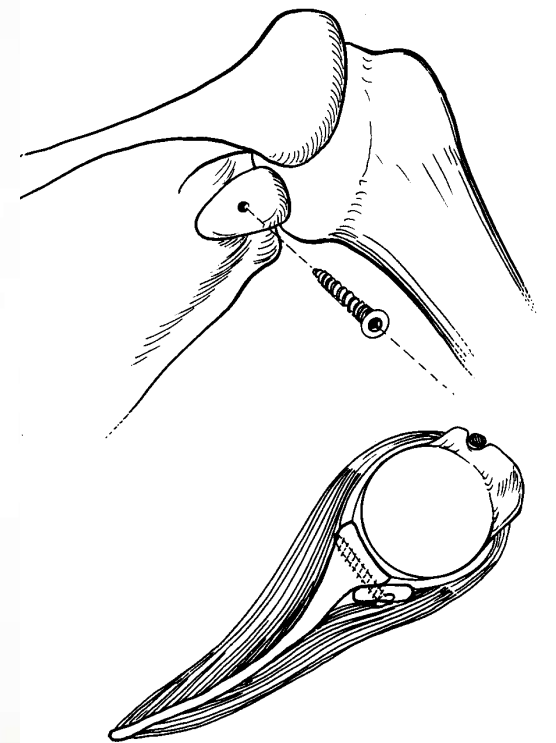
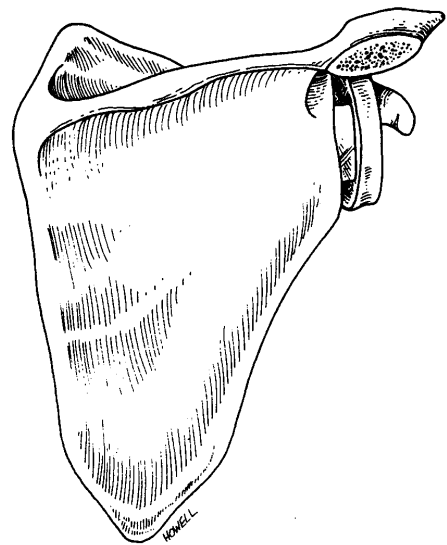
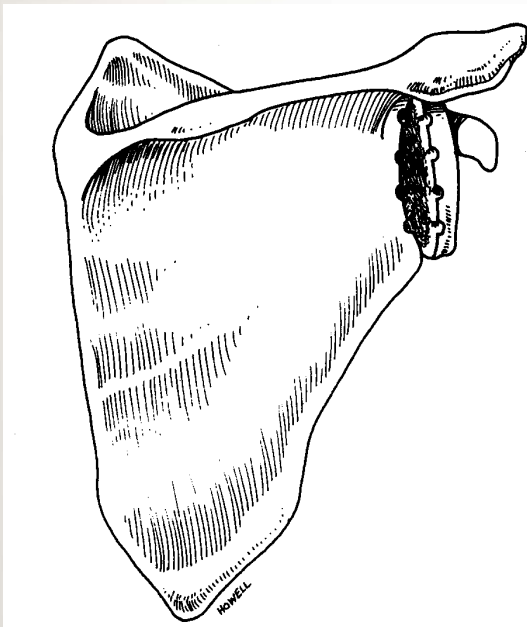
Why did this one Fail?

What would you do now?

Open Posterior Capsulorrhaphy Extra-Articular Iliac Crest Graft



What Other Options Exist?

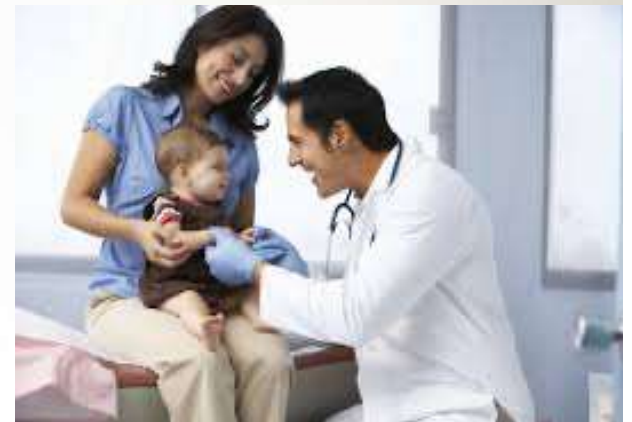

Other Questions for the Panel

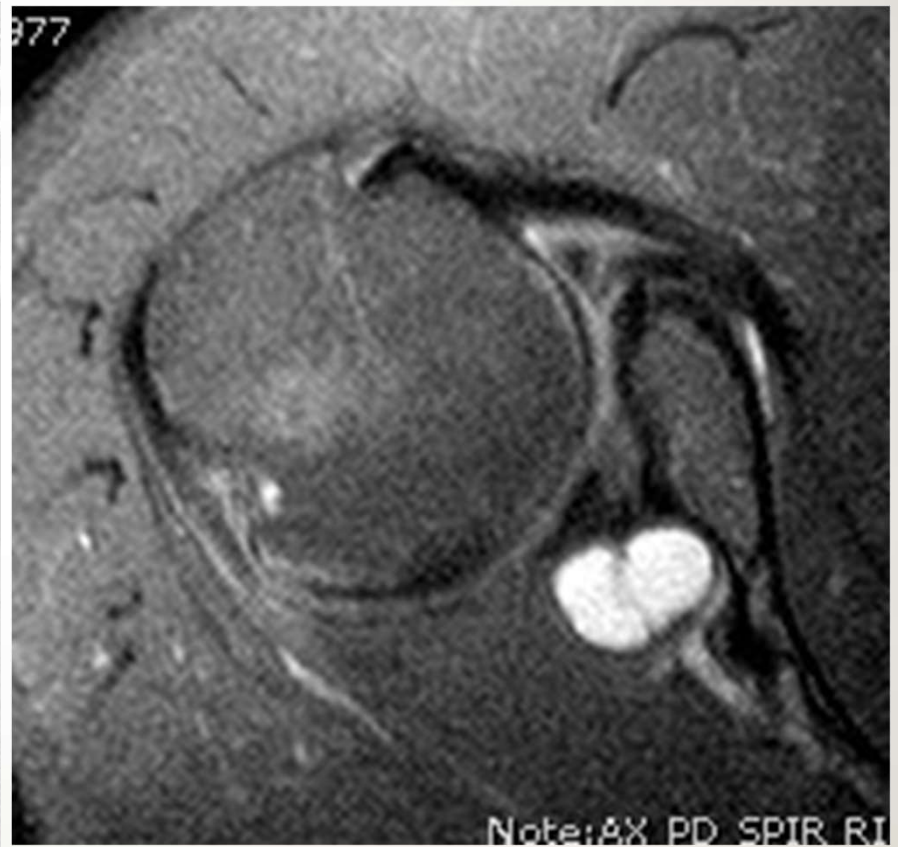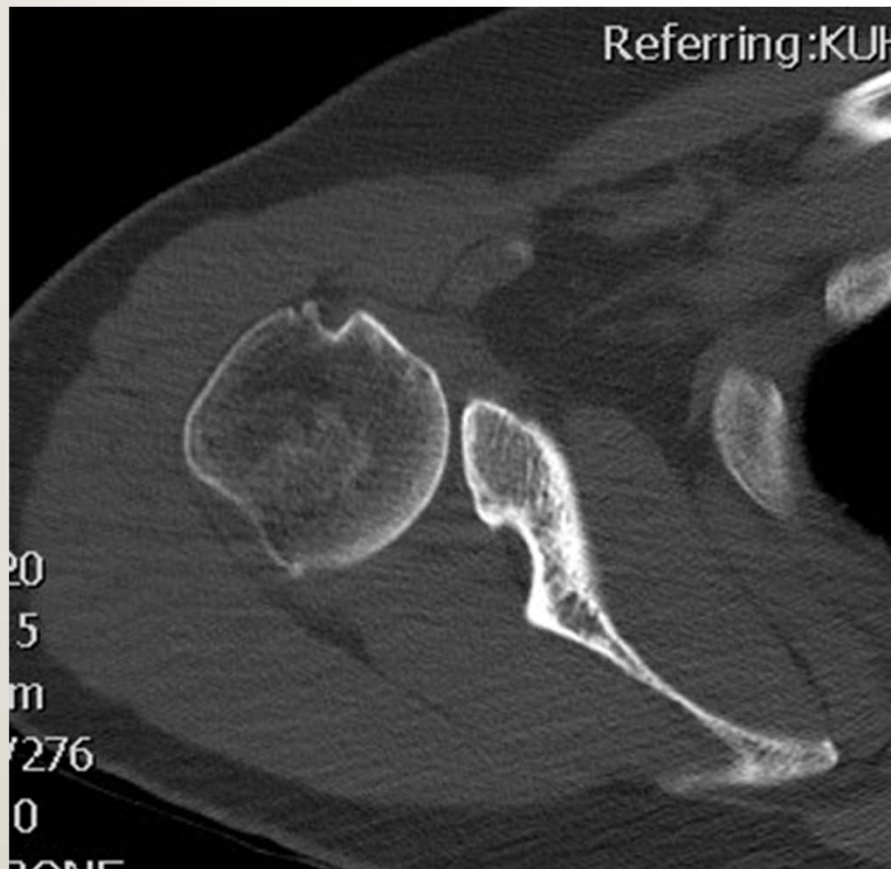
- *Describe your Postop Care?*
- *Is this a precursor to B2 Glenoids?*
- *Do you treat Throwing Athletes Differently?*
- *How do you distinguish between Demonstrable Posterior Instability and Volitional Posterior Instability?*

Case 2

- 34 year old Pediatric Cardiologist
- Symptoms for Repetitive Tennis
- Pain, Popping, Mild Slipping
- Pain at Night Now



Severe Glenoid Hypoplasia Spinoglenoid Notch Cyst

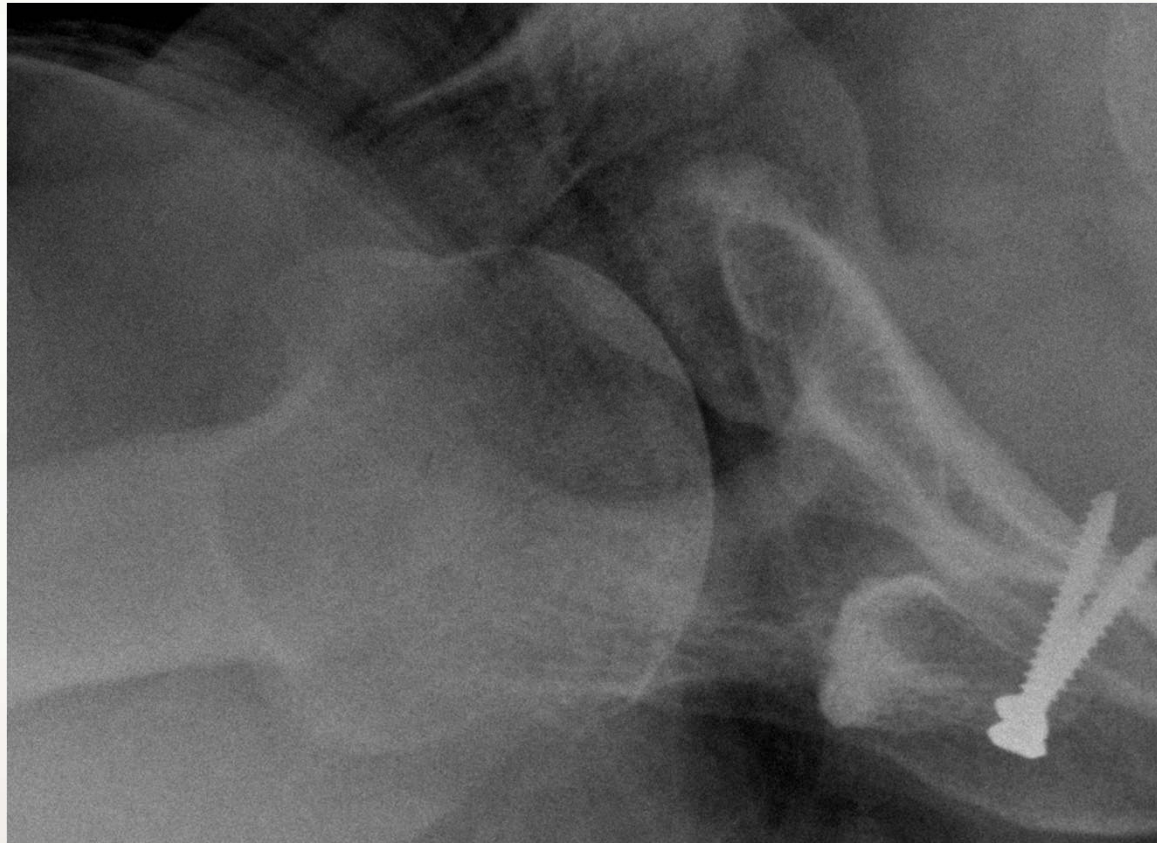


Hypoplastic Glenoid

*I live in Tennessee-
Am I the Only One who Sees This?*



Decompress Cyst Bone Graft to Buttress Cartilage



Thanks!

