



**Common Intertrochanteric
Femur Fractures**


Richard T. Laughlin, MD
University of Cincinnati College of Medicine




1



No disclosures related to this presentation




2



EPIDEMIOLOGY

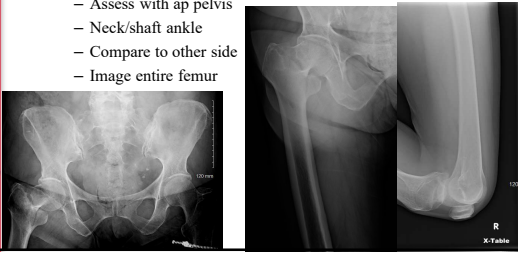
- 90% of hip fractures occur in people over the age of 60
- Nearly 250K trochanteric hip fractures per year
- Trochanteric hip fractures outnumber femoral neck fractures 2:1
- 20% mortality at one year



3

Anatomy


- Osseus anatomy
 - Assess with ap pelvis
 - Neck/shaft ankle
 - Compare to other side
 - Image entire femur



University of CINCINNATI

4

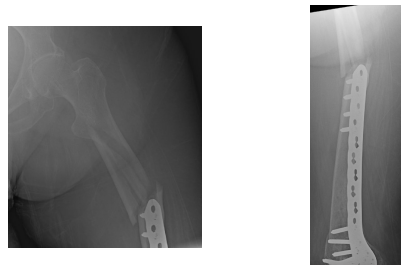
Image the entire femur



University of CINCINNATI

5

Image the entire femur

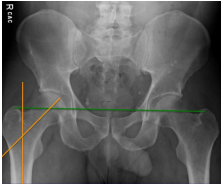


University of CINCINNATI

6

Intertrochanteric Fractures

- Note neck/shaft angle
- Note relationship of greater trochanters
- Aim is to recreate the normal anatomy

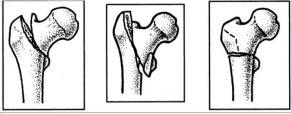


University of CINCINNATI

7

Intertrochanteric Femur Fracture Classification

AO/OTA




- 31A
- Proximal femur, trochanteric segment

University of CINCINNATI

8

Intertrochanteric Femur Fractures stable vs unstable

- Stable
 - Lesser trochanter intact
 - Usually 2 part
 - No fracture of lateral cortex





University of CINCINNATI

9

Intertrochanteric Femur Fractures
stable vs unstable




- Unstable
 - More than 2 parts
 - Lesser trochanter off
 - Includes reverse oblique patterns



10

SLIDING HIP SCREW



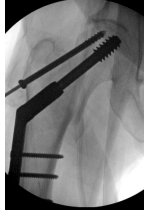

- 2part stable
- Lateral cortex intact
- Lesser trochanter intact or "small"
- Combined IT +shaft




11

SLIDING HIP SCREW

- 2part stable
- Lateral cortex intact
- Lesser trochanter intact or "small"
- Combined IT +shaft




12




Intertroch + shaft



- Radiolucent flat top table
- Intertroch first
- Retrograde femoral nail
- Schantz pins to control middle segment
- Multiple pins for provisional reduction
- Can be difficult to get good lateral xray




13



Intertrochanteric Femur Fracture plus Shaft fracture





14



Intertrochanteric Femur Fracture IM Rod


- Unstable
 - More than 2 parts
 - Lesser trochanter off, medial or posteromedial comminution
 - Includes reverse oblique patterns
 - Transverse fracture above the lesser troch
 - Extension to subtrochanteric region



15

**Intertrochanteric Femur Fracture
IM Rod**

- Anatomic reduction prior to fixation
- Implant will not reduce fracture
 - Pins to joystick the fracture
 - Bone hook over the anterior femur to reduce neck/calcar

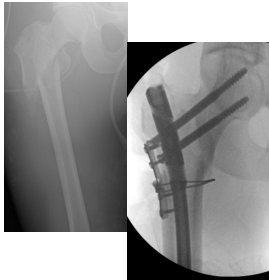


From the OTA fracture lecture series

16

**Intertrochanteric Femur Fracture
IM Rod**


- Provisional fixation to maintain reduction while reaming and passing nail



17

**Intertrochanteric Femur Fracture
IM Rod**


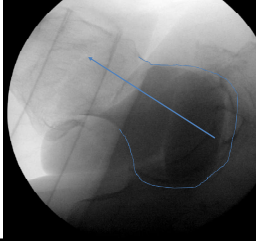
- Entry point
 - Starting point, stay out of fracture
 - Most cephalomedullary nails start at the tip of the greater trochanter
 - Inability to hold neck/shaft angle in valgus can allow the neck to fall into varus
 - An entry point that is too lateral ream out the lateral side of the trochanter and will allow the fracture to fall into varus



18

Intertrochanteric Femur Fracture IM Rod



- Entry point
 - Must get a true lateral
 - Pin should be at junction of anterior and middle third of the greater trochanter, in line with the femoral shaft
 - Too posterior and the rod abuts the anterior cortex



19


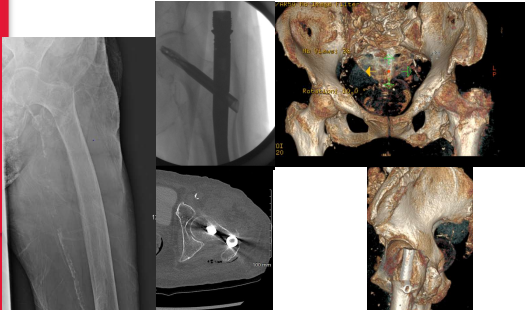
Intertrochanteric Femur Fracture IM Rod

- Take great care in making entry point over the guide wire
 - Common mistake is to ream out laterally causing fracture to go into varus
 - Cannulated awl is good option to avoid this



20


Intertrochanteric Femur Fracture IM Rod



21

**Intertrochanteric Femur Fracture
IM Rod**

- Reaming
 - In older population, measure canal with c-arm
 - May not need to ream at all

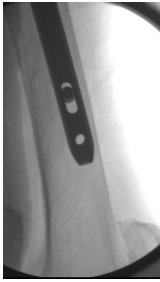


University of CINCINNATI

22

**Intertrochanteric Femur Fracture
IM Rod**

- Reaming
 - In older population, measure canal with c-arm
 - May not need to ream
 - Be wary of anterior bow of femur mismatch with rod
 - Check a lateral xray **BEFORE PUTTING IN PROXIMAL FIXATION**

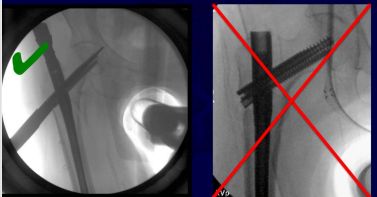


University of CINCINNATI

23

**Intertrochanteric Femur Fracture
IM Rod**


- prior to proximal fixation add traction to eliminate varus (as needed)



From the
OTA fracture
core lecture
series

University of CINCINNATI


24




Intertrochanteric Femur Fracture IM Rod

Medialization of head/neck

- Can happen if entry point too medial or in fracture
- Consider bone hook or provisional pins to maintain neck shaft alignment
- Won't correct with compression when the nail entry is in the fracture



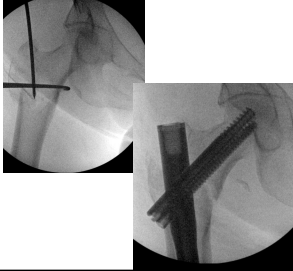
25




Intertrochanteric Femur Fracture IM Rod

Medialization of head/neck

- can happen if entry point too medial or in fracture
- Consider bone hook or provisional pins to maintain neck shaft alignment
- Won't correct with compression when the nail entry is in the fracture



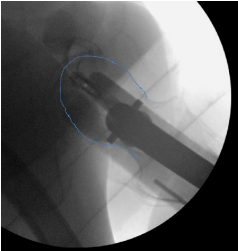
26



Intertrochanteric Femur Fracture IM Rod

Lateral xray/fluoro

- *perfect lateral shows the rod centered over the femoral head and neck
- *aiming arm can be rotated to direct pin trajectory to the center of the head
- *put guide pin all the way to subchondral bone
- tip apex distance <25mm

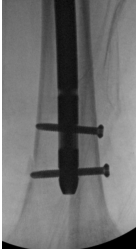


27

**Intertrochanteric Femur Fracture
IM Rod**

Distal interlocking screws

- for rotationally or axially unstable fractures
- Need a good reason not to put at least one in
- Care in making sure drill is centered in the hole of the nail, can blow out medial femoral cortex



University of CINCINNATI

28

**Intertrochanteric Femur Fracture
IM Rod**

Summary

- Anatomic reduction prior to placing implant
- Use provisional fixation/bone hook/joystick pins to maintain reduction
- Proximal fixation all the way to subchondral bone
- Post op should be able to weight bear as tolerated

University of CINCINNATI

29

Thankyou

University of CINCINNATI

30

Treatment

- pick a starting point that keeps the reamer from falling into the fx

medial starting point avoids more lateral fx

lateral starting point avoids more medial fx

31

Treatment

whatever implant is chosen...

- anatomic reduction *prior* to fixation**
- implant won't reduce the fracture
- avoid devitalizing fragments - joystick with pins
- need 'stable' fixation to allow early mobilization

University of CINCINNATI

32

University of CINCINNATI

33
