


Pelvic Fx's: What Should The Community Surgeon Do?

Michael T. Archdeacon, M.D., M.S.E.
Peter J. Stern Professor & Chairman,
Department of Orthopaedic Surgery
University of Cincinnati Medical Center

May 1, 2019



1

Disclosure

*Paid Consultant for
Stryker
Royalties
Stryker;
SLACK, Inc*



2

Disclosure

*Research Support:
OTA; FOT; DOD, NIH*



3


Disclosure




Deputy Editor:
JAAOS
Editorial Board:
**JOT; JBJS; JOR;
CORR**




4



Pelvic Fx





- High Energy To Significantly Fx Pelvis
- Potentially Life-Threatening Injury
- Aggressive Evaluation & Management
 - ❖ Team / Multi-Disciplinary Approach
 - ❖ ATLS Protocols



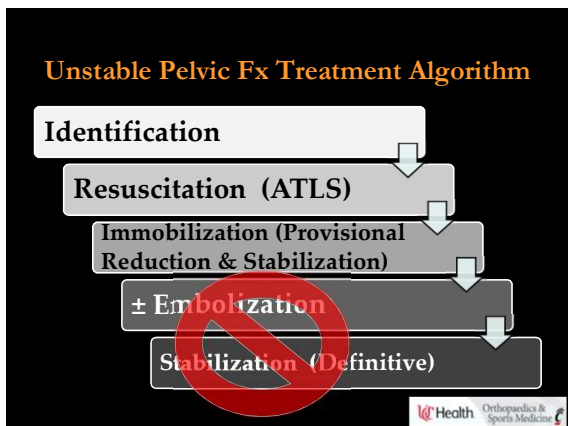
5

ASSOCIATED INJURIES

- Pelvic Fx's
 - ❖ Shock – 25 - 67%
 - ❖ Neurologic – 27 - 60%
 - ❖ ARDS – 6 - 19%
 - ❖ Thoracic – 19 - 43%
 - ❖ Urologic – 0 - 16%
 - ❖ Mortality – 14 - 37%




6



7

Patient Evaluation

- Identify Patients At High Risk For Mortality
 - ❖ Blunt Trauma
 - ❖ Hemodynamically Unstable
 - ❖ Mechanically Unstable Pelvic Fx
 - ❖ Elderly Patients
- Physical Exam
- Radiographic Evaluation

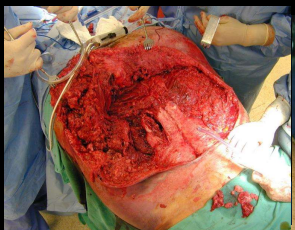


Q Health Orthopaedics & Sports Medicine

8

Physical Exam

- Visual Pelvic Exam
 - ❖ Lacerations In Perineal Region
 - ❖ Scrotal/Labial Ecchymosis
 - ❖ Open Pelvic Crush Wounds
 - ❖ Degloving Injuries
 - Morel-Lavalle



Courtesy of Mark Reilly, MD

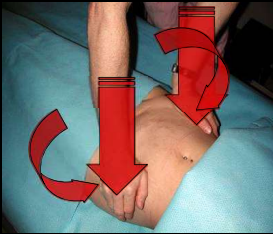
Q Health Orthopaedics & Sports Medicine

9

Physical Exam

- Pelvic Stability
 - ❖ Rock The Pelvis
 - AP Compression
 - ❖ Squeeze The Pelvis
 - Lateral Compression

Do This One Time Only




Courtesy of Mark Reilly, MD

Q Health Orthopaedics & Sports Medicine

10

Radiographic Exam – Screening AP Pelvis

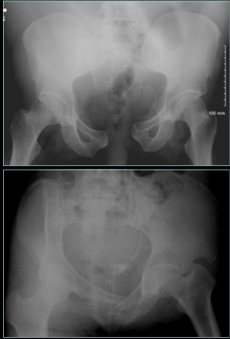


ate
lvic
on
ion
ection of
ve The
e Pelvic
xtensive
juries

Q Health Orthopaedics & Sports Medicine

11

Radiographic Exam – Screening AP Pelvis



- Utility Of Screening AP Pelvis Debated
 - ❖ Trauma Surgeons Argue CT Adequate
 - Delays Immediate Dx Of Severe Pelvic Ring Injuries
 - Delays Earlier Rx – Provisional Reduction / Stabilization
 - Civil et al; Ann Emer Med 1988
 - Resnik et al; Amer J Rad 1992
 - Gillott et al; J Trauma 1988

Q Health Orthopaedics & Sports Medicine


12

Provisional Pelvic Immobilization (Reduction)

- Sheet Wrap
- Pelvic Binder

❖ **Goals**

- Provisional Stabilization
- Prevent Further Hemorrhage



Health Orthopaedics & Sports Medicine

13

Sheet Wrap







❖ Not At Iliac Crests

❖ Not A Rope Around The Pelvis

Health Orthopaedics & Sports Medicine

14

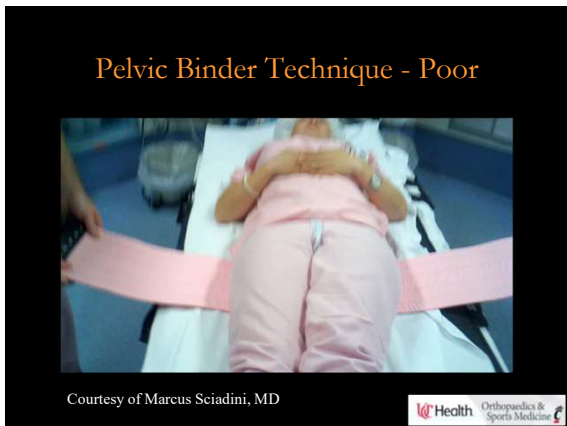Pelvic Binder



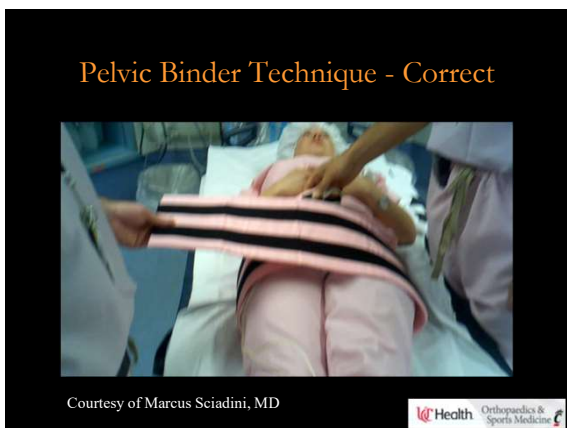Pelvic Binder

Health Orthopaedics & Sports Medicine

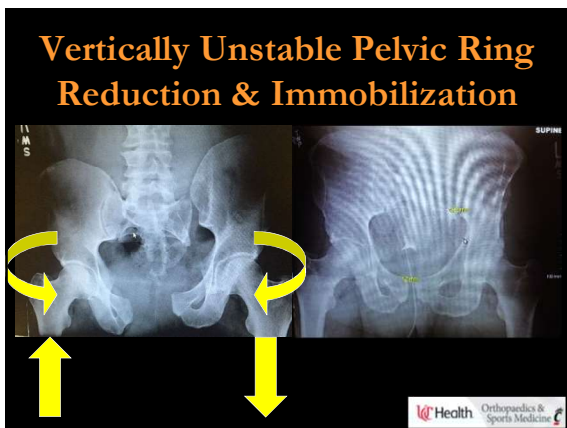
15



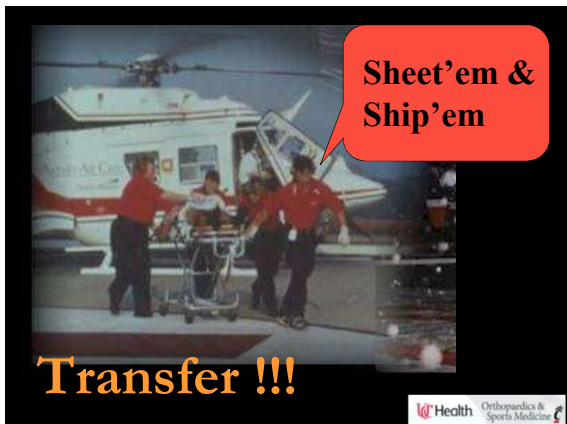16



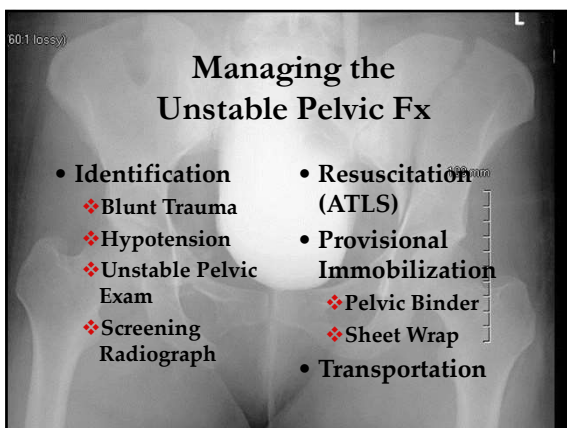
17



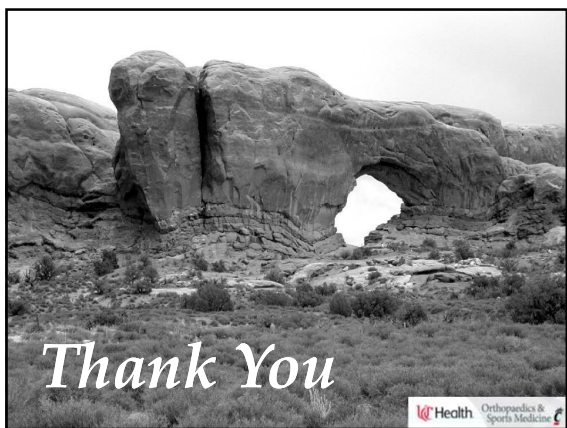18



19



20



21
