
Indiana University Health

Proximal Tibia Nailing: Tips and Tricks


Walter W. Virkus, MD
*Associate Professor
Vice Chair Clinical Affairs
Indiana University School of Medicine
Director, Orthopedic Trauma Service
IU Health Methodist Hospital
Indianapolis, IN*

5/4/2019

1

Proximal tibia nailing: Why not plate?



- Plating not always a reasonable option
 - Soft tissue compromise
 - Technically easier to span entire bone
 - Segmental fractures
 - Pathologic fractures
- Advantages of nails
 - Load sharing rather than load bearing
 - Nailing often allows for earlier weight bearing



2

Evidence for Nailing


- Biomechanical studies of proximal tibial metaphysis nail versus plate constructs show nails have:
 - Improved stiffness and resistance to axial loads, bending, and torsion vs. unilateral plate
 - Comparable stiffness to double plating
- Clinical evidence lacking



3

Goal

- Obtain and maintain reduction
 - During every reamer pass
 - During nail insertion
- Fractures usually reduce in extension
 - Difficult to maintain sufficient extension throughout operation




ORTHOPEDIC TRAUMA SERVICE

4

Common Deformities

- Angulation: Valgus and Procurvatum
- Posterior translation of distal segment
- Causes
 - Poor starting point for nail
 - Reaming with fracture displaced
 - Poor nail morphology
 - Not as much of a problem with modern nails with more proximal Herzog bend



ORTHOPEDIC TRAUMA SERVICE


5

Keys to Success

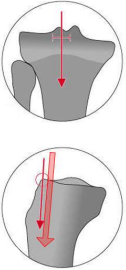
- 1) Perfect starting point
- 2) Maintain reduction during reaming
 - Only ream the path where you want the nail
- 3) Use blocking screws or drill bits
 - From the beginning of the case
 - To salvage an unacceptable reduction when the nail deforms the fracture

ORTHOPEDIC TRAUMA SERVICE

6


Starting Point 

- A bad starting point will cause the nail to malreduce the fracture
- AP view
 - In line with where you want the nail to go
 - Lateral to midline
 - Medial side of the lateral tibial eminence
- Lateral view
 - The apex of the anterior tibial cortex and the plateau

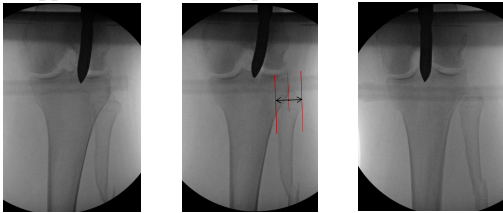


TRAUMA SERVICE

7

Starting Point 


- Rotation of leg can affect radiographic appearance of starting point



Externally rotated Internally rotated

ORTHOPEDIC TRAUMA SERVICE

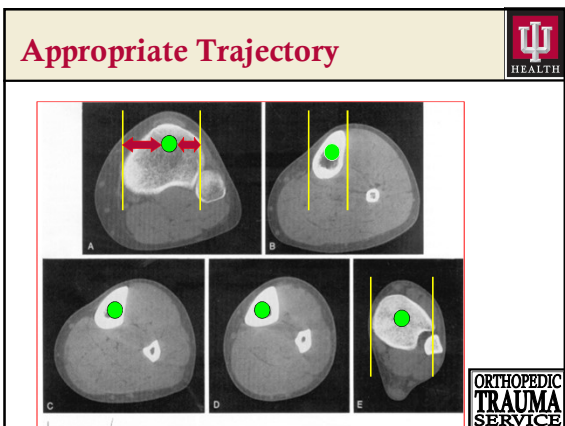
8

Starting Point 

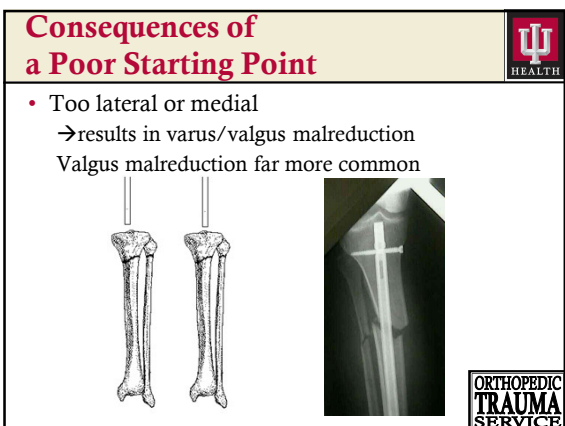
- Using a guide pin instead of an awl allows for correcting mistakes more easily
 - Pin can be pushed around by patella
 - Awl can push patella out of the way
- Trajectory of entry just as important as site of entry
 - Avoid aiming too posterior
 - Path must be directly adjacent to the anterior cortex
 - Keep guide wire in the path where the nail will go

ORTHOPEDIC TRAUMA SERVICE


9



10




11



12

Consequences of a Poor Starting Point

- Too far distal on the anterior cortex
→ results in procurvatum.
- Be careful not to ream out the anterior cortex
 - Causes nail entry point to migrate anterior/distal

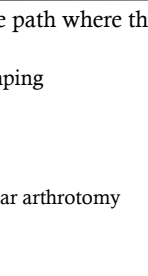


ORTHOPEDIC TRAUMA SERVICE

13

Maintain Reduction During Reaming

- Allows reamer to stay in the path where the nail should be placed
 - Percutaneous or open clamping
 - Provisional plating
 - External fixation
 - Keep knee semi-extended
 - Medial/Lateral parapatellar arthrotomy
 - Suprapatellar nailing

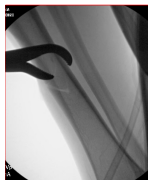



ORTHOPEDIC TRAUMA SERVICE

14

Open Clamping

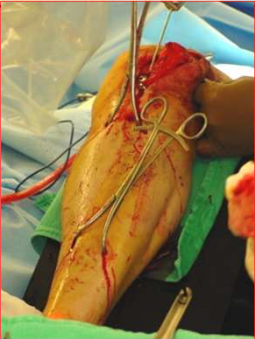
- Good for open fractures
- Anterolateral or posteromedial approach
 - Avoid incisions over the anteromedial border of the tibia
 - Leave periosteum intact



ORTHOPEDIC TRAUMA SERVICE

15

Percutaneous Clamping




ORTHOPEDIC TRAUMA SERVICE

16

Provisional Plating

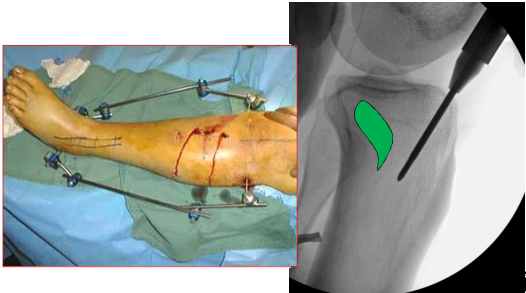
- Anterolateral and/or medial plate with unicortical or bicortical screws
 - Recon plate
 - small locking plate
- Multiple small fragment-specific plates



ORTHOPEDIC TRAUMA SERVICE

17

External Fixation

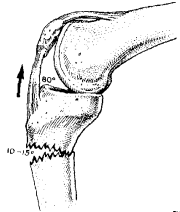


ORTHOPEDIC TRAUMA SERVICE

18

Semi-extended Nailing

- Helps to avoid procurvatum deformity
- Parapatellar arthrotomy – medial or lateral
 - Alternative: retinacular release while staying extrasynovial
- Suprapatellar nailing




ORTHOPEDIC TRAUMA SERVICE

19

Suprapatellar nailing

- Advantages
 - Incisions avoid infrapatellar branch of saphenous n.
 - Semi-extended positioning facilitates reduction
 - Instrumentation protects patellofemoral joint from iatrogenic injury
 - Assuming proper surgical technique

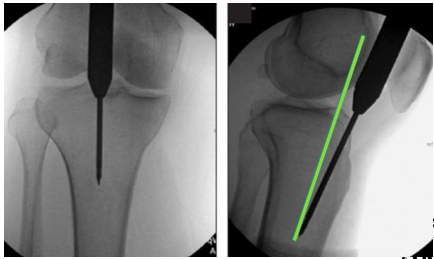


ORTHOPEDIC TRAUMA SERVICE

20

Suprapatellar nailing

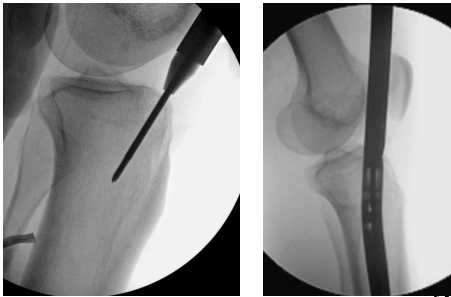
- Potential difficulties
 - Optimizing both starting point and trajectory



ORTHOPEDIC TRAUMA SERVICE

21

Suprapatellar nailing

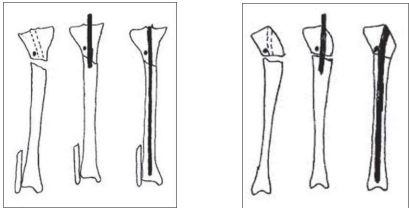


ORTHOPEDIC TRAUMA SERVICE

22

Blocking Screws

- Can help prevent malreduction
- Can salvage a poor reduction
- Blocking drill bits or Steinman pins are alternatives

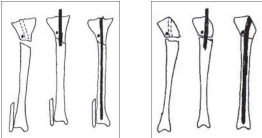


ORTHOPEDIC TRAUMA SERVICE

23

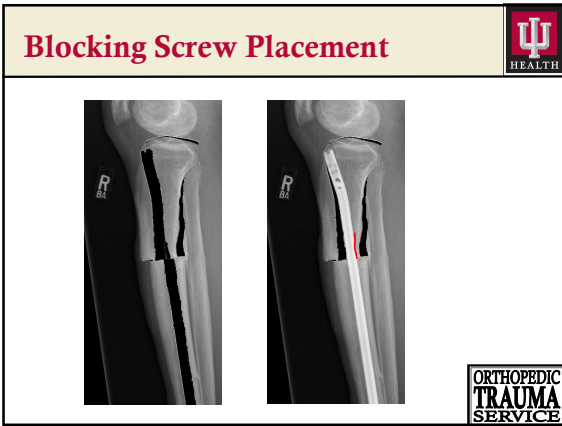
Blocking Screw Placement

- Universal Rule: put the screw...
 - where you don't want the nail to go
 - Where you want to move a cortex away from the nail
- Rule of thumb
 - put the screw on the concave side of the deformity

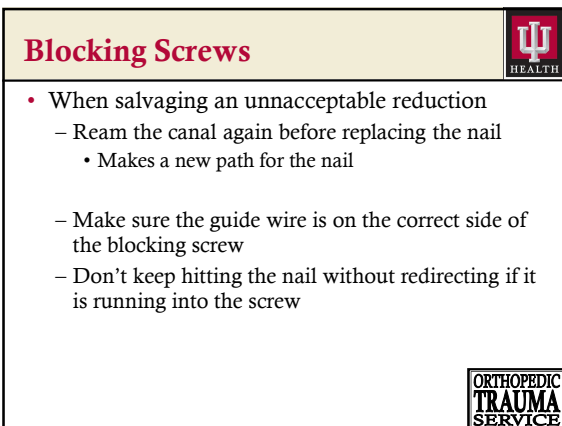


ORTHOPEDIC TRAUMA SERVICE

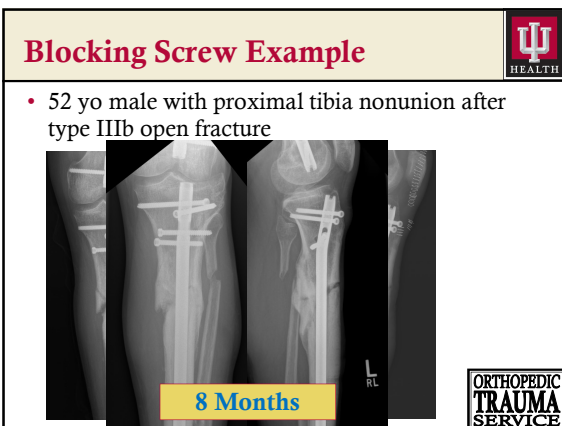24



25




26



27

Final Tip

- When placing the nail, don't judge sagittal plane malreduction until nail is seated




ORTHOPEDIC
TRAUMA
SERVICE

28

Considerations

- Suprapatellar or arthrotomy
- Small plates and screws out of nail path
- Sagittal plane "corrects itself" with bumps
- Easier to get good alignment in proximal and distal fractures



ORTHOPEDIC
TRAUMA
SERVICE

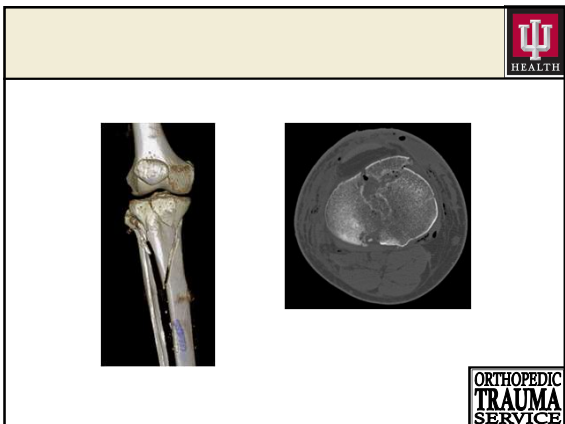29

33yo male

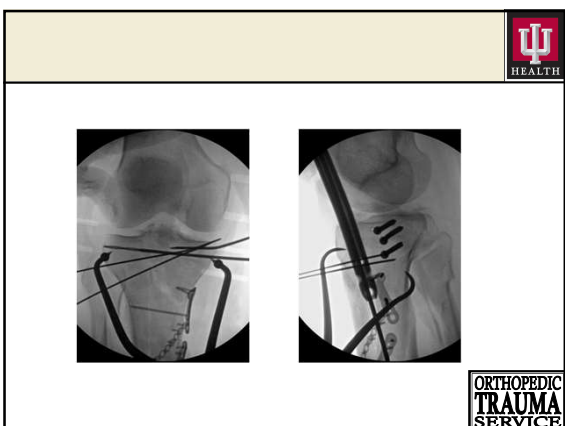


ORTHOPEDIC
TRAUMA
SERVICE

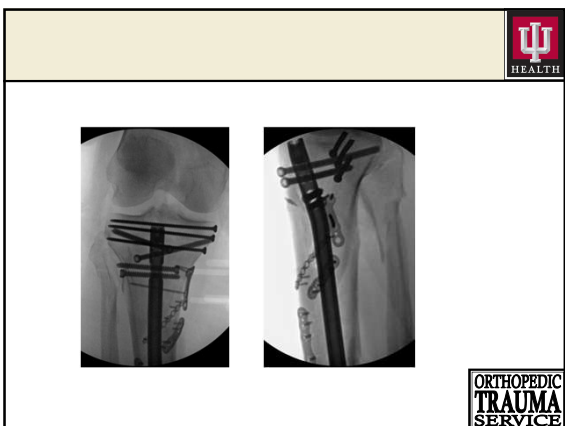
30



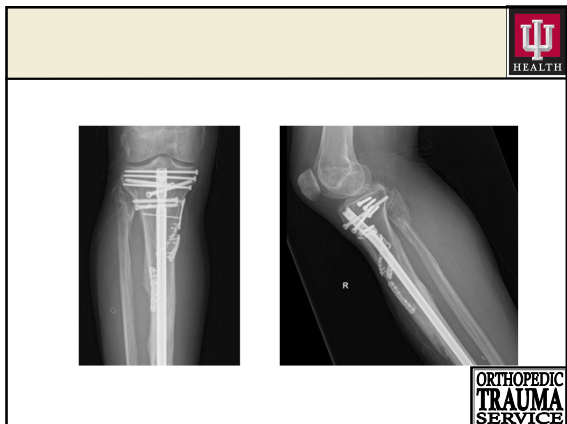
31



32



33



34

Proximal Tibial Nailing – Case #1

- 47 yo male police officer
 - Motorcycle patrol
 - Struck by a SUV while approaching a construction site
 - Patient flipped several times after leaving motorcycle
 - Type III open R tibia/fibula fracture

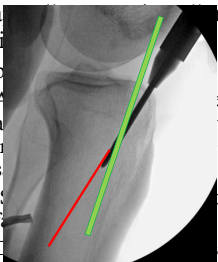



PSI HEALTH logo in top right, ORTHOPEDIC TRAUMA SERVICE logo in bottom right.

35

The Challenges

- Supracondylar technique
 - Supracondylar
 - Anterior knee injury to
 - of leg
 - age to patellofemoral joint



PSI HEALTH logo in top right, ORTHOPEDIC TRAUMA SERVICE logo in bottom right.

36

The Challenges



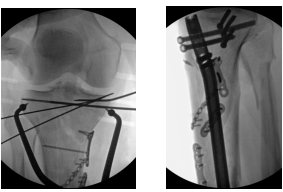


Plates / screws / drill





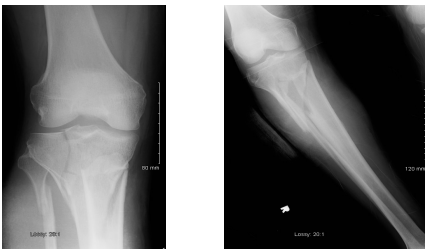
37

Liberal use of Small Plates to Hold Reduction

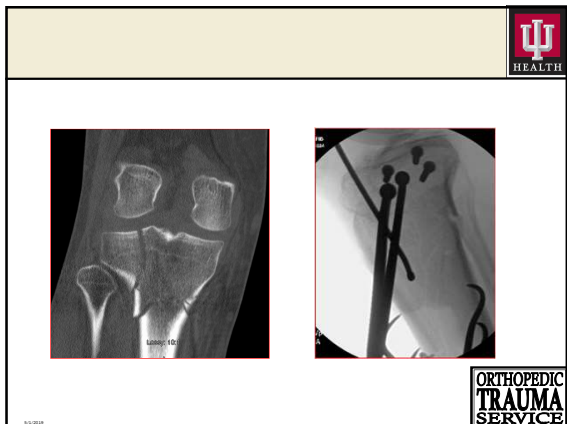


38

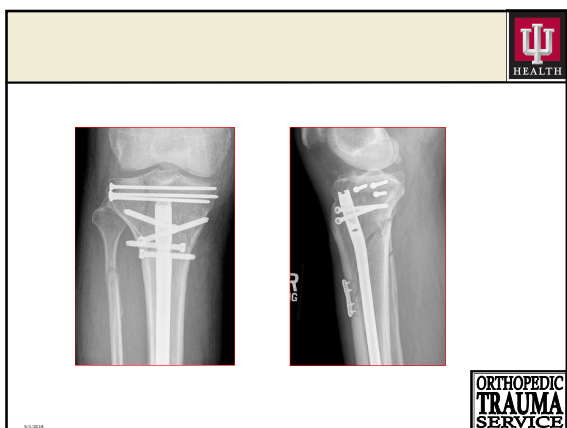
35 yo Female



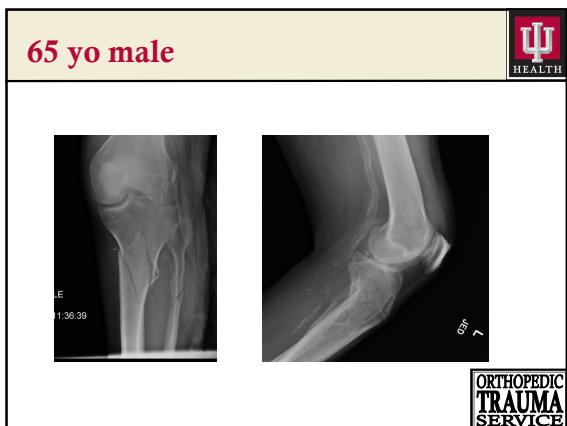39



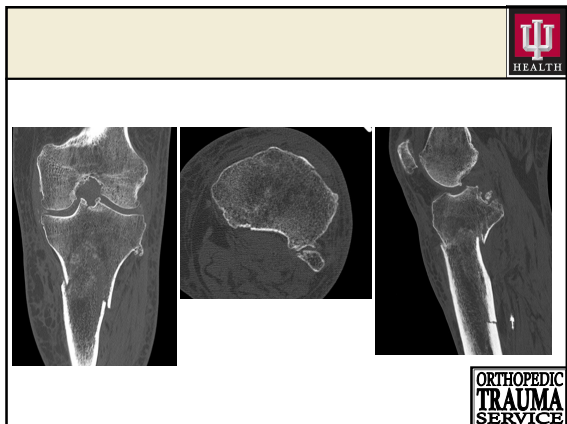
40



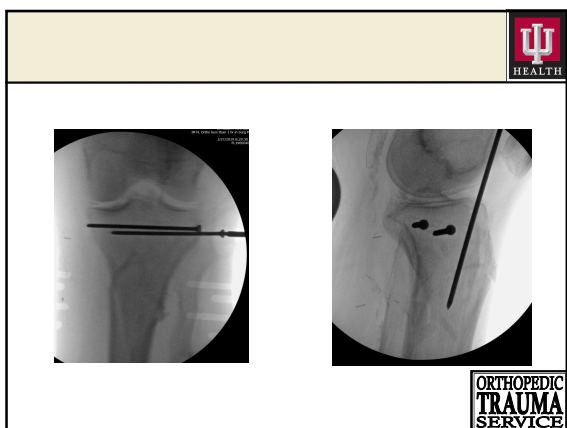
41



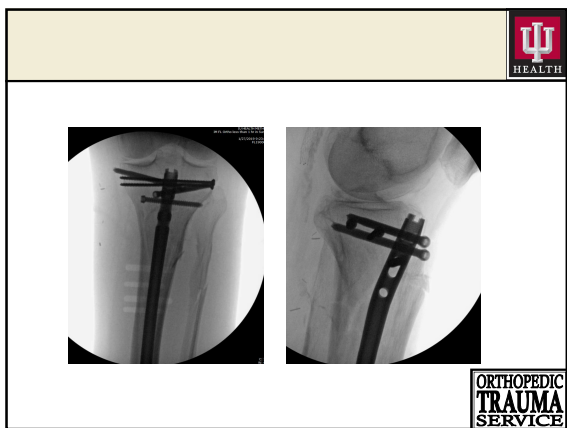
42



43



44



45

IU Proximal Tibia Results

- 87 patients with 12 mos FU
 - 12% NU
 - 12% deep infections (6/7 in open fractures)
 - 26% unplanned reoperation

ORTHOPEDIC TRAUMA SERVICE

46

Proximal Tibia Fracture Nailing Summary

- Don't settle for a mediocre starting point or guidewire placement
- Maintain reduction by any means necessary while reaming
- Use blocking screws when necessary

ORTHOPEDIC TRAUMA SERVICE

47

Indiana University Health

Thank You

5/1/2019

48