

Management of Anterior Shoulder Instability

UC Health Orthopaedics & Sports Medicine

AMERICAN ATHLETIC CONFERENCE

UC BERKELEY

1

Angelo J. Colosimo, MD

Head Orthopaedic Surgeon University of Cincinnati Athletics
Director of Sports Medicine University of Cincinnati Medical Center
Associate Professor of UC College of Medicine
Medical Director Holmes Sports Medicine

UC Health Orthopaedics & Sports Medicine


AMERICAN ATHLETIC CONFERENCE

UC BERKELEY

2

Introduction

- The shoulder is an inherently unstable joint, but allows for great range of motion



UC Health Orthopaedics & Sports Medicine


AMERICAN ATHLETIC CONFERENCE

UC BERKELEY

3

Introduction

- **Definitions:**
 - **Laxity:** loss of centering of the humeral head on glenoid
 - **Instability:** disability due to laxity
 - **Multi-directional instability:** disability due to inferior laxity with anterior and/or posterior laxity



Health.
Orthopaedics &
Sports Medicine


AMERICAN
ATHLETIC CONFERENCE

C
BEARCATS

4

Classifications of Instabilities

- Two major categories historically:
 - **Acute Traumatic:** single traumatic event due to a sudden episode
 - **Chronic/Throwing Athlete:** a chronic situation or subtle anterior subluxation in a thrower



Health.
Orthopaedics &
Sports Medicine


AMERICAN
ATHLETIC CONFERENCE

C
BEARCATS

5

Introduction – Acute Traumatic

- Locked anterior dislocation most common
- Historically - eliminate recurrent instability
- Compromise ROM
- Success rates



Health.
Orthopaedics &
Sports Medicine

AMERICAN
ATHLETIC CONFERENCE

C
BEARCATS

6

Introduction

- Attention to athletes
- Subtle instability (subluxation)
- Higher standard for success
- Maintain full ROM
- Restoration of stability
- Avoid over-tightening
- Selective capsular shift





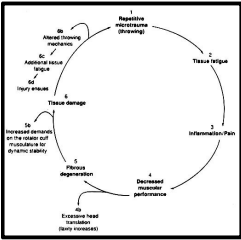





7

Introduction

Etiology of Instability:

- Normal balance between mobility and stability
- Repetitive overhead throwing
- Attenuation of static stabilizers
- Muscle fatigue-subluxation



8

Introduction

- **Primary or Classic Neer Impingement**
- **Secondary Impingement:**
 - Instability
 - Mass lesion
 - Neurologic Injury
- **Internal Impingement**
 - Instability







9

Classifications of Instabilities

- **Classification:**
 - Etiology
 - Degree
 - Direction
 - Duration
 - Frequency
 - Volition











10

Diagnosis

- **History:**
 - Feelings of instability
 - Dead arm syndrome
 - Radicular symptoms
 - Stiffness or loss of motion
 - Popping or clicking










11

Diagnosis

- Determine direction and degree of instability











12

Differential Diagnosis

- Brachial plexus syndrome (burner)
- Shoulder subluxation (dead arm)
- Rotator cuff pathology
- AC joint separation
- Cervical disc disease
- Axillary nerve palsy
- Fracture/Dislocations

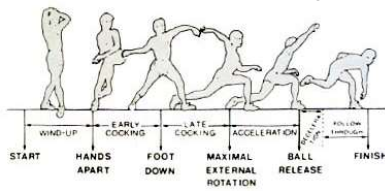









13

Diagnosis – History




- **History:**
 - Single event vs. repetitive microtrauma
- **Pain:**
 - Location, Duration, Phase of throwing



14

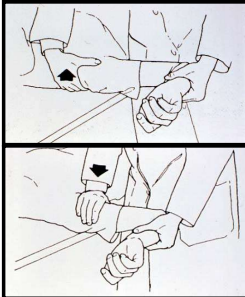
Physical Examination








15

Instability Physical Examination

- Apprehension sign
- Relocation test
- Sulcus sign











16

Radiographic Evaluation

- AP (subchondral cysts/sclerosis)
- Lateral in IR and ER
- Supraspinatus outlet (Y view)
- Axillary view











17

Advanced Imaging

- **MRI:** most sensitive and non-invasive tool to evaluate rotator cuff pathology
- Ultrasound
- Arthrogram
- Arthroscopy

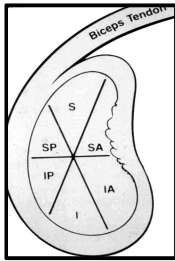









18

Arthroscopic Shoulder Evaluation




- Anterior inferior (Bankart)
- Posterior (reverse Bankart)
- Posterior superior (Internal impingement)
- Anterior superior (Andrews)
- **Superior Labrum Anterior Posterior (SLAP)**
- Posterior inferior (Bennett's lesion)



19

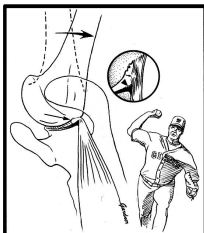
Internal Impingement








20

Internal Impingement




- Pain with Abducted, externally rotated shoulder (ABER)– late cocking-phase of throwing
- Pain Relieved with relocation test of Jobe
- Posterosuperior labral lesions and articular sided rotator cuff tears seen on arthroscopy
- MRI and arthroscopy
 - High correlation with diagnosis of RCT and labral injuries
 - Low correlation with diagnosis of chondral injuries and tendonitis



21

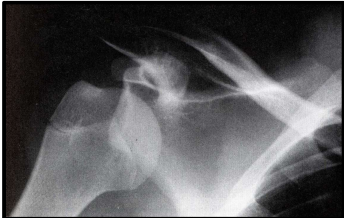
Anterior Instability








22

Anterior Instability

- Most common instability seen
- 80% - 85% of all shoulder dislocations











23

Anterior Instability

- **Traumatic:**
 - Acute subluxation
 - Recurrent subluxation
 - Acute anterior dislocation
 - Recurrent anterior dislocation
- **Atraumatic**
 - Voluntary

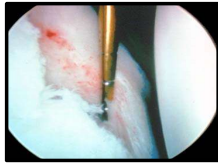
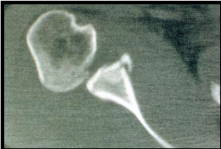









24

Anterior Instability

- Pathology of instability with failure at the glenoid:
 - Classic Bankart lesion
 - Bony Bankart lesion
 - Isolated capsular tear

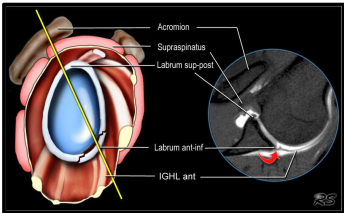










25

Anterior Instability

- Failure in continuity:
 - IGHL stretches or attenuates
 - HAGL Lesion

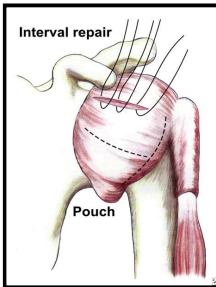







Robin Smithuis and Henk Jan van der Woude
Radiology department of the Rijnland hospital,
Leiden/Long and the Onze Lieve Vrouwe Gasthuis,
Amsterdam, the Netherlands


26

Anterior Instability

- Associated pathology in traumatic anterior shoulder instability:
 - Labral tears
 - Hill Sach's deformity
 - Capsule tear
 - SLAP lesion
 - Complete cuff tears
 - Partial cuff tears in subtle instability
 - Rotator Interval Defect
 - Bone Loss (Glenoid or Humeral Head)
 - HAGL Lesion





27


Anterior Instability

- Recurrent dislocation:
 - Age most important factor
15-25 y.o.a. have ~ 50-70%
redislocation rate
 - Severe trauma and/or
greater tuberosity fracture
lower rate of recurrence
 - Mean recurrence rate in
literature is 67%



Health.
Orthopaedics &
Sports Medicine







28


Anterior Instability Treatment

- Primary dislocation
 - **Conservative:** (gold standard)
 - Period of immobilization
 - Rehabilitation
 - Restriction of sports activities



Health.
Orthopaedics &
Sports Medicine







29


Anterior Instability

- Primary subluxation:
 - REHAB then more
REHAB
 - Restriction of sporting
activity



Health.
Orthopaedics &
Sports Medicine





30

Anterior Instability

- Surgical considerations:
 - Throwing athlete vs. non-throwing athlete
 - Contact sports vs. non-contact sports
 - Athlete vs. non-athlete
 - Dominant arm vs. non-dominant arm
 - Patient expectations
 - Bony Deformities



Health
Orthopaedics &
Sports Medicine







31

Anterior Instability

In the athletic population, since the redislocation rate is so high, there is a school of thought that if the patient will be rested anyway, the lesion should be fixed first, then rested and rehabbed. The attempt is to change the natural history and lower the redislocation rate.

Health
Orthopaedics &
Sports Medicine







32


Anterior Instability Treatment

- Surgical options for primary dislocation:
 - Acute arthroscopic fixation of Bankart
 - +/- Thermal capsular shrinkage
 - Immobilization
 - Rehabilitation



Health
Orthopaedics &
Sports Medicine

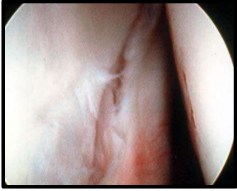







33

Treatment

- The pathology of the unstable shoulder involves both the labral and capsular tissue
- Both capsular and labral lesions must be dealt with



34

OPUS Bankart Repair Video







35

OPUS SLAP Repair Video



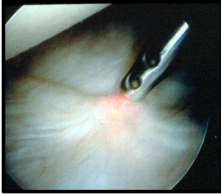







36

Treatment of the Capsule

- **L.A.C.S.** (Laser assisted capsular shift)
 - Indicated in unidirectional or multidirectional instability in the presence or absence of associated labral pathology
 - Fallen out of favor
 - High failure rates reported











37

Recurrent Anterior Instability

- **Surgical options:**
 - Arthroscopic
 - Open selective shift
 - Thermal capsulorrhaphy???
 - Bankart repair











38

Arthroscopic Capsular Shift

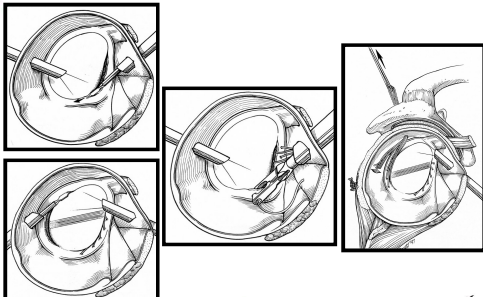
- Eliminates some of the morbidity of open procedures
- Mechanically decreases the size of the capsule
 - Mobilize the inferior capsule
 - Reattach more superiorly










39

Arthroscopic Capsular Shift



The images illustrate the arthroscopic capsular shift procedure in four stages: 1) Identification of the capsular defect, 2) Dissection and mobilization of the capsular tissue, 3) Creation of a capsular shift, and 4) Final repair and tightening of the capsule.

40

Open Surgical Technique

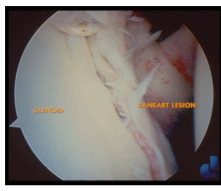







41

Open Procedures for Instability

- **Bankart repair:**
 - Classic Bankart
 - Suture anchor
- **Capsular tightening:**
 - Lateral shift (Bigliani)
 - Medial glenoid shift (Jobe)
 - Horizontal shift / rotator interval (Altchek)
 - Posterior capsular shift



42

Open Capsular Shift

- Deltopectoral approach
- Divide subscapularis
- Identify
 - Capsular laxity
 - Rotator interval defect

Health Orthopaedics & Sports Medicine
AMERICAN ATHLETIC CONFERENCE
 REARCATS

43

Surgical Technique

- Latarjet
 - Bone Loss

Health Orthopaedics & Sports Medicine
AMERICAN ATHLETIC CONFERENCE
 REARCATS

44




Surgical Techniques

- Remplissage Procedure
 - Large engaging Hill-Sachs
 - Infraspinatus transferred to the defect

Health Orthopaedics & Sports Medicine
AMERICAN ATHLETIC CONFERENCE
 REARCATS

45


Treatment Algorithms for Instability








46

Principles of Treatment

- Immediate & correct diagnosis
- Avoid further damage
- Address underlying pathologies
- Restore normal anatomy and shoulder function











47

Treatment Algorithm

1. Acute first time traumatic anterior dislocation
2. Acute first time traumatic subluxation
3. Recurrent anterior dislocation (failed rehab)
4. Recurrent anterior subluxation
5. Multidirectional instability











48

Treatment Algorithm

- Acute first time traumatic anterior dislocation:
 - With Bankart
 - Without Bankart
 - Large Hill-Sach's with Bankart
 - Surgical vs conservative???











49

Treatment Algorithm

- Acute first time traumatic subluxation:
 - REHAB - REHAB - REHAB
 - Restriction of sports activity








50

Treatment Algorithm

- Recurrent anterior dislocation (failed rehabilitation):
 - With Bankart lesion:
 - Non-dominant arm/Bankart repair/open capsular shift
 - Dominant arm (thrower) - arthroscopic
 - With-out Bankart lesion:
 - Open anterior/inferior capsular shift










51

Treatment Algorithm

- Recurrent anterior subluxation with Bankart lesion:
 - Non-dominant arm
 - Open anterior/inferior capsular shift /Bankart repair
 - Dominant arm
 - Arthroscopic laser shrinkage vs open anterior capsular shift
 - Bankart repair via arthroscope











52

MDI Treatment Algorithm

- REHAB – REHAB
 - Failed rehabilitation:
 - Dominant arm – LACS
 - Non-dominant arm – LACS vs open capsular shift











53

Treatment

- Complex problems:
 - Multidirectional instability
 - Bony glenoid defects
 - Large Hill-Sachs deformity











54

Conclusions

- Clear understanding of normal anatomy and biomechanics
- Restoration of normal anatomy
- Selective correction of the abnormality

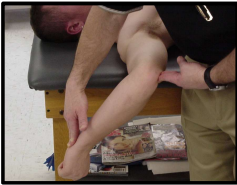









55

Conclusions

- Eliminate capsule laxity *without* sacrificing ROM
- Technically, do what works best in your hands
- Aggressive physical therapy



56

Thank You!







57
