


Case Presentation:
The Knee Cap Jamboree

Brian Grawe, MD
Assistant Professor
University of Cincinnati Medical Center
4/26/2019



UCHealth Orthopaedic Surgery and Sports Medicine

1

Brian Grawe, MD
Assistant Professor
Phone Number: 513-558-4516
Email: grawebn@ucmail.uc.edu



UCHealth Orthopaedic Surgery and Sports Medicine

2

Disclosures



- Consulting
 - Mitek
- Committee Member
 - AAOS, AOSSM,
- Journal Reviewer
 - AJSM, JSES, JBJS
- Clinical Trial Support
 - Zimmer
- Grant Support
 - DoD, OREF, Institutional funding
- Institutional Support
 - Zimmer, Stryker, Synthes, Smith & Nephew



UCHealth Orthopaedic Surgery and Sports Medicine



3

SJ

- 24 yo female
- 10 year history of left knee symptoms
 - Pain
 - Instability (knee cap gives out)
 - Locking catching
- Sustained a remote patellar dislocation
- Underwent VMO advancement 9 years ago
 - No relief

Current Issue

- ✓ Locking / catching is worse
- ✓ Feels like something is in there





UCHealth Orthopaedic Surgery and Sports Medicine

4

SJ


- BMI 24
- Physical Exam
 - Equal symmetric motion bilateral
 - Pain w/ patellar grind
 - Significant lateral apprehension of patella
 - 3+ quadrant mobility (other side 2)
 - No hyperextension (weakly + Beighton criteria)
 - Tibiofemoral stable in coronal / sagittal plane
- Normal 24 yo who is recreationally active



UCHealth Orthopaedic Surgery and Sports Medicine



5

❖ What to do next:
Nothing, advanced imaging, straight to surgery



For Review

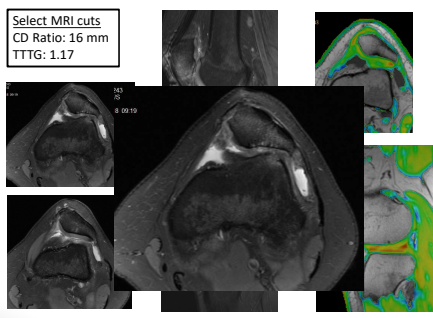
- ✓ Innumerable PT visits throughout lifetime
- ✓ NSAIDs on board
- ✓ Mechanical sx's now dominant



UCHealth Orthopaedic Surgery and Sports Medicine

6

Select MRI cuts
CD Ratio: 16 mm
TTTG: 1.17



❖ What to do next:
Nothing, kind of nothing, does a surgical solution exist?

UNIVERSITY OF CINCINNATI College of Medicine
UCHealth Orthopaedic Surgery and Sports Medicine

7

SJ

- Surgery (we are surgeons)
- Cadillac
 - TTO
 - MPFL
 - Cartilage recon (PJAC)
 - LR / loose body removal

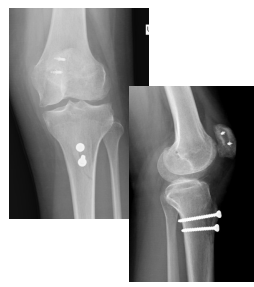


UNIVERSITY OF CINCINNATI College of Medicine
UCHealth Orthopaedic Surgery and Sports Medicine

8

SJ

- TTWB x 6 weeks
- CPM, CPM, CPM
- Brace to protect graft
- Get her going at 6 wks
*union acheived





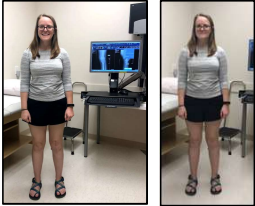
UNIVERSITY OF CINCINNATI College of Medicine
UCHealth Orthopaedic Surgery and Sports Medicine

9

SJ

F/U @ 6months

- >IKDC 86.2
- >KOOS 94.6
- >KOOS subscales
 - Symptoms/stiffness
 - 75 → 89.3
 - QOL
 - 56 → 75



UCHealth Orthopaedic Surgery and Sports Medicine

10

END



Thank you!



UCHealth Orthopaedic Surgery and Sports Medicine

11
