

Case Presentation

Failed PCL reconstruction



1

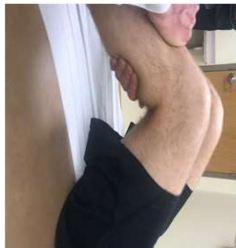- **27y, male**
- Construction worker and Soccer coach
- 2012 twisting injury while hiking, PCL rupture
- Symptoms: Left knee gives away with athletic activity, occasional swelling, stiffness, activity related pain
- 2017 isolated PCL reconstruction with hamstring autograft
- Never got better since surgery



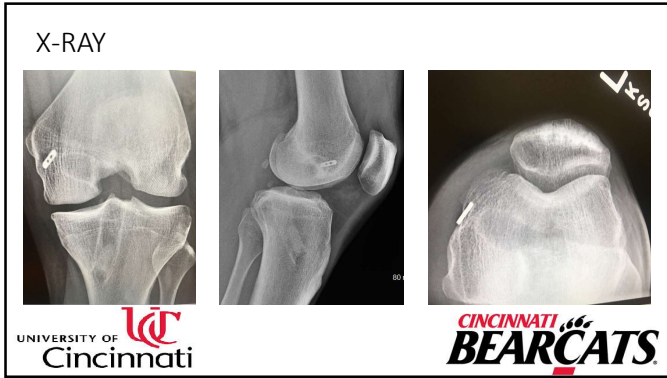
2

Physical Exam:

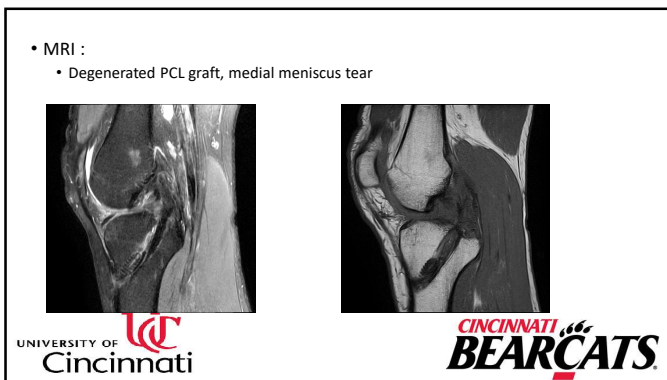
- Flex 0-130°
- Anterior Drawer –
- Lachman –
- McMurray + medial side
- Varus/Valgus ST -
- Posterior Sag Sign +
- Posterior Drawer Test +2
- Posterolateral Drawer Test +



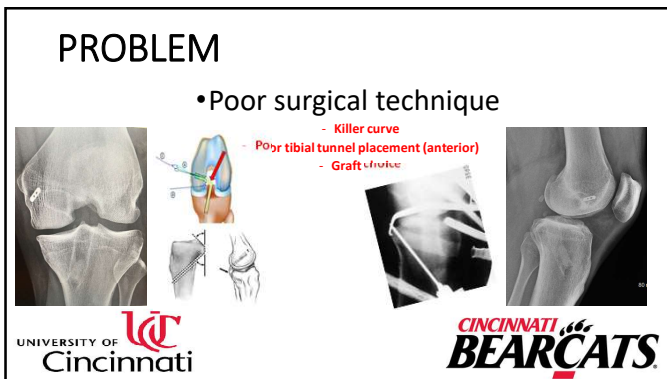
3



4



5



6

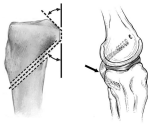
Plan?



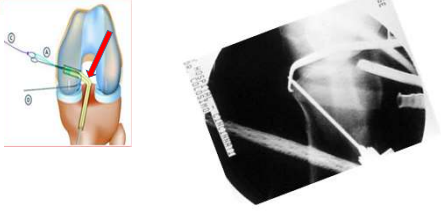
UNIVERSITY OF CINCINNATI **BEARCATS**

7

Double Killer Curve



Tibial Tunnel Placement



UNIVERSITY OF CINCINNATI **BEARCATS**

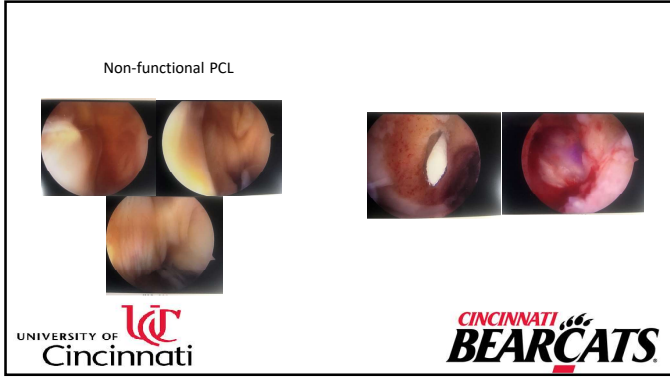
8

Exam under Anesthesia

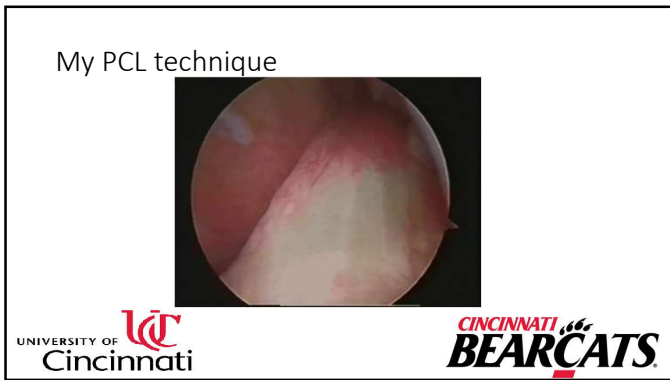


UNIVERSITY OF CINCINNATI **BEARCATS**

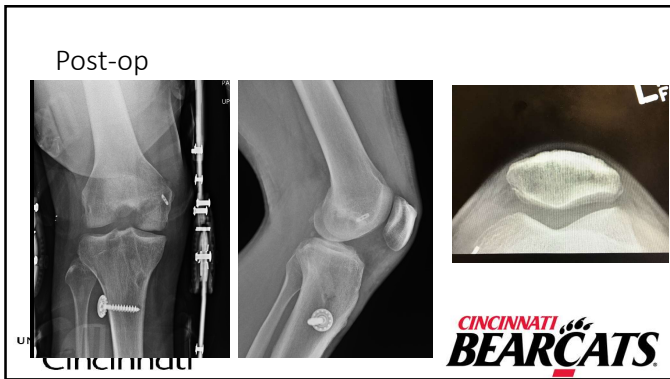
9



10



11



12
