

Treatment of Meniscal Tears

UC Health Orthopaedics & Sports Medicine

AMERICAN ATHLETIC CONFERENCE

UC REARCATS

1

Angelo J. Colosimo, MD

Head Orthopaedic Surgeon University of Cincinnati Athletics
Director of Sports Medicine University of Cincinnati Medical Center
Associate Professor of UC College of Medicine
Medical Director Holmes Sports Medicine

UC Health Orthopaedics & Sports Medicine

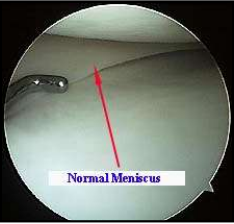
AMERICAN ATHLETIC CONFERENCE

UC REARCATS

2

Introduction

- Meniscus is integral in knee biomechanics
- Preservation is essential
- Meniscal surgery continues to evolve



Normal Meniscus

UC Health Orthopaedics & Sports Medicine

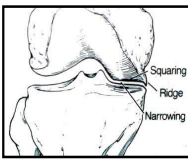
AMERICAN ATHLETIC CONFERENCE


UC REARCATS

3

Introduction

- Sutton (1897)
- King (1936)
- Fairbanks (1948)
 - Osteophyte formation
 - Flattening of marginal half of femoral surface
 - Joint space narrowing

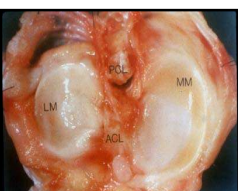





4

Meniscal Function

- Shock absorption
- Force transmission
- Lubricates joint
- Nutrition to chondrocytes
- Provides stability

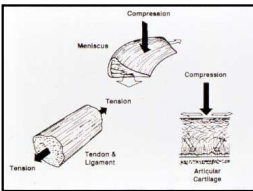





5

Meniscal Biomechanics

- ‘Hoop stress’
- Maintains shape and structure when axially loaded
- Increases surface area
- Decrease force per unit area






6

Meniscal Deficiency

- Decrease in surface area
- Increase force per unit area
- Decreases shock absorption
- Results in degeneration



Health Orthopaedics & Sports Medicine

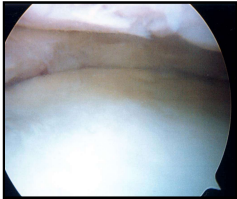
AMERICAN
ATHLETIC CONFERENCE

THE BEARCATS

7

Historical Treatment Options

1. Total meniscectomy
2. Partial meniscectomy
3. Meniscal repair



Health Orthopaedics & Sports Medicine

AMERICAN
ATHLETIC CONFERENCE

THE BEARCATS

8

The bottom line is to preserve the meniscus whenever possible!

Health Orthopaedics & Sports Medicine

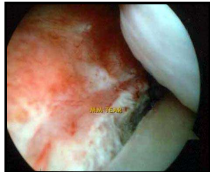
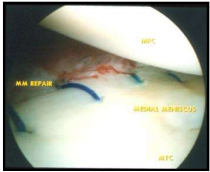
AMERICAN
ATHLETIC CONFERENCE




THE BEARCATS

9

Meniscal Repair

- Preferred treatment
- Repairs do fail

10

Meniscal Repair Options

1. Inside-out repair
2. Outside-in repair
3. Inside-in repair
 - Meniscal arrows/darts
 - FastFix








11

Meniscal Repair

Need options for failed meniscal repair and/or previous meniscectomy

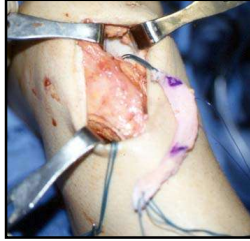




12

Meniscal Allografts

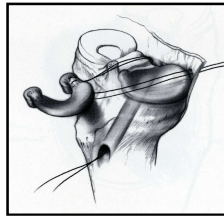
- First meniscal transplant 1984 by Milachowski (Germany)
- Multiple animal models have been evaluated



13

Goals of Meniscal Allograft

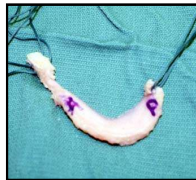- Relieve pain and swelling
- Improve secondary stability
- Prevent progression of articular lesions and arthrosis



14

Meniscal Allograft Indications


- Symptomatic meniscal deficiency
- Intact primary stability
- Acceptable alignment
- Minimal articular disease
- Age less than ~ 40



15

Contraindications

- Chronic ligamentous instability
- Arthrosis > grade III
- Advancing age
- Severe malalignment
- Arthroplasty candidates



B

Health
Orthopaedics &
Sports Medicine

AMERICAN
ATHLETIC CONFERENCE

C
BEARCATS

16

Meniscal Allograft Immunology

- “Immunologically privileged”
- Extracellular matrix
- HLA typing????
- Local rejection
- Knowledge limited



Health
Orthopaedics &
Sports Medicine


AMERICAN
ATHLETIC CONFERENCE

C
BEARCATS

17

Graft Preservation

- Fresh
 - Most immunogenic, difficult logistics
- Fresh frozen
 - Reduced antigenicity
- Freeze dried (lyophilization)
 - Shrinkage reported
- Cryopreserved
- Cell viability
 - Host cells rapidly repopulate the transplanted cells in all types



Health
Orthopaedics &
Sports Medicine


AMERICAN
ATHLETIC CONFERENCE

C
BEARCATS

18

Graft Sizing

- Essential for incorporation and restoration of function
- Ideally within 5% of anatomic
- Utilizes plain radiographs, MRI and CT scanning
- Lack of standardized sizing protocol



Health Orthopaedics & Sports Medicine

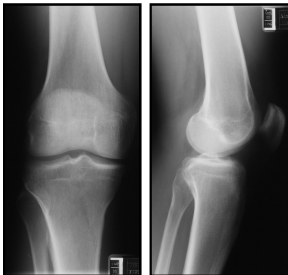
AMERICAN
ATHLETIC CONFERENCE

THE
REARCATS

19

Meniscal Allograft

- Patient evaluation:
 - Plain radiographs
 - Alignment
 - Stability
 - MRI vs. staging arthroscopy



Health Orthopaedics & Sports Medicine

AMERICAN
ATHLETIC CONFERENCE

THE
REARCATS

20

Surgical Technique

Health Orthopaedics & Sports Medicine


AMERICAN
ATHLETIC CONFERENCE

THE
REARCATS

21

Surgical Techniques

1. Bone Plug techniques
 - Medial meniscal allograft
 - Double bone plug
 - Single bone plug
2. Keyhole technique
 - Lateral meniscal allograft
3. Non-bone plug techniques




Health Orthopaedics & Sports Medicine
AMERICAN ATHLETIC CONFERENCE
 BEARCATS

22

Surgical Techniques

- Keys to success:
 1. Bed preparation
 2. Appropriate sizing
 3. Anatomic placement
 4. Secure fixation
 5. Joint stability
 6. Normal alignment

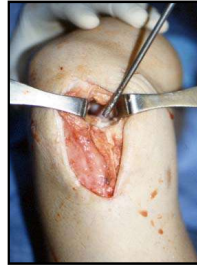


Health Orthopaedics & Sports Medicine
AMERICAN ATHLETIC CONFERENCE
 BEARCATS

23

Surgical Technique

- Arthroscopically assisted
- Medial or lateral arthrotomy
- Concomitant ligament reconstruction
- Osteotomy



Health Orthopaedics & Sports Medicine
AMERICAN ATHLETIC CONFERENCE
 BEARCATS

24

Bone Plug Surgical Technique

- Root identification



Health Orthopaedics & Sports Medicine


AMERICAN ATHLETIC CONFERENCE

REARCATS

25

Bone Plug Surgical Technique

- Graft preparation



Health Orthopaedics & Sports Medicine

AMERICAN ATHLETIC CONFERENCE

REARCATS

26

Bone Plug Surgical Technique

- Graft passage



Health Orthopaedics & Sports Medicine

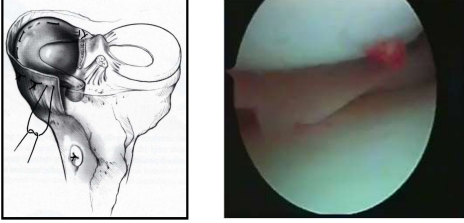
AMERICAN ATHLETIC CONFERENCE

REARCATS


27

Bone Plug Surgical Technique

- Final placement and graft fixation

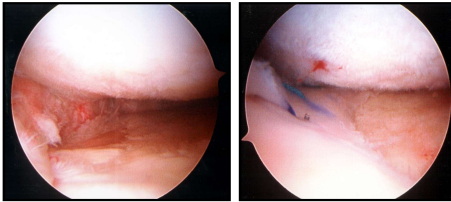


The slide features two images: on the left, a black and white anatomical diagram of a knee joint showing the femur, tibia, and patella, with a small red dot indicating the location of the bone plug; on the right, a circular arthroscopic view showing a bone plug being positioned within the joint.




28

Bone Plug Surgical Technique




Pre-Operatively Post-Operatively

The slide shows two side-by-side arthroscopic views. The left view, labeled 'Pre-Operatively', shows the joint space before the bone plug is inserted. The right view, labeled 'Post-Operatively', shows the bone plug successfully placed and fixed within the joint.



29

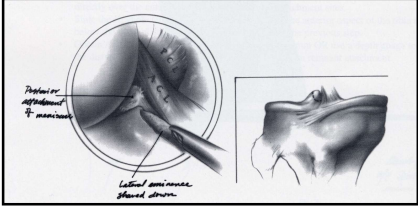
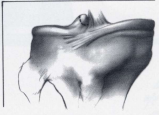
Keyhole Surgical Technique




30

Keyhole Surgical Technique

- Bed preparation
- Take down of tibial eminence


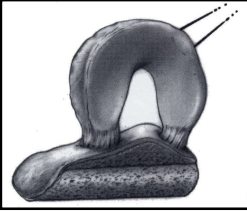




Health Orthopaedics & Sports Medicine
AMERICAN
ATHLETIC CONFERENCE


31

Keyhole Surgical Technique

- Graft preparation


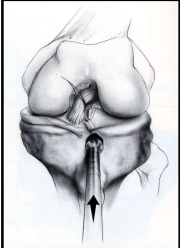




Health Orthopaedics & Sports Medicine
AMERICAN
ATHLETIC CONFERENCE


32

Keyhole Surgical Technique

- Tunnel drilling


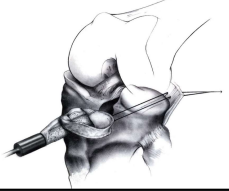






Health Orthopaedics & Sports Medicine
AMERICAN
ATHLETIC CONFERENCE


33

Keyhole Surgical Technique

- Passing of completed graft

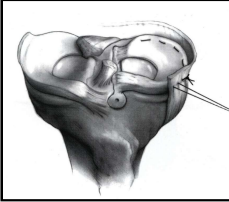











34

Keyhole Surgical Technique

- Securing the graft

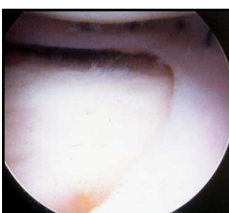
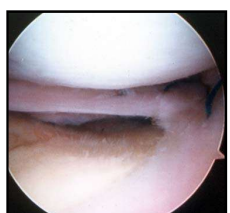










35

Keyhole Surgical Technique

Final allograft placement

36

Keyhole Surgical Technique




- Second look arthroscopy at 12 months



37


Rehabilitation




  

38

Rehabilitation

- Lack of standardized protocol
- Concomitant surgery
- Protective WB for 6 weeks
- Early limitations in flexion
- Return to activity at 3-6 months
- Full return at 6-9 months



39

Clinical Case #1

- Case: M.H. 26 y.o. male soccer player
- ~ 2 years S/P MM with MJLT and swelling



Health
Orthopaedics &
Sports Medicine


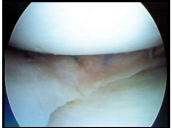
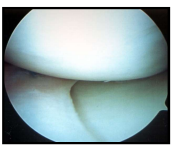
AMERICAN
ATHLETIC CONFERENCE

C
BEARCATS

40

Clinical Case #1

- M.H. Medial meniscal allograft placed February, 2000

Health
Orthopaedics &
Sports Medicine

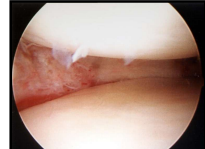
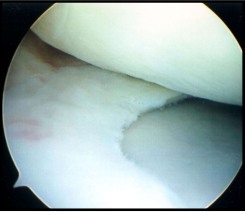
AMERICAN
ATHLETIC CONFERENCE

C
BEARCATS

41

Clinical Case #1

- M.H. second look arthroscopy at 6 months

Health
Orthopaedics &
Sports Medicine

AMERICAN
ATHLETIC CONFERENCE

C
BEARCATS

42

Mechanism of Allograft Failure

- Technical failures:
 - Loss of fixation
 - Lack of bone plug incorporation
 - Poor graft placement
 - Size mismatch
- Biologic failures:
 - Absence of peripheral healing
 - Absence of re-vascularization
 - Lack of chondrocyte viability
 - Graft shrinkage











46

Future Directions

- Develop accepted standards for:
 - Patient and graft selection
 - Indications for surgery
 - Graft selection and sizing
 - Further immunologic studies
 - Rehabilitation protocol
 - Long term follow-up
 - Bioengineered/Synthetic



47

Summary

- Vital role of meniscus
- Meniscal allograft transplantation remains investigational
- Allograft reconstruction is technically feasible
- Long term success unknown







48

What's new and upcoming?

49

Meniscal Scaffolds

- Indications
 - Intact meniscal rim
 - Stable anterior and posterior meniscal horns
 - Well-aligned knee with minimal cartilage damage

50




Meniscal Scaffolds

- Synthetic – Polyurethane
 - Acellular
 - Degrades over 5 year period
- Collagen Meniscal Implant
 - Type 1 collagen – bovine achilles
- Limited studies and RCTs
 - Patients report decrease in pain and increase in function
 - Relatively high failure rate
 - Meniscal extrusion seen on MRI
 - Questionable cartilage preservation

51

Future Advances

- Meniscal regeneration
 - Scaffolds with biomaterials/stem cells
- 3D printing
- Cellular vs. Acellular scaffolds
- Tissue engineering
 - Meniscal cells, chondrocytes, stem cells, etc
 - Repair of avascular meniscus?

52

Thank You!

53
