



High Energy Injuries around the Knee: Ext Fix and Soft-Tissue Managment

 *T. Toan Le MD*
Dep. of Orthopaedics - UC
Trauma 101
Clearwater FL 2019 

1

Outline

- Goals of “Early” Fracture Stabilization
- Advantages of Spanning External Fixators
- Case Examples



2

Spectrum of Injury



Osteous injury is an imperfect the soft tissue injury

3

High Energy Periarticular Fxs

Osseous Injury	Soft Tissue Injury
➤ Static	➤ Dynamic
➤ Easily assessed	➤ Accumulative
➤ Easily Quantified	➤ Difficult to assess

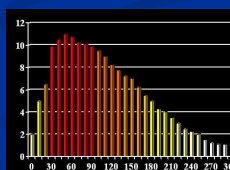
Complications and Prognosis
Both are significantly altered by treatment

4

Soft Tissue Response to Injury

➤ **Inflammatory Phase**
Platelets, Neutrophils and Macrophages

- ❖ Release cytokines
- ❖ Worsening tissue hypoxia
- ❖ Perpetuates inflammatory response
- ❖ Progressive acidosis
- ❖ Vicious cycle of progressive tissue injury



5

Goals of Fracture Fixation

- Stabilize fractures w minimal complications
- Provisional & definitive fixations - same goal
- Definitive fixation & ETC - harmful
- Spanning external fix is ideal for soft tissue management & *complex periarticular fractures & patients in extremis*

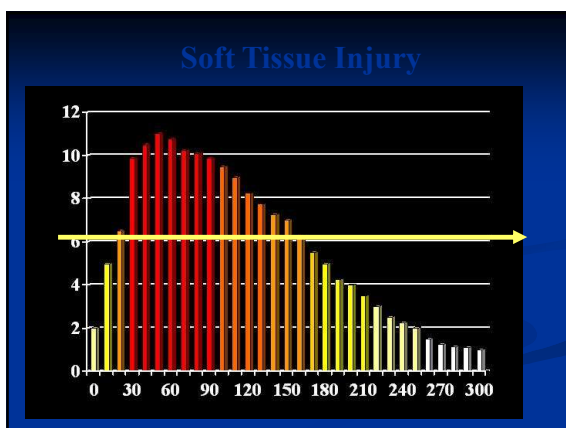
6

Importance of Early Fracture Stabilization

- Integral part of resuscitation process
- Mobilization – nursing care
- Pulmonary function
- Pain management
- Soft-tissue management
- Improves patient survival & outcome



7

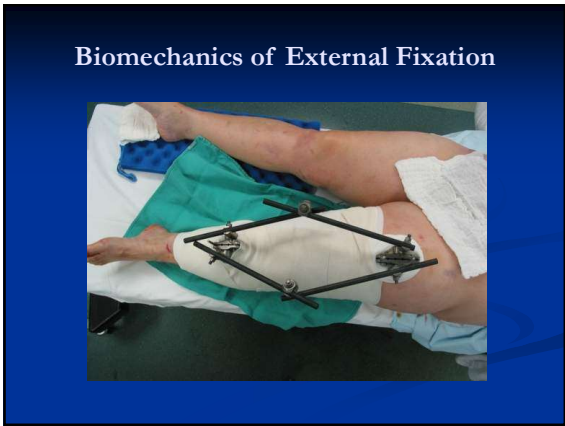

8

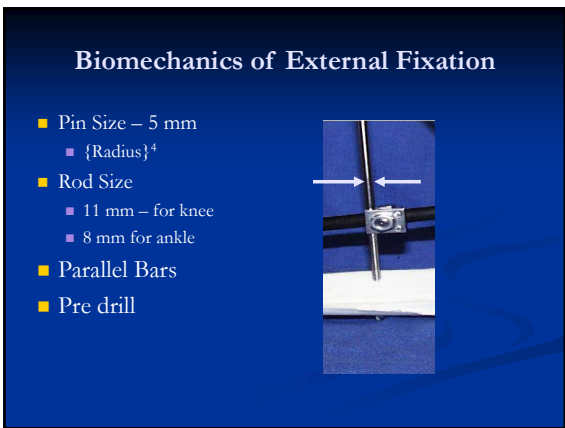
When to use it?

- Complex periarticular injuries
- Soft-tissue injuries – Grade 3B, crush injuries, swelling & compartment syndrome
- Speed is an issue – vascular injury or patient in extremis
- Logistics of definitive fixation are suboptimal

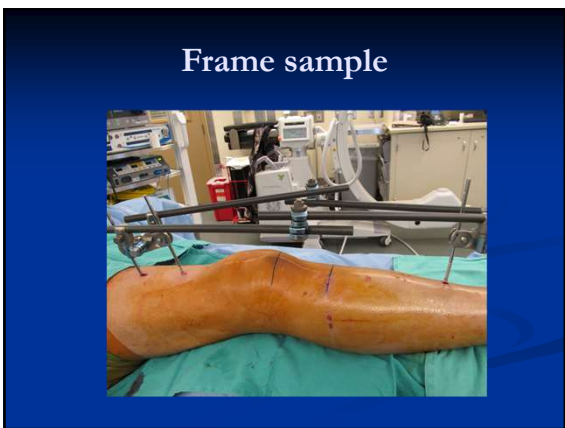
9



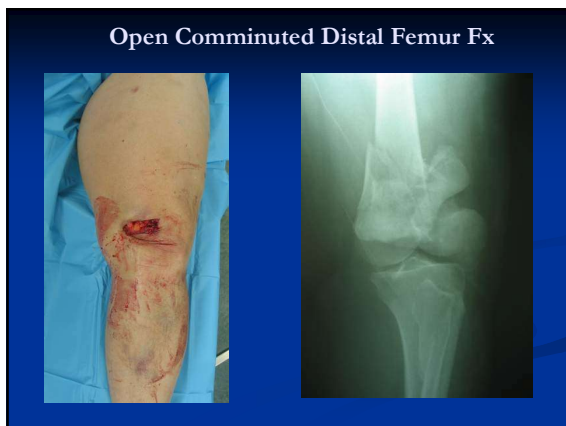10



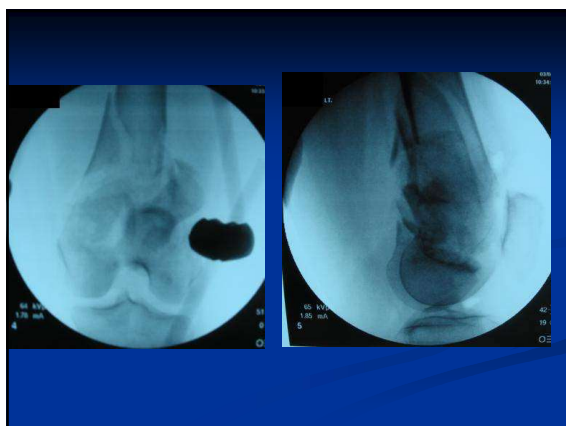
11



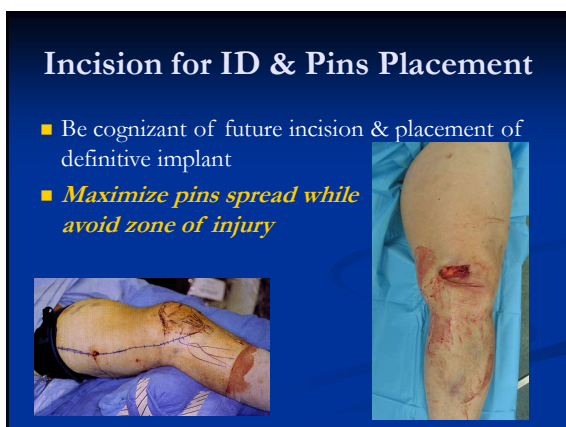12



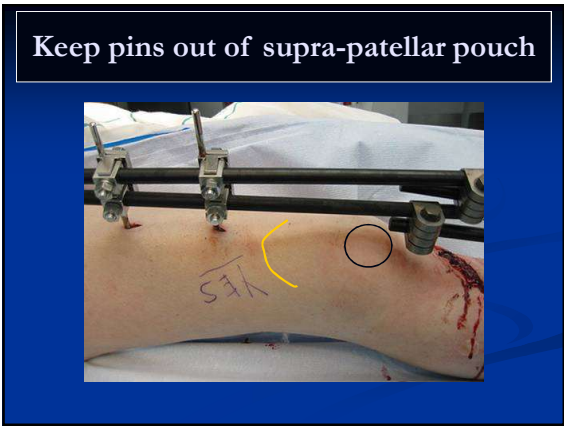
13



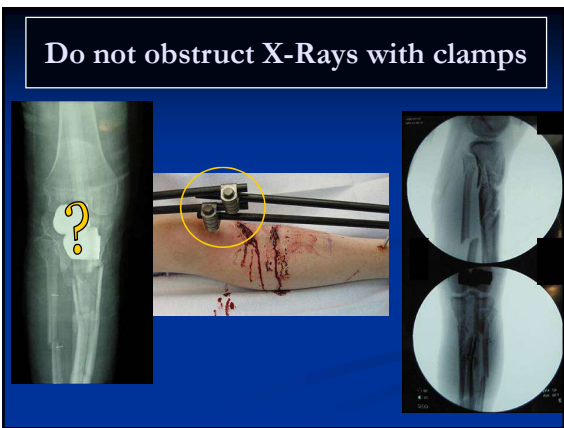
14



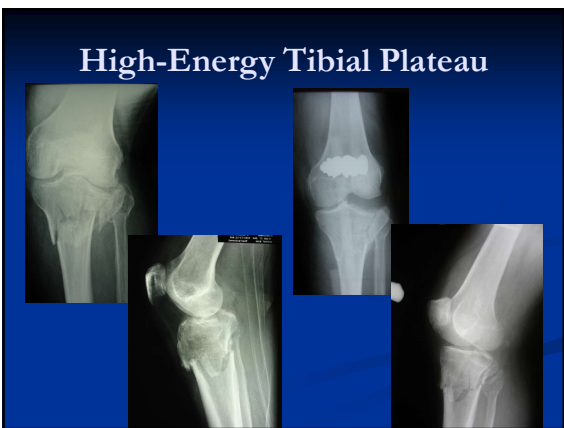
15



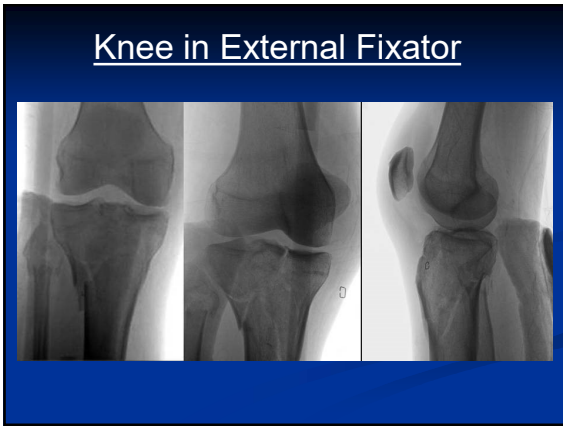
16



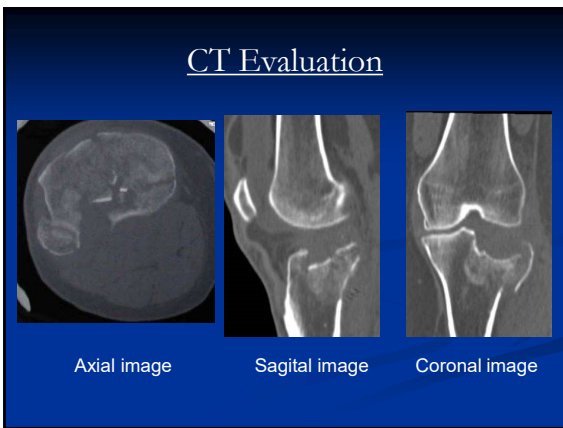
17



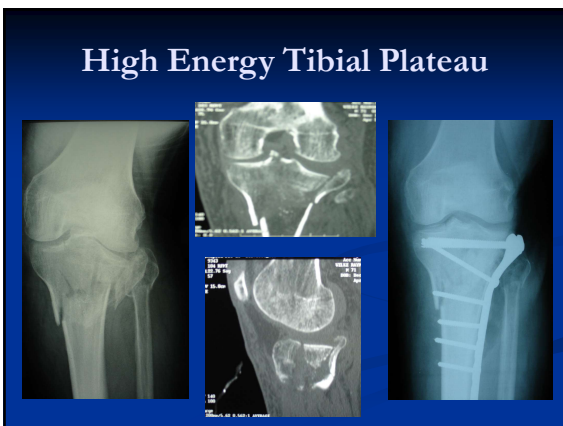
18



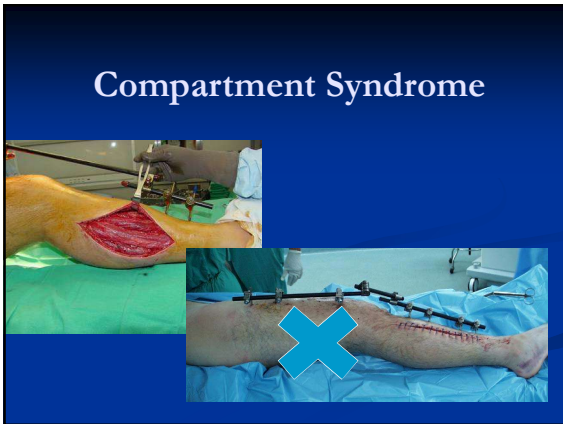19



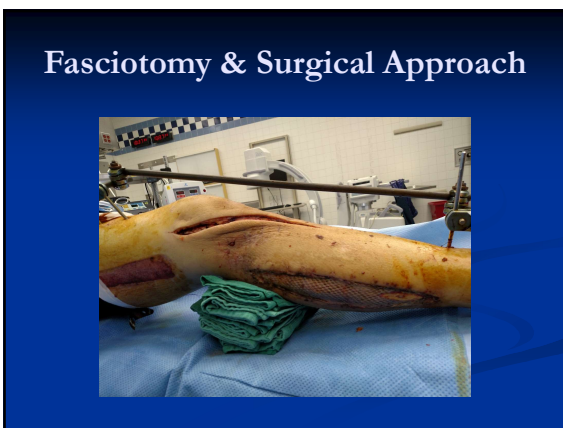20



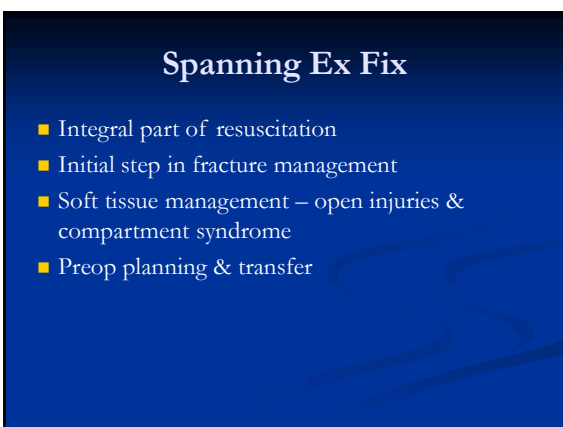21



22



23



24



25
