


Institute for Orthopaedics and Sports Medicine



MIS Forefoot Surgery: Have I Lost My Mind?

Craig S. Radnay, M.D., M.P.H.
(Fellow 2005-06)

Insall Scott Kelly® Institute
for Orthopaedics & Sports Medicine
NYU-Hospital for Joint Diseases
October 27, 2018



A Leap Of Faith



My Real Disclaimer:

These Have Not Been My Favorite Cases

- Demanding patients
- ?Reasonable expectations
 - Pain, swelling, function, motion
- Cosmetic demands
- Shoewear demands
- Extensive follow up




“Sneaker-Wearing Christian Louboutin Says Women Should Suffer for Beauty” People Magazine



Technical Goals

- Goals:
 - Correct HVA/IMA
 - Create congruent 1st MTP joint with sesamoid realignment
 - Remove medial eminence
 - Retain functional 1st MTP ROM
 - Maintain normal WB mechanics



ISK
Insall Scott Kelly

Clinical Goals

- Functional, painless 1st MTPJ
- Restore normal alignment
- Ability to wear shoes of choice

ISK
Insall Scott Kelly

The Reality: Surgical Treatment

- Earliest reports of HV correction Gernet 1836
- >150 open techniques described
- 15% of postop patients have complications
 - Pain
 - Stiffness
 - Malunion
 - Delayed wound healing
 - Infection
 - Slow recovery

Schuh et al, Intl Orth 2013; Lehman, Ft Ankle Clin 2003

ISK
Insall Scott Kelly

Minimal Incision Surgery (MIS)

- Adoption in orthopedics and all surgical specialties
- Knee, shoulder, hip
- GU
- GI
- Less operative trauma
- Preserve blood supply of healing soft tissues



Why Minimally Invasive Foot Surgery?

- Patients desire
 - Smaller incisions
 - Faster recovery
- Allows for a reduction in costs due to
 - Faster procedures
 - Fewer wound complications
 - Fewer infections



MIS Global Movement





- MIS Foot and Ankle started in 1945
- Morton Polokoff DPM
 - Subdermal Surgery, chisels, rasps, spears
- Leonard Britton—perc metatarsal osteotomies
- 1990s: Stephen Isham DPM popularized many procedures: Reverdin modification
- Broadened indications in Europe in 2000s
- Spanish/French adopters → GRECMIP (2002)

Group of Research and Study in Mini-Invasive Surgery of the Foot and Ankle



Evolution of MIS Hallux Valgus Correction (MICA)

- 1st generation
 - Closing wedge, no fixation (*Isham, 1980s*)
- 2nd generation (SERI, *Bosch, Hohmann*)
 - Distal transverse 1st MT osteotomy, axial K wire
 - Hardware left temporarily spanning joint
- 3rd generation (MICA)
 - Combine percutaneous Chevron/Akin osteotomies with **rigid internal screw fixation**
 - *Vernois and Redfern, 2011*




Today's MIS Foot Surgery

- **New technology to fit classic techniques**
- Same open procedures performed percutaneously
- Reduces incision size
 - Reduces soft tissue trauma
- **'Extra articular' philosophy** allowing joints of foot to maintain maximum flexibility and ROM
- Use of burs instead of saws for osteotomies
- 9 Years of clinical history



Today's MIS Foot Surgery

- Increased patient satisfaction
- Increased ROM
- Earlier Return to Function
- Less stiffness
- Less post op pain
- Less blood loss
- Less infection



Open procedures performed percutaneously

1. Chevron Osteotomy
2. Akin Osteotomy
3. DMMO/Bunionette
4. Cheilectomy
5. MDCO



ISK
Insall Scott Kelly

What is MIS Foot Surgery?

Open MIS

Bunion

Akin



ISK
Insall Scott Kelly

What is MIS Foot Surgery?

Open MIS

Cheilectomy

MDCO/Calc Osteotomy



ISK
Insall Scott Kelly


To Start, Consider The Following Patients:

1. Diabetic
2. Smoker
3. Patients with history of wound healing problems or previous surgeries.
4. Patients with collagen disorders
5. History of keloid scarring

ISK
Insall Scott Kelly

MICA: Surgical Technique


- Assess deformity on preop XR
- What will it take to normalize the M1:M2 intermetatarsal angle?
 - Check displacement distance needed to correct the IM angle (a)
 - Check diameter of 1st metatarsal at proposed osteotomy site (b)
 - If $a/b \leq 1$, MICA can correct deformity




Redfern, Vernois, Tech FA Surg 2015

ISK
Insall Scott Kelly


MICA: Percutaneous Burr Equipment




Burrs
Optimized for foot pathologies



Power
Low Speed Machine with Irrigation
Optimized for Foot and Ankle Procedures



MIS tools
Rasps, Elevators
Designed specifically for foot surgery



Pencil Driver
High torque for quick osteotomies

ISK
Insall Scott Kelly

MICA: Percutaneous Burr Equipment




- Precise pencil driver burr
- High Torque
- Low Speed (<6,000 RPM)
- Saline irrigation *always* used
- Difficult to cut soft tissue with burr


ISK
Insall Scott Kelly

Equipment for MIS in the Foot Burrs

'Shannon'
2mm x 8mm/12mm/20mm burr – straight cutting



'Wedge'
3.1mm / 4.1 x 12mm burr – reaming / shaving



Refern et al, 2011

ISK
Insall Scott Kelly

MICA: Surgical Technique


- Chevron-shaped 1st MT osteotomy
- Akin-type osteotomy P1 hallux
- Percutaneous with burr
- Image guidance
- Rigid internal fixation with screws

Redfern et al, Clin Pod Med Surg 2015

ISK
Insall Scott Kelly

MICA: Surgical Technique


- Position supine
- Foot overhanging bed
- Mini C arm to right (if right handed)
- Burr equipment to the left
- Scrub table distal
- +/- tourniquet
 - ? Cooling effect from blood flow



ISK
Insall Scott Kelly

MICA: Surgical Technique



- Outline the dorsal, plantar MT borders
- Stab incision at osteotomy site
 - Flare of 1st MT distal neck/metaphysis
 - Avoid 1st DMCN
- Elevator to create working space dorsal, free lateral periosteum



ISK
Insall Scott Kelly

MICA: Surgical Technique


- Burr to create osteotomy
 - 2 mm diameter, leaves cut of 2-2.5 mm
 - 10° distal, 15° plantar, depending
 - Reload the 1st MT
- CHECK before penetrate lateral cortex
 - This step dictates the whole plane of osteotomy
- If burr is perpendicular to axis of 2nd MT, then head is displaced distally 3mm during translation



ISK
Insall Scott Kelly

MICA: Surgical Technique

- Complete Chevron osteotomy
 - Angle subtended by 2 limbs is $\sim 130^\circ$
 - Dorsal limb perpendicular to 1st MT
 - Plantar limb parallel to floor
 - Lift hand dorsal toward 1st MTP



ISK
Insall Scott Kelly



MICA Surgical Technique

- Dominant hand holds burr and touches the foot for balance
- Other hand “feels” burr thru skin as guide

ISK
Insall Scott Kelly

MICA: Surgical Technique


- 2 guidewires from medial base 1st TMT
 - Larger wire mid-axis through lateral wall of proximal 1st MT, 1 cm proximal to osteotomy
 - 2nd wire slightly more distal, lateral
- Wires should not block head translation



ISK
Insall Scott Kelly

MICA: Surgical Technique

- Curved elevator through osteotomy site into proximal 1st MT canal
- Control displacement lateral, distal, plantar
- Lever 1st MT head laterally
 - With heel of nondominant hand
 - Dominant hand holds head and slight dorsal force to avoid malrotation
 - Slight varus rotation force to hallux
 - Correct pronation



ISK
Insall Scott Kelly

MICA: Surgical Technique


- Guidewires advanced across osteotomy into head fragment
 - 3-point fixation
 - Check in AP, lateral, oblique planes



ISK
Insall Scott Kelly

MICA: Surgical Technique

- 2 cannulated compression screws
 - Provide rotational, dorsal/plantar stability
 - Chamfered head sits flush to bone
 - Avoid prominence, need for HWR
 - Fully threaded, compression
 - Increased head length optimizes cortical contact



ISK
Insall Scott Kelly

MICA: Surgical Technique
?Distal Lateral Soft Tissue Release


- Facilitate lateral displacement of MT head
- Help correct sesamoid subluxation
- Help correct hallux valgus angle
- Allow derotation of a mildly pronated great toe
- Allow correction of more severe deformity
- With MICA translation up to 100%, adductor hallucis is relaxed so lateral soft tissue release only required if hallux not clinically reducible

Steinbock et al, J Ft Ankle Surg 2003; Bai et al, FAI 2010

ISK
Insall Scott Kelly

MICA: Surgical Technique
Distal Lateral Soft Tissue Release

- Perform *after* Chevron cut and stabilization
- Percutaneous
- Medial to EHL
- Dorsolateral corner 1st MTPJ



ISK
Insall Scott Kelly


MICA: Surgical Technique
Distal Lateral Soft Tissue Release

- Bring toe into varus
- Divide lateral sesamoid-phalangeal ligament (lateral head FHB distal to lateral sesamoid)
- Divide lateral plantar plate

ISK
Insall Scott Kelly

MICA: Surgical Technique
Akin osteotomy

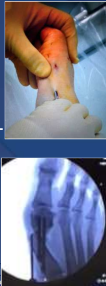
- Mid-axial
- 2 x 12mm Shannon burr
- Check angle
- Sweep dorsal, plantar
- Closing wedge, rotation
- Leave lateral hinge
- 2.5 headless compression screw fixation from medial base phalanx



ISK
Insall Scott Kelly

MICA: Surgical Technique

- Shave overhanging bone
 - 12 x 3.1 mm wedge burr
 - Through one of portals
 - Redundant shoulder of proximal 1st MT
 - Plantar to dorsal
 - Median eminence
 - Plantar to dorsal, inside out



ISK
Insall Scott Kelly

Remove Overhanging Bone



ISK
Insall Scott Kelly

MICA: Surgical Technique

- ***Irrigate all portals copiously
 - Express bony debris
 - Can irritate joint, cause stiffness, wound-healing issues
- Portal closures



ISK
Insall Scott Kelly

MICA: Surgical Technique

- Saline-soaked bunion gauze dressings

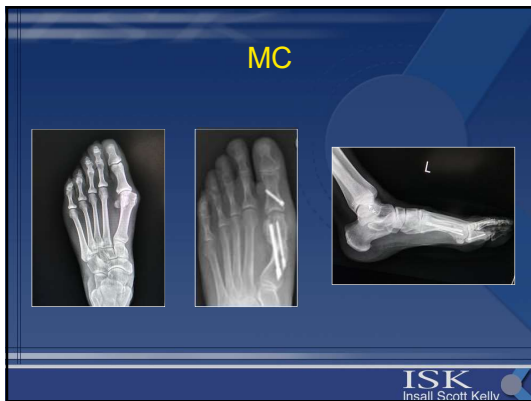

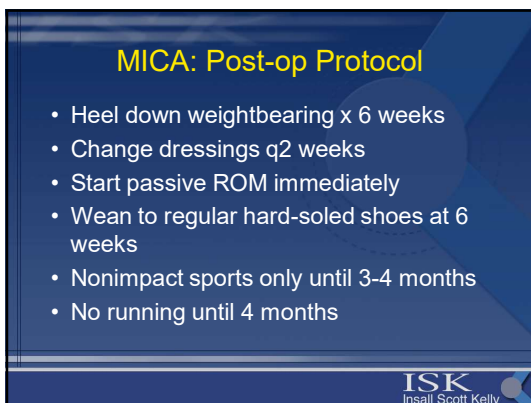
ISK
Insall Scott Kelly

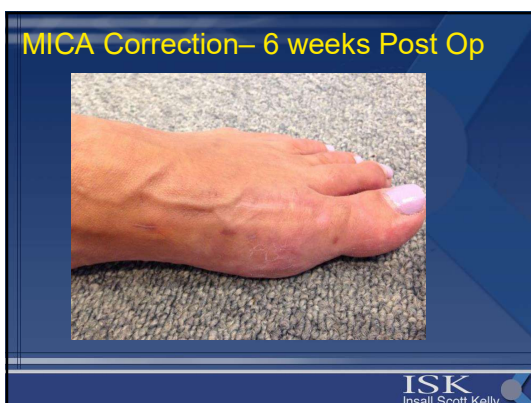PA



ISK
Insall Scott Kelly







MICA Risks

- No direct visualization of different tissue layers
- Need appropriate placement of osteotomy
 - Avoid shortening, elevation
- Essential use of intra-op flouroscopy
- Stable and reliable fixation requires screw fixation and use of 3-point fixation for proximal screw

ISK
Insall Scott Kelly

MICA risks

- Potential skin burring from burr
 - 0-13% (*Darcel et al, Mono AFCP 2009; De Prado et al, Rev Esp Cir Orto Traum 2003*)
- Minimal risk to tendon
- Minimal risk to medial sensory cutaneous branch superficial peroneal nerve

Dhukaram et al, FAI 2012

ISK
Insall Scott Kelly

MICA Risks


- Minimal risk to vascular supply
 - MICA is an extracapsular approach
 - Blood supply MT head preserved, ↓AVN
- No greater incidence injury to nerve, blood vessels, tendon (*Dhukaram et al, FAI 2012*)

ISK
Insall Scott Kelly

MICA Clinical Benefits


- Less pain, stiffness
- Shorter operative times
- Less blood loss than open
- Minimal neurovascular risks
- Decreased risk of infection
- Decreased risk overcorrection because no medial soft tissue tightening

Lam et al, Ft Ank Clin NA, 2016




MICA Clinical Results
Percutaneous Surgery is Complicated and Has a Learning Curve

- *Kadakia et al, FAI 2007 (SERI)*
 - Prospective study, short-term outcomes
 - Unacceptable complication rate
 - Dorsal malunion (69%), Osteonecrosis, Wound complications, Recurrence (38%)
 - Superficial infection, delayed union, overcorrection of deformity, stiffness
 - Stopped study prematurely




MICA Clinical Results
Percutaneous Surgery is Complicated and Has a Learning Curve

- *Bauer et al, Ortho Traum Surg Res 2010*
 - Reverdin-Isham, shortened 1st MT, increased risk 1st MTPJ incongruency, limit IM<15°
- *Biz et al, J Orth Surg Res 2016*
 - Limit IM<15°
- *Lucas y Hernandez et al, Bone Jt J 2016*
 - MICA, screw removal, fixation failures





MICA Clinical Results

- *Vernois, Redfern, Fuss Sprung 2013*
 - Up to 3 yr f/u, 96% G/E satisfaction
 - HVA:33°→7°; IMA 14.5°→5.5°
 - No major complications, no nonunions/AVN
- *Brogan et al, FAI 2016*
 - Retrospective, 2 yr f/u,
 - Comparable clinical/XR outcomes to open
 - The swath from the burr in a closed procedure aids radiographically earlier union



MICA Clinical Results

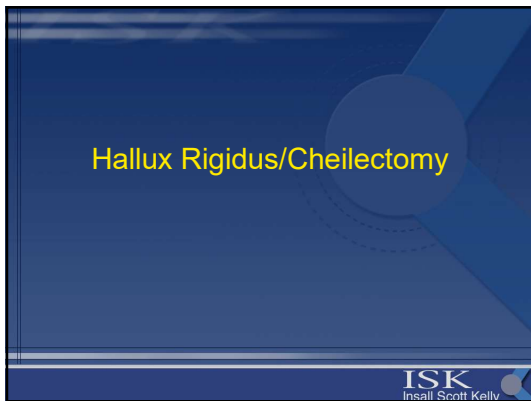
- *Lam et al, Ft Ank Clin NA 2016*
 - Similar HVA/IMA correction, complications
 - Shorter operative times, improved cosmesis
higher level patient satisfaction
- *Lee et al, FAI 2017, prospective*
 - Similar clinical, XR outcomes
 - Significantly lower pain levels to 6 weeks,
scar length, greater high satisfaction rate

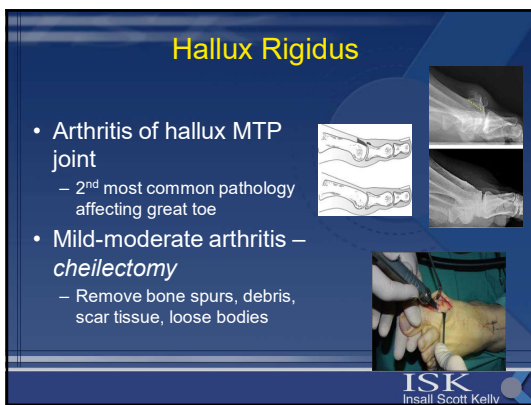


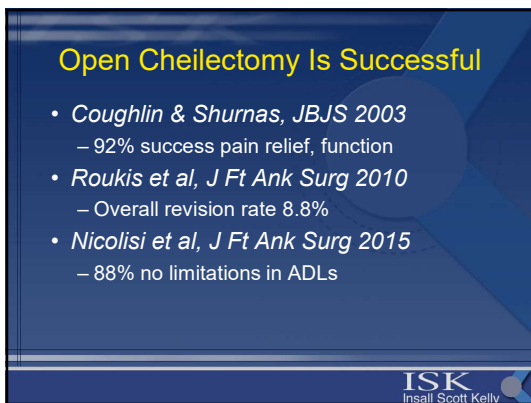
MICA Clinical Results

- *Lai et al, FAI 2018*
 - Perc Chevron/Akin vs open Scarf
 - Comparable clinical and radiologic outcomes at 24 mo f/u
 - Perc group significantly
 - Less periop pain
 - Shorter length of operation
 - Decreased risk wound complications











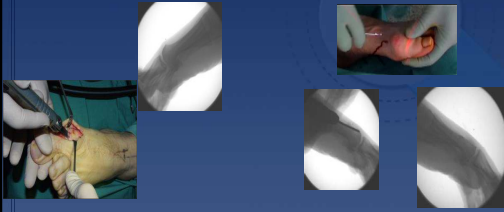
MIS Cheilectomy

- Less operative morbidity
- Small incisions minimize soft tissue disruption
- Better cosmesis
- Shorter recovery period
- Comparable successful outcomes to open




MIS Cheilectomy

Traditional Cheilectomy *MIS Cheilectomy*




MIS Cheilectomy

- Heel off bed
- +/- tourniquet
- Mini C arm
- Mark out the nerve prior to incision
 - Danger zone at 1/3 the length of 1st MT from MTPJ (Teoh et al, FAI 2018)
 - Portal just plantar to nerve




Teoh et al. FAI 2018



MIS Cheilectomy


- Stab incision dorsomedial 1st MT
- Proximal to medial eminence
 - 2.5 cm proximal to 1st MTPJ
 - Allow access to DM and lateral lying osteophyte AND avoid DMCN



ISK
Insall Scott Kelly

MIS Cheilectomy

- Periosteal elevator to lift capsule from MT head
 - Create a working space for the burr to access the osteophytes
 - Protect the tendon
 - Protect the nerve (DMCN)



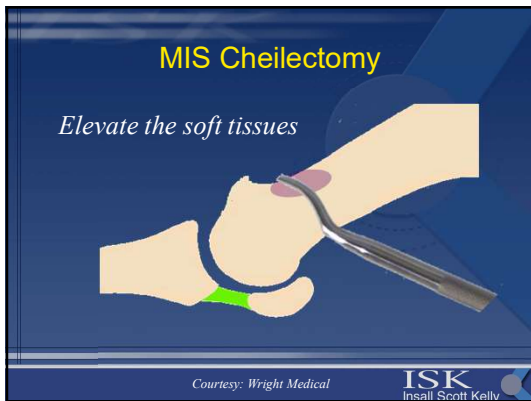Teoh et al, FAI 2018

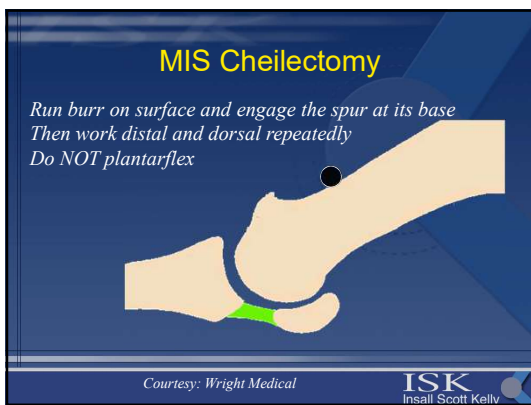
ISK
Insall Scott Kelly

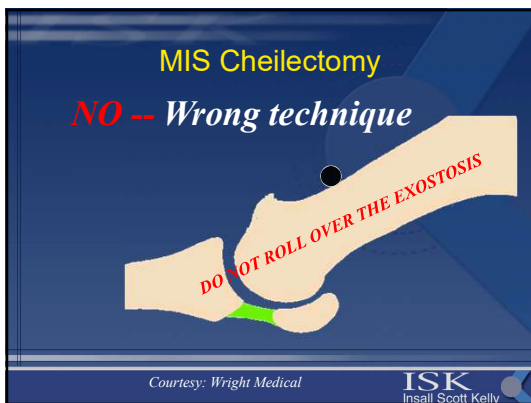MIS Cheilectomy

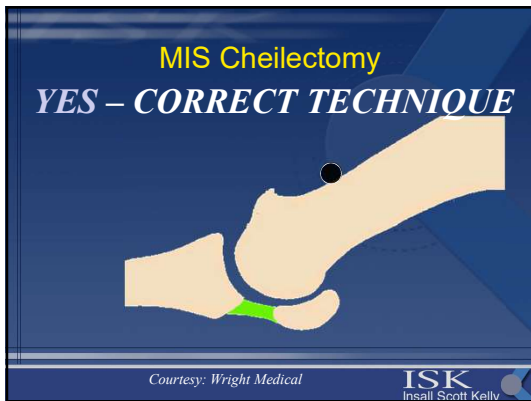
- Use 3.1 mm wedge burr
 - Set to high torque low speed (80Ncm, <300 rpm)
 - Sweep proximal to distal, lateral to medial
- Remove up to dorsal 1/3 MT head
- Start proximal, inferior
- Confirm with mini C

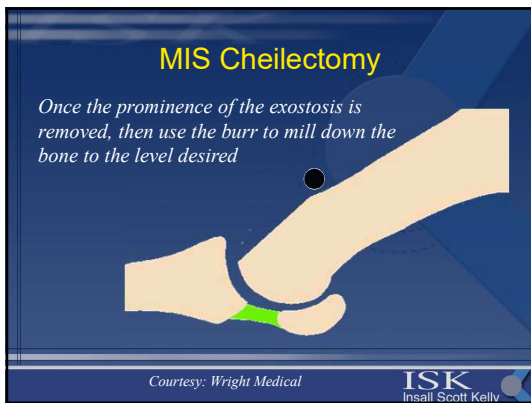
ISK
Insall Scott Kelly

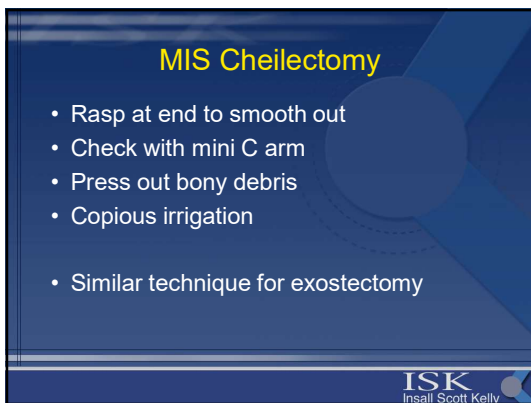












MIS Cheilectomy

- If remove P1 osteophytes, advance burr distal
- Sometimes need dorsolateral portal for lateral MT/P1 osteophytes
 - Lateral to EHL
 - Elevator to make working space
- ?arthroscopy

ISK
Insall Scott Kelly

MIS Cheilectomy: Clinical Results

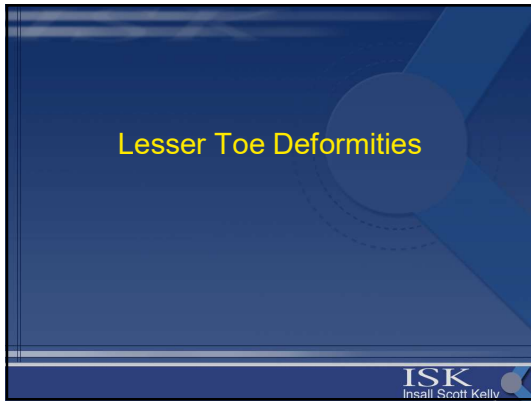
- *Morgan et al, Orth Proc 2018*
 - Comparable results, lower failure rate
- *Redfern et al, Clin Pod Med Surg 2015*
 - Improved cosmesis
 - Improved pain control
 - 86% return to regular footwear, normal daily activity/employment within one week

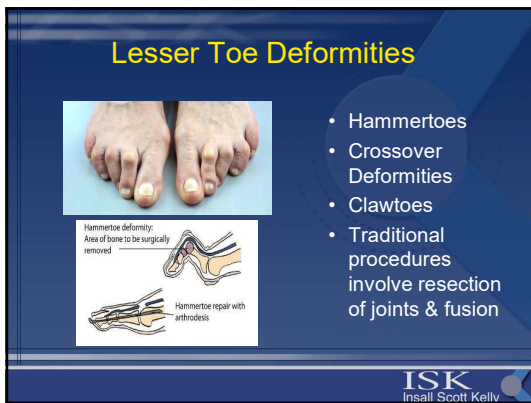ISK
Insall Scott Kelly

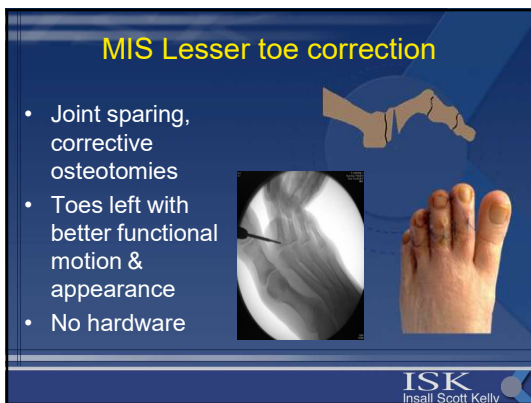
MIS Cheilectomy: Clinical Results

- *Teoh et al, FAI 2018*
 - Improved clinical outcomes, PROM
 - 4% nerve issues (2 neuropraxia, 2 permanent)
 - Learning curve, 42% of re-ops 2° technical
 - Incomplete cheilectomy
 - Loose bone
 - Best for Grade 1 (10% Grade 2-3 → fusion)

ISK
Insall Scott Kelly








MIS Lesser Toe Correction

- Soft Tissue Procedures
 - Flexor tenotomies (FDB or FDL)
 - Extensor tenotomies (EDL, EDB)
 - Joint release (MTP, PIP)
- Bone Procedures
 - Extra-articular (phalangeal osteotomy P1, P2)
 - Intra-articular (condylectomy, fusion PIP, DIP)

Redfern et al, Clin Pod Med Surg 2015



Hammer Toe

Severity

Flexible or Rigid


+/- metatarsalgia

Subluxation/dislocation @ MTPJ


Varus / Valgus malalignment




Soft Tissues: Extensor Tenotomy



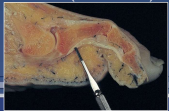
- Proximally EDB and EDL can be separated
- MTPJ level if capsular release necessary
 - Only with MTPJ dislocation
- Plantar flex, but usually well-visualized



Soft Tissues: FDL & FDB Tenotomy




- Plantar incision at base of toe allows FDL and FDB section
- Division completed by simultaneous dorsiflexion of toe
- I prefer selective tenotomy otherwise toe does not contact floor
 - Neurologic deformities (Parkinson's)




ISK
Insall Scott Kelly

Soft Tissues : Selective FDB tenotomy

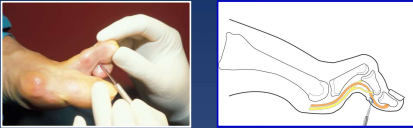


Difficult to be selective with plantar approach
Mid-axial incision, advance through PIPJ capsule at P2
Release FDB heads off plantar surface middle phalanx
Elevator and then hyper dorsiflex the PIPJ



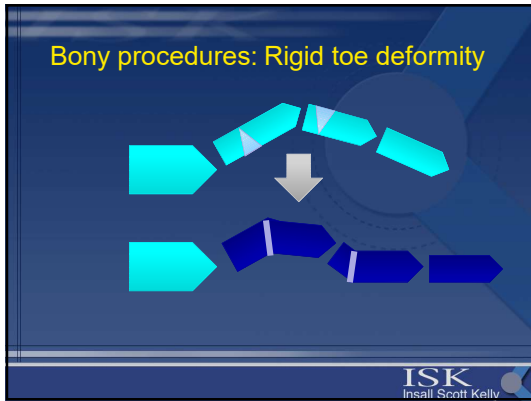
ISK
Insall Scott Kelly

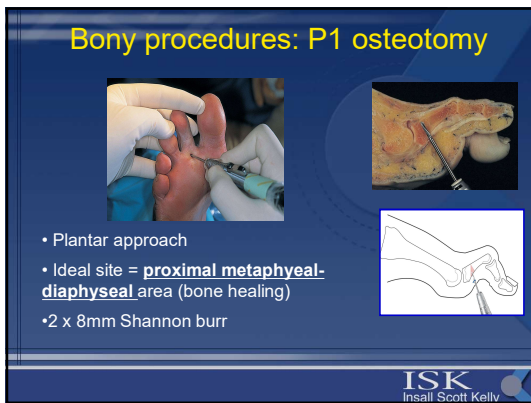
Soft tissues : FDL tenotomy

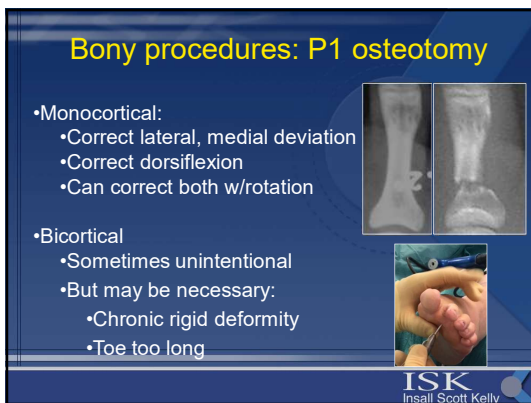


Plantar distal incision at the level of DIP joint
Dorsiflex DIPJ and tenotomize

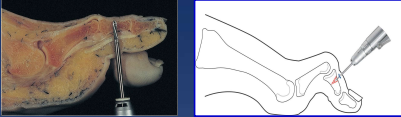
ISK
Insall Scott Kelly







Bony procedures: P2 osteotomy



- Lateral or medial mid-axial approach depending on
 - Dominant hand of the surgeon
 - Operated foot
 - Desired procedure
- **Mid-diaphyseal** to avoid articular damage
- Monocortical or bicortical

ISK
Insall Scott Kelly

Bony procedures: P2 osteotomy



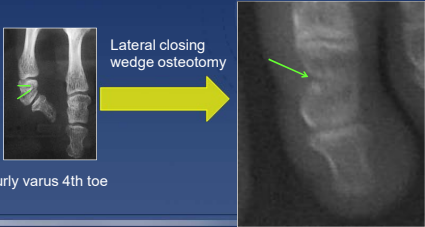
P2 osteotomy sometimes useful as complementary procedure when PIPJ deformity correction is not achieved

8 days

ISK
Insall Scott Kelly

Bony Procedures: Clinodactyly

MONOCORTICAL OSTEOTOMY: Clinodactyly correction



Curly varus 4th toe

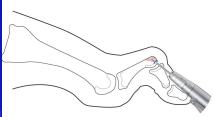
Lateral closing wedge osteotomy

ISK
Insall Scott Kelly

Bony procedures: Condylectomy

P1 dorsal head burring +/- P2 base

- Can add to correction of a severe stiff hammertoe in addition to P1, P2 osteotomies
- Need to irrigate copiously!
- Bone fragments better eliminated without tourniquet
- Remaining bone risk of inflammation (fluoro++)

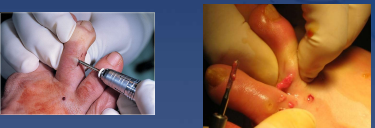


ISK
Insall Scott Kelly

Bony procedures: Condylectomy

P1 dorsal head burring +/- P2 base


- Approach: lateral or medial distal dorsal P1
- Work from dorsal base P2 proximal, toe in flexion
• (Redfern et al, Clin Pod Med Surg 2015)



ISK
Insall Scott Kelly

Hammer Toe Correction

- Flexible or rigid?
- Assess at each joint (MTP, PIP, DIP)
 - Sagittal plane (flexion, extension) deformity
 - Transverse plane (varus, valgus) deformity
 - With PIP flexed, check DIP, MTP



ISK
Insall Scott Kelly


Hammer Toe Correction

GO TO PROCEDURES

- PIPJ plantar release + selective FDB tenotomy
- P1 Osteotomy (plantar closing wedge)

ASSOCIATED PROCEDURES
(depending on deformity)

- Extensor tenotomies (if rigid deformity)
- Dorsal MP capsular release
- P2 Osteotomy (esp with rigid deformity)
- Condyloplasty





ISK
Insall Scott Kelly

Metatarsalgia, Bunionette

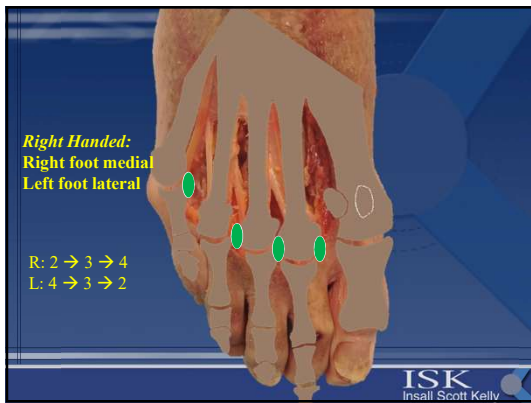

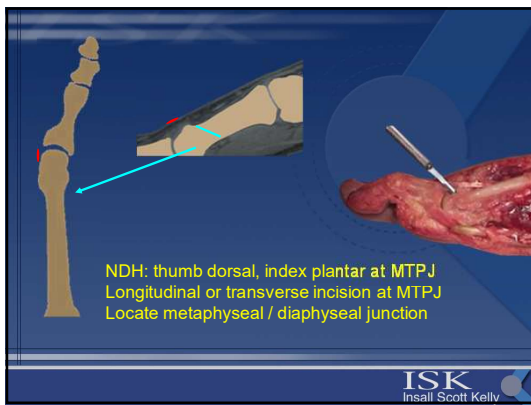
ISK
Insall Scott Kelly

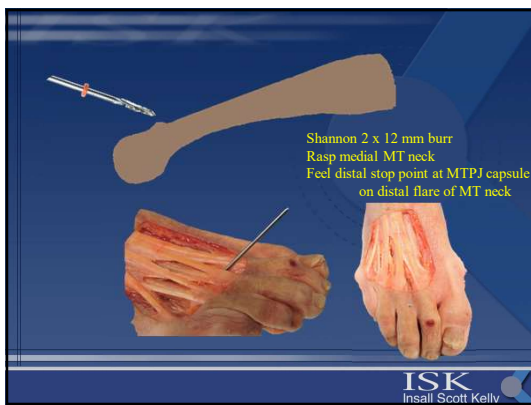MIS DMMO for Metatarsalgia, Bunionette Try and Minimize Stiffness, Floating Toe

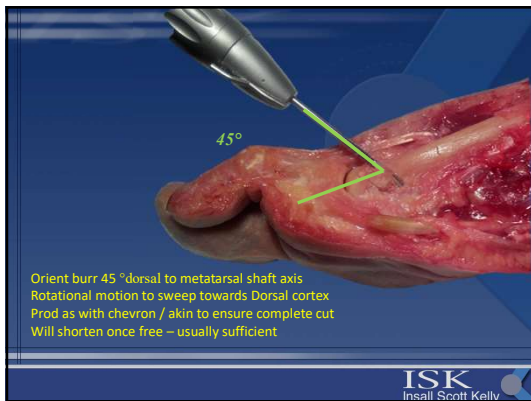
DMMO	WFII
	
<ul style="list-style-type: none">• Dynamic correction• No fixation• Shortening• Extra-articular• Percutaneous	<ul style="list-style-type: none">• Not dynamic• Fixation• Shortening• Intra-articular• Open

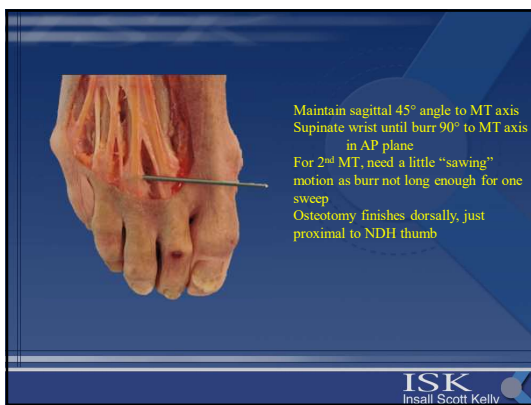
ISK
Insall Scott Kelly

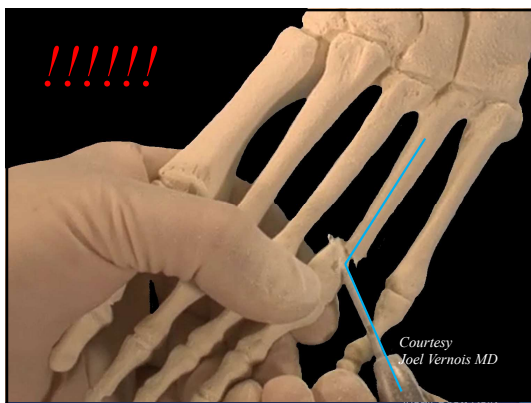


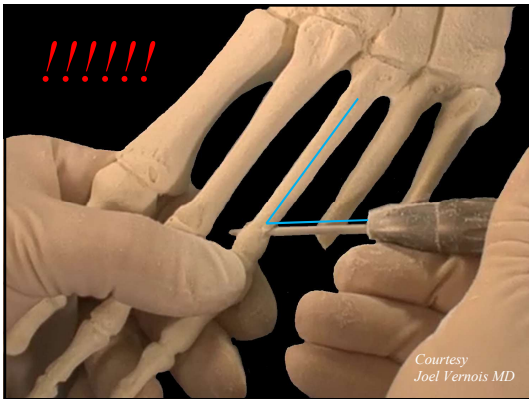


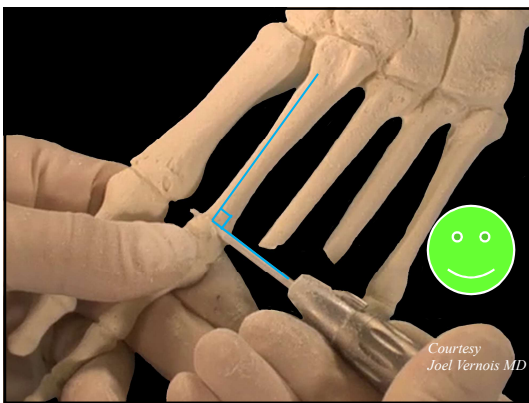


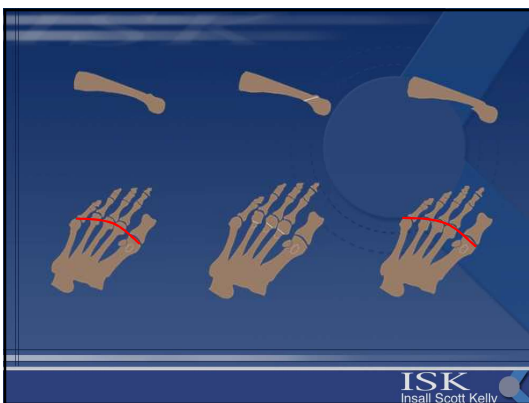













MIS DMMO for Metatarsalgia, Bunionette

- Extraarticular
- Metatarsal neck osteotomy
- No internal fixation
- Healing augmented by bone graft from burr (bony union 4-10 weeks)
- Dressing to control lateralization
- Full WB in flat shoe helps set the MT head in desired position (dynamic)

Laffontre et al, Orth Traum Surg Res 2015; Lui et al, J Ft Ank Surg 2014; Michels et al, Ft Ank Surg 2013



Isolated Metatarsalgia



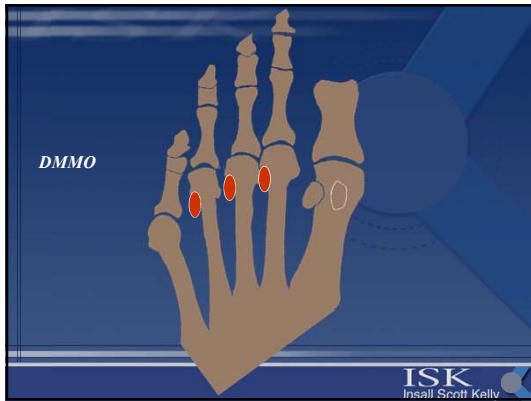ISK
Insall Scott Kelly

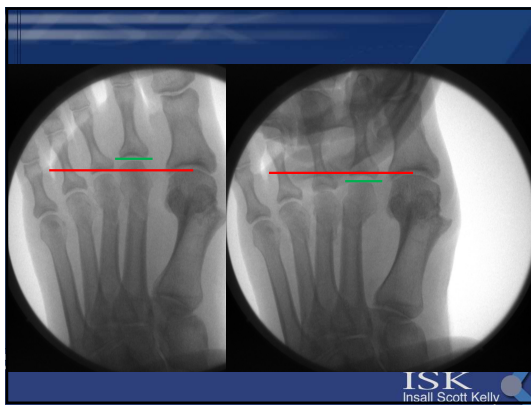

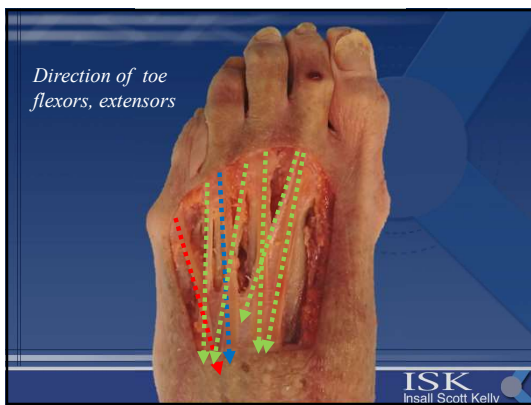
With this technique, increased risk of transfer lesions unless DMMOs done of 2,3, and 4 MT

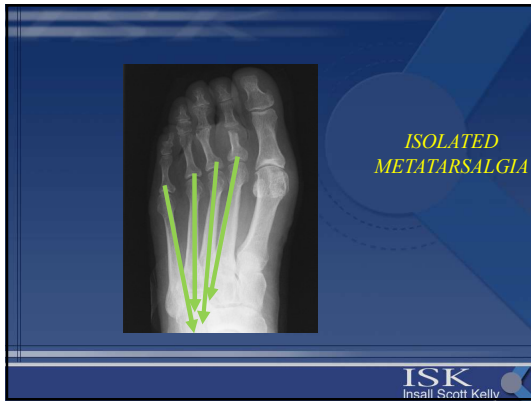Add 5th if relatively small length difference btw 4&5

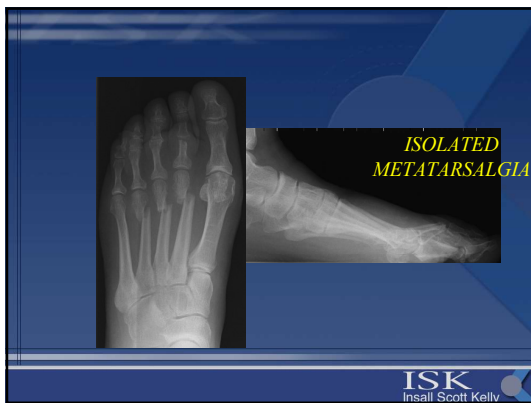ISK
Insall Scott Kelly

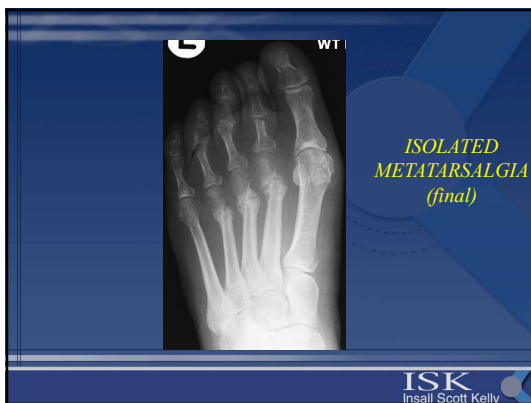


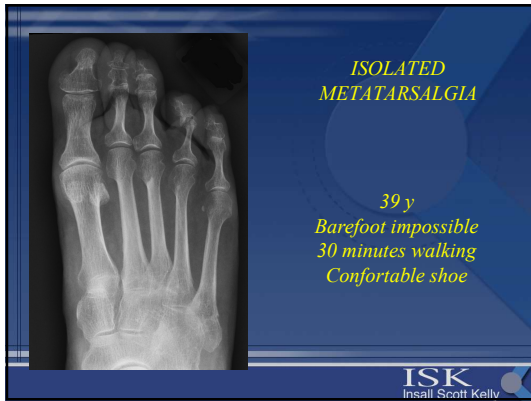
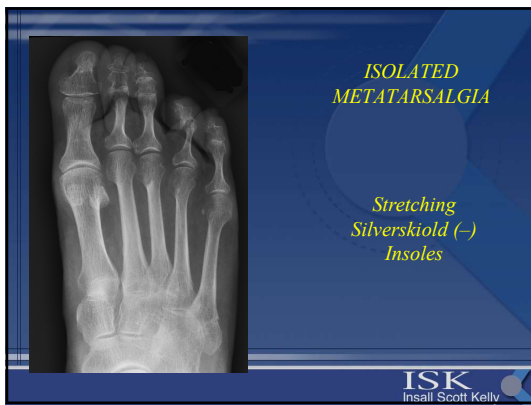




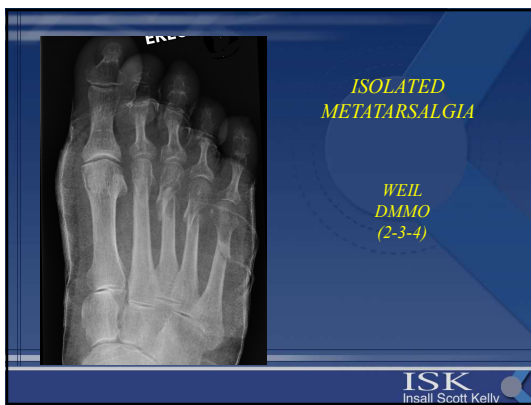

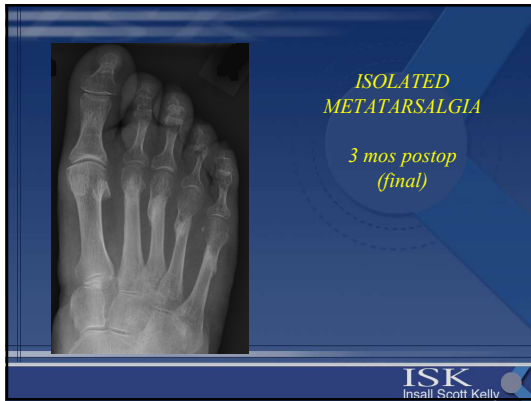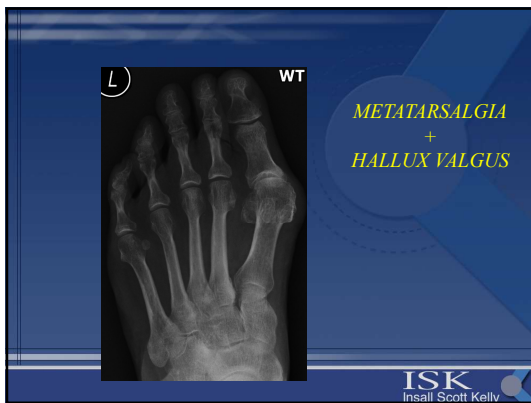






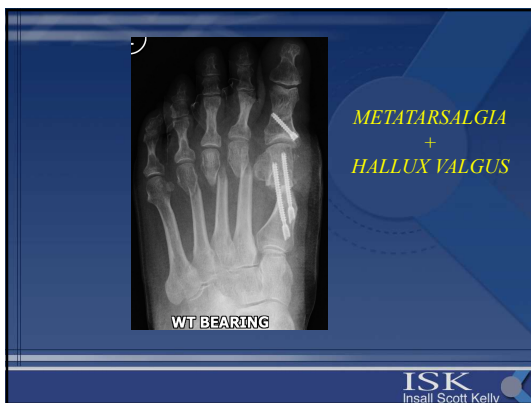


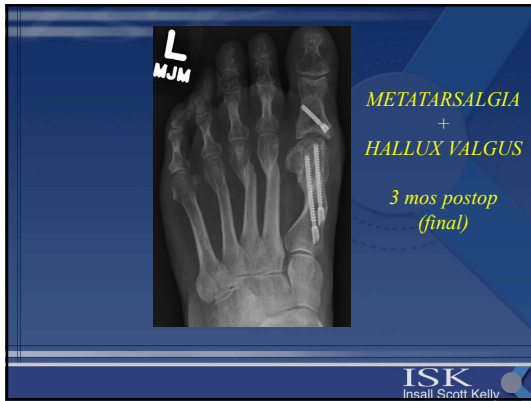


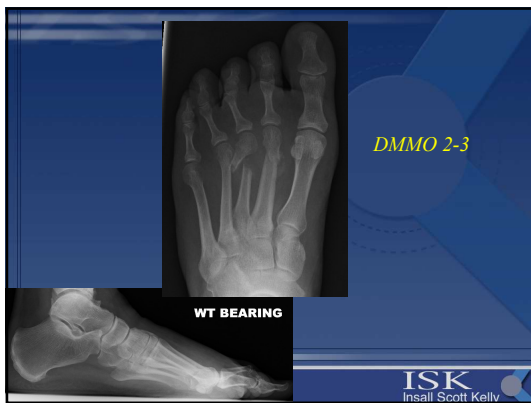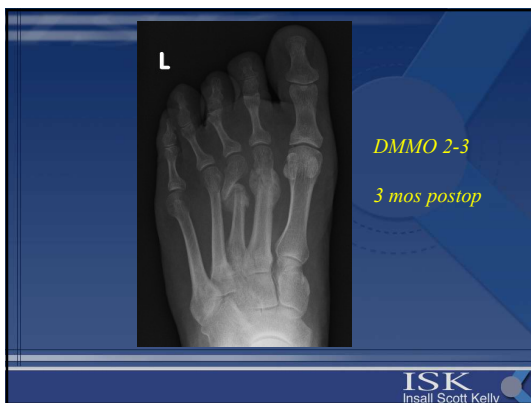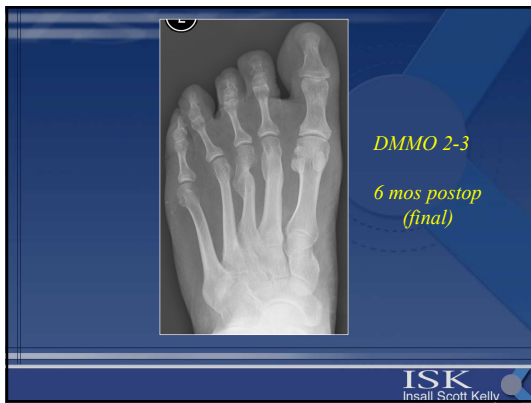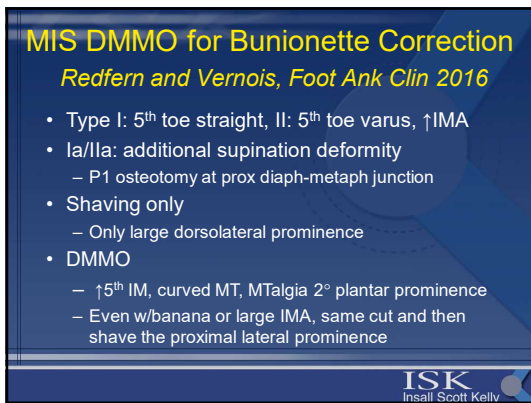


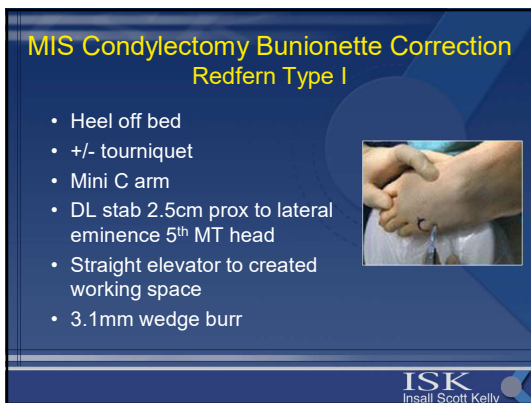













MIS DMMO for Bunionette Correction Redfern Type II

- Heel off bed
- +/- tourniquet
- Mini C arm
- Incision at 5th MT neck
- Elevator
- 2 x 12 mm Shannon burr




Teoh et al, FAJ 2018

ISK
Insall Scott Kelly

MIS DMMO for Bunionette Correction

- Origin of cut is just proximal to plantar flare of plantar condyle
- Hold at 45° in sag plane
- Make lateral indent
- Cut proximal plantar to distal dorsal
- End up 90° to shaft in coronal




Teoh et al, FAJ 2018

ISK
Insall Scott Kelly

MIS DMMO for Bunionette Correction

- No internal fixation
- FWB in flat shoe
- Slight abduction dressing
- 5th MT head will move medially due to axis of EDB acting on the 5th toe




Flouro Stress View

Teoh et al, FAJ 2018

ISK
Insall Scott Kelly

MIS DMMO for Bunionette Correction

- *Tech et al, FAI 2018*
 - Osteotomy +/- condylectomy
 - No fixation
 - Average 4 mm decrease foot width
 - Improved clinical results
 - Improved patient-reported outcomes
 - Safe, low complication rate
 - 10% symptomatic dorsal callus
 - Forefoot swelling 3-6 months



ISK
Insall Scott Kelly

General Risks of DMMO

- Persistent metatarsalgia
- Nonunion
- Malunion
- Dorsal elevation
- Floating toe
- Joint damage
- Portal skin issues



Khazen et al, Tech FA Surg 2017

ISK
Insall Scott Kelly


General Benefits of MIS DMMO

- Less stiffness ++
- Reliable healing (but may be prolonged swelling)
- Minimal pain even when delayed union
- Seems more predictable than Weil
- Less operative time

ISK
Insall Scott Kelly

Conclusions

- Hallux valgus very common pathology
 - Demanding patients
 - Set appropriate expectations
- Distal 1st MT osteotomy (Chevron) is indicated for mild-moderate hallux valgus
 - Stable osteotomy
 - Rapid bone healing



ISK
Insall Scott Kelly

Advantages of MIS Procedures

New Tools For Classic Surgical Techniques

- 3rd generation technique of percutaneous hallux valgus surgery
 - Custom MIS instruments/burr
 - Stable internal fixation
- Extracapsular procedure
 - Protects blood supply to metatarsal head
 - Decreases post-op stiffness



ISK
Insall Scott Kelly

Advantages of MIS Procedures

New Tools For Classic Surgical Techniques

- Safe and effective procedure
- Shorter operative time vs open
- Significantly ↓ post-operative pain
- Less post-operative swelling and stiffness
- Reduced wound complications/infection
- Improved cosmesis
- Quicker recovery
- Increased patient satisfaction



ISK
Insall Scott Kelly


MIS Technique Tips
There Is Definitely A Learning Curve!

- Plan out correction pre-op
- Draw out bony landmarks to help with placement of incisions/wires/screws
- Use c-arm frequently esp in beginning
- Rotate hand and pull to avoid leveraging on the skin
- Post-op dressings to help control correction

ISK
Insall Scott Kelly

Conclusions

- Surgeon experience important
 - Specific cadaveric training
 - Expand indications?
 - Severe deformity, revisions
- More high-quality prospective studies comparing open & MIS
 - Longer-term outcomes



ISK
Insall Scott Kelly

THANK YOU!!!



ISK
Insall Scott Kelly
