


TALUS FRACTURES: WHAT SHOULD I DO WITH THE BAD ONES

John Ketz, MD

Hawkins – AVN rates

- **Type I**
 - 0-13%
- **Type II**
 - 20-50%
- **Type III**
 - 75-100%


10/29/2018 2



TALAR NECK FRACTURES: RESULTS AND OUTCOMES

BY HEATHER A. VALLIER, MD, SEAN E. NORK, MD, DAVID P. BAREL, MD,
STEPHEN K. BENIRSCHKE, MD, AND BRUCE J. SANGEORZAN, MD

Investigation performed at Harborview Medical Center, Seattle, Washington



VOLUME 86-A • NUMBER 8 • AUGUST 2004

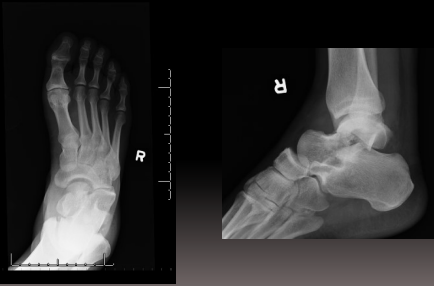
AVN (with collapse)

- **Type I-IIA**
 - 0%
- **Type IIB/III/IV**
 - 49%

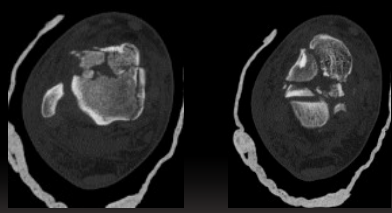
▪ **WORSE OUTCOMES WITH NECK COMMINATION AND OPEN INJURIES**

10/29/2018 4

42 yo M s/p MVC



10/29/2018 5




10/29/2018

Plate Fixation of Talar Neck Fractures: Preliminary Review of a New Technique in Twenty-three Patients

P. B. Fleuriau Chateau, *D. S. Brokaw, *B. A. Jelen, *D. K. Scheid, and *T. G. Weber


Department of Orthopaedics, Montfort Hospital, Ottawa, Canada; *Indiana University School of Medicine, and Orthopaedics Indianapolis, Methodist Hospital, Indianapolis, Indiana, U.S.A.



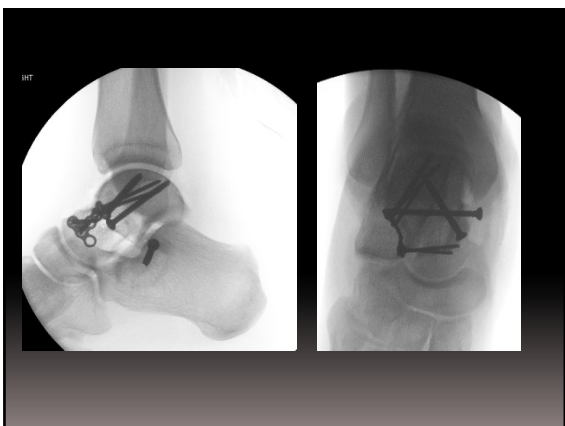
ORIGINAL ARTICLE

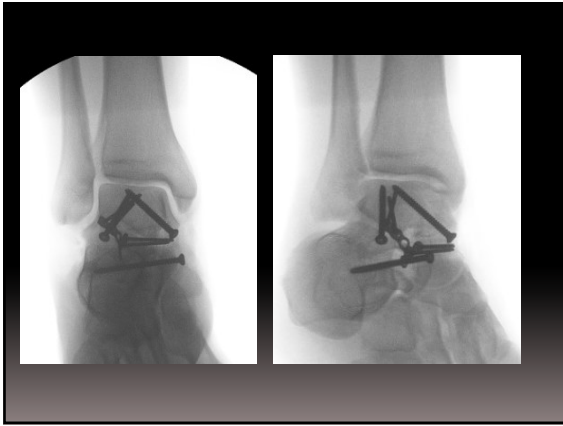
Treatment of Comminuted Talar Neck Fractures With Use of Minifragment Plating

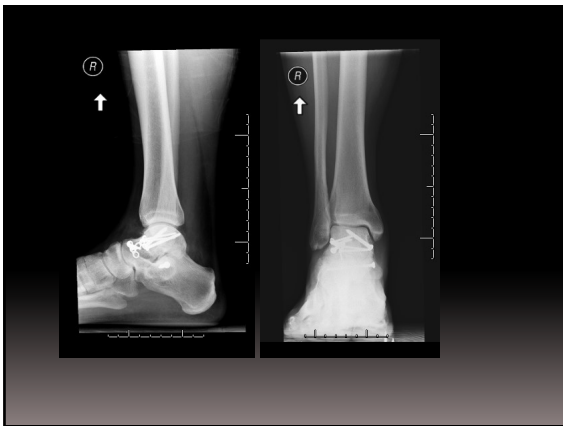Michael A. Maceroli, MD,* Christopher Wong, MD,† Roy W. Sanders, MD,‡ and John P. Ketz, MD*

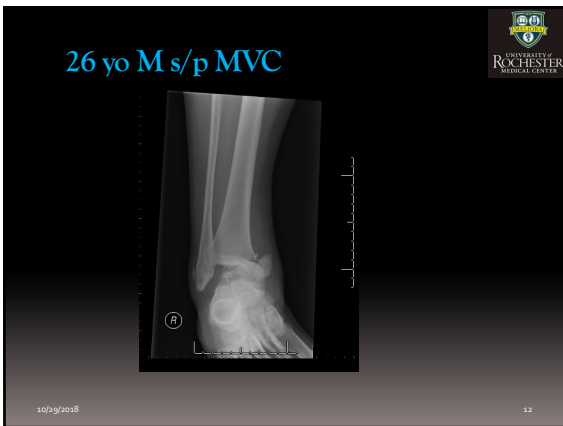


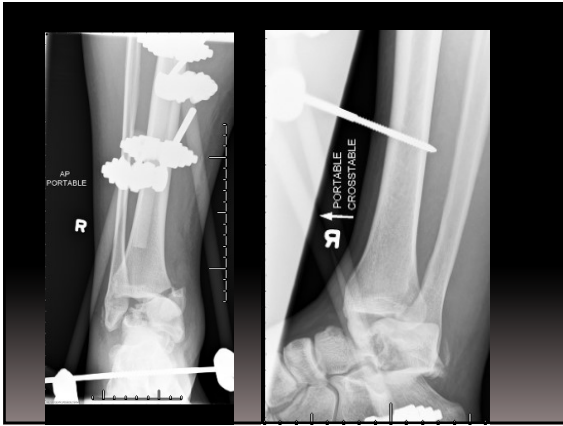
- High energy talus fractures IIB-IV
- 27% AVN with collapse

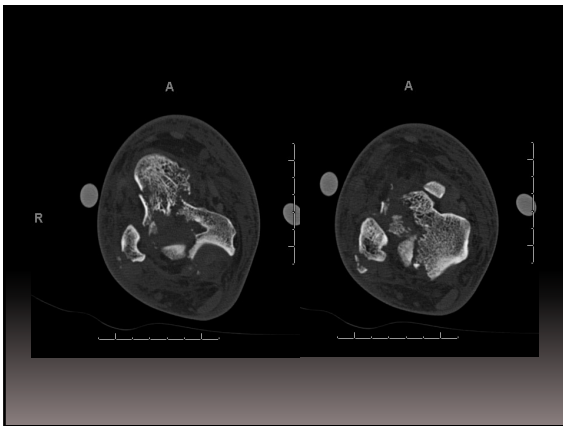


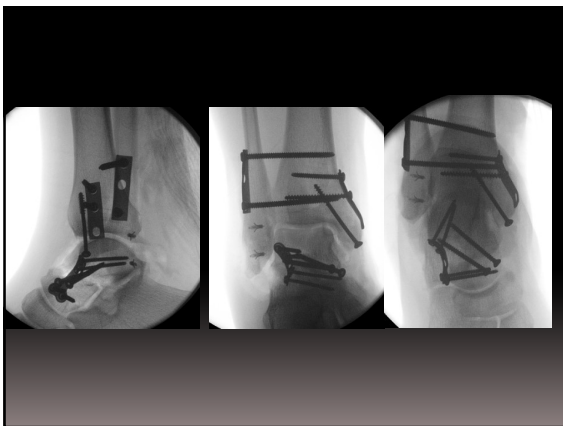

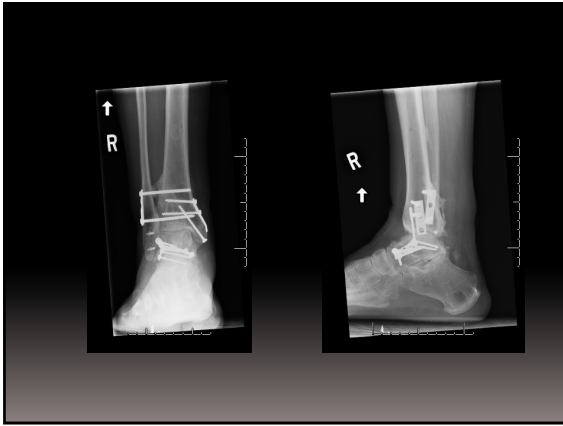


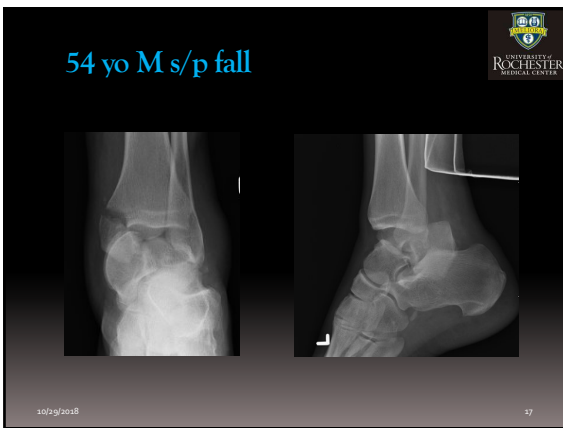



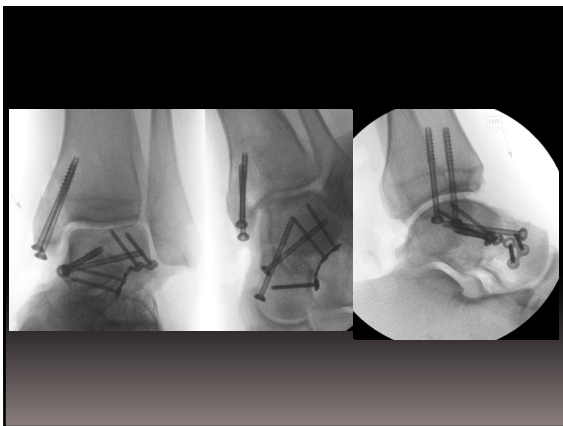


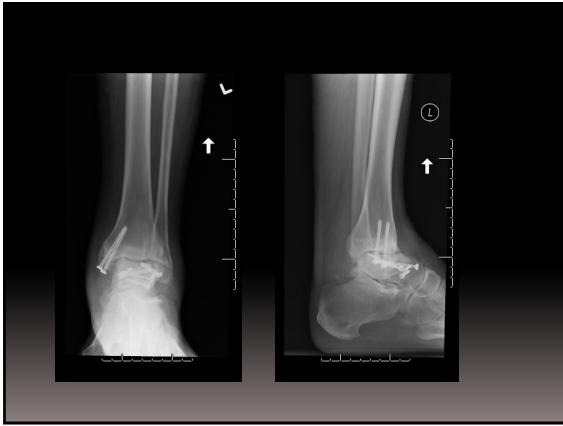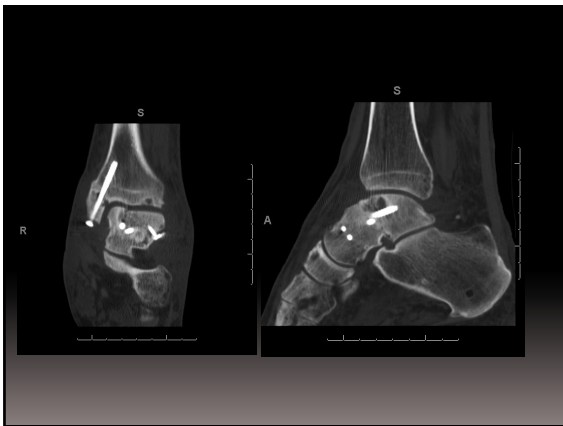


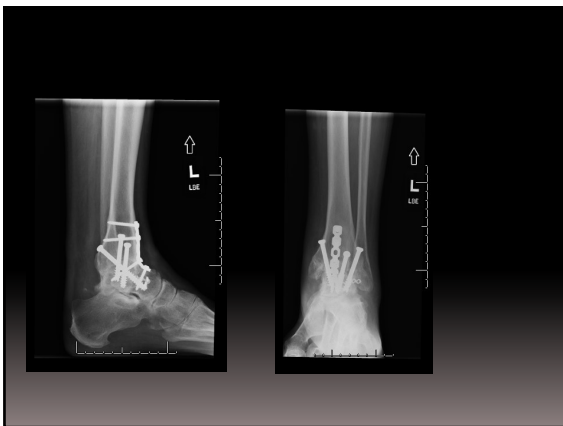





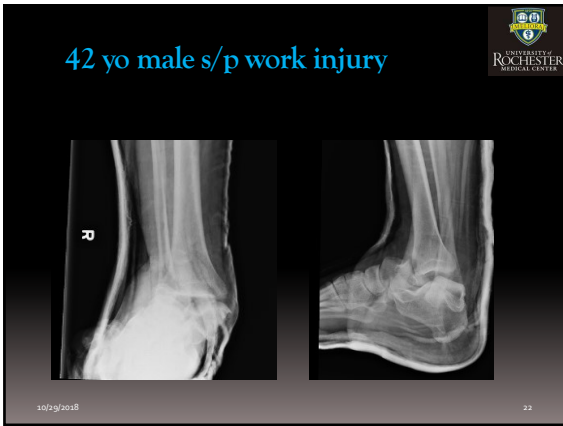
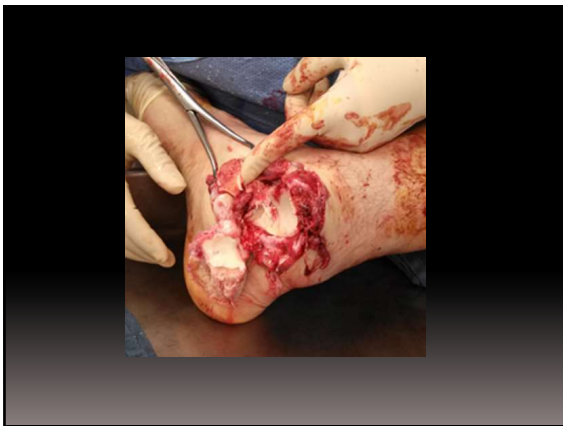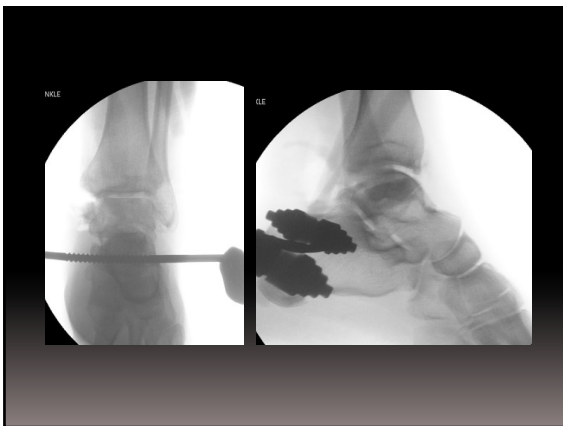


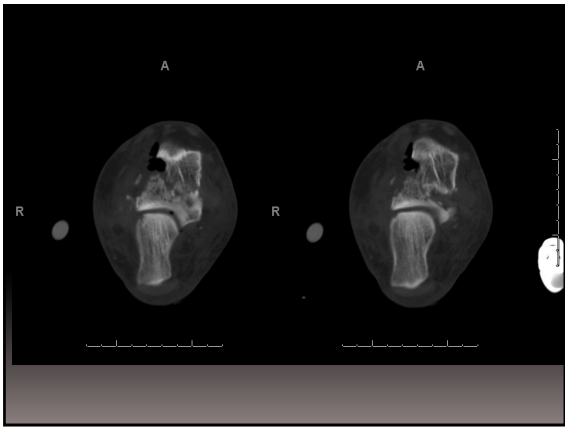


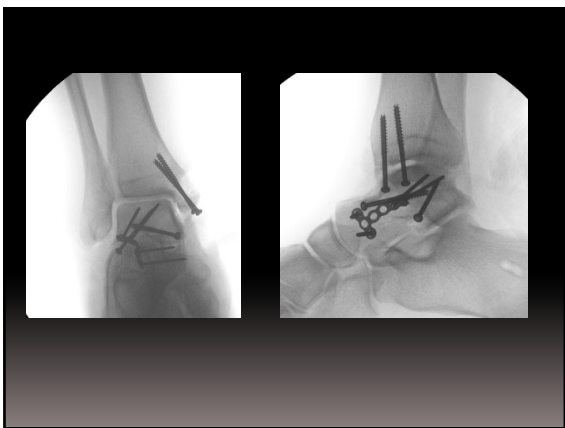







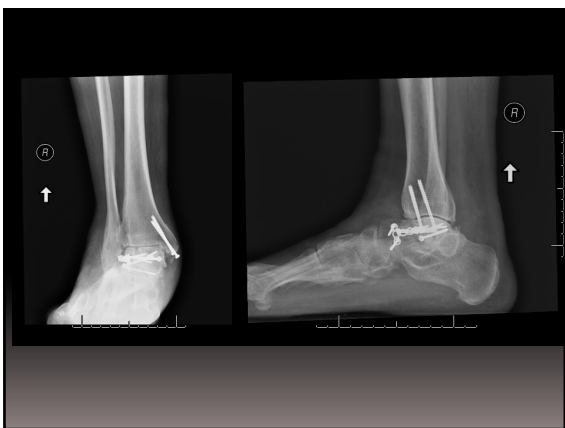
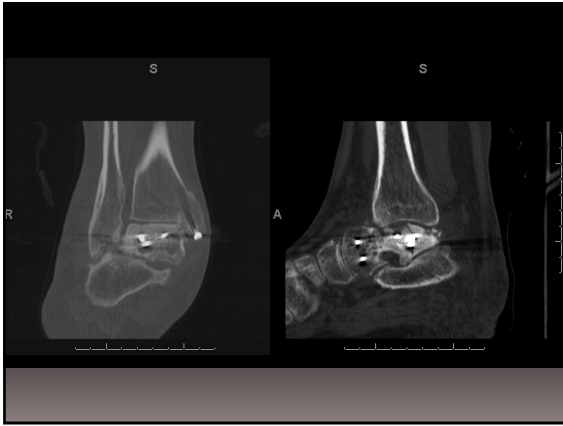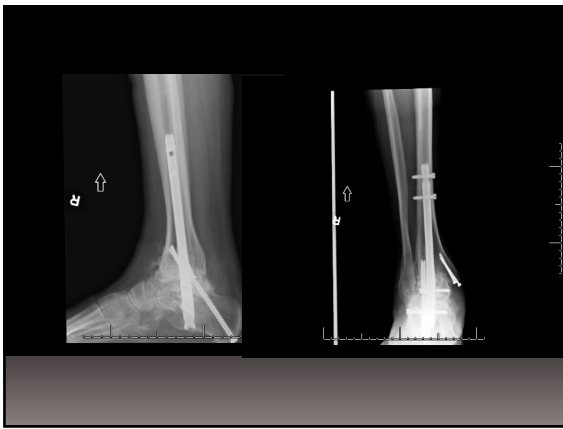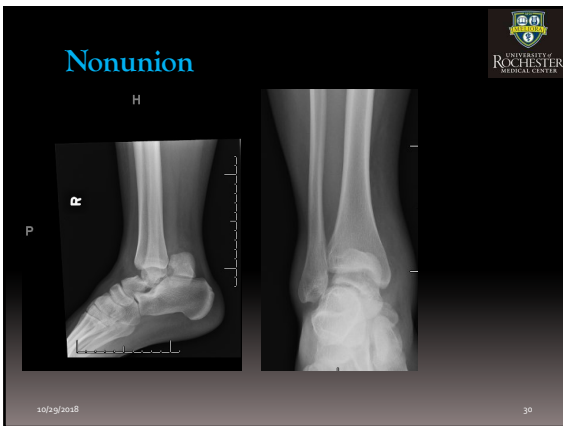


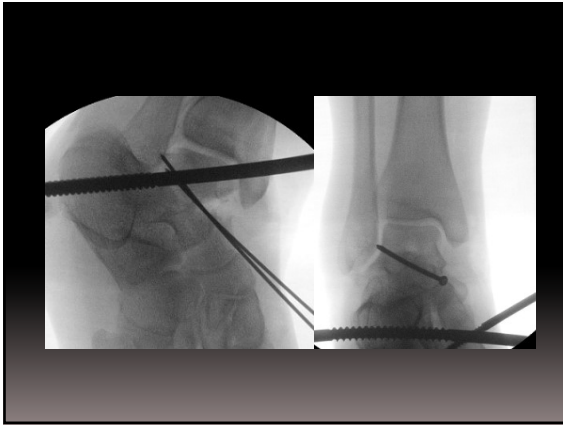


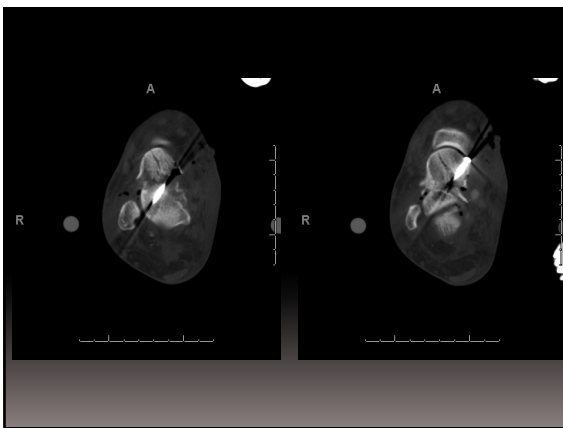


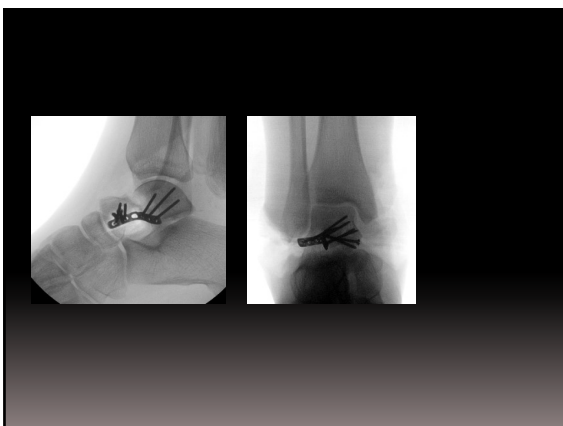


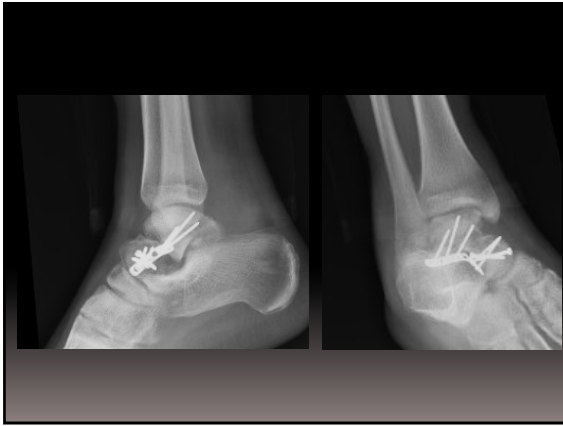




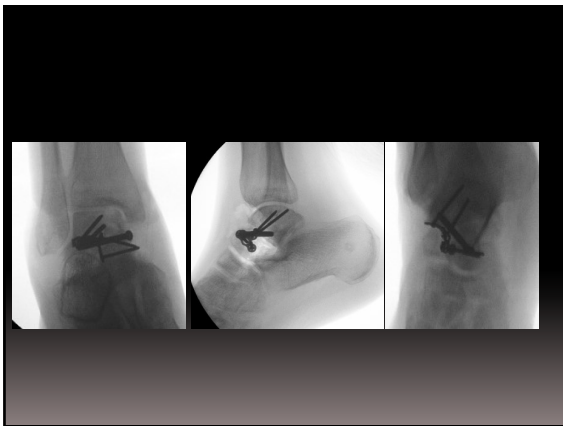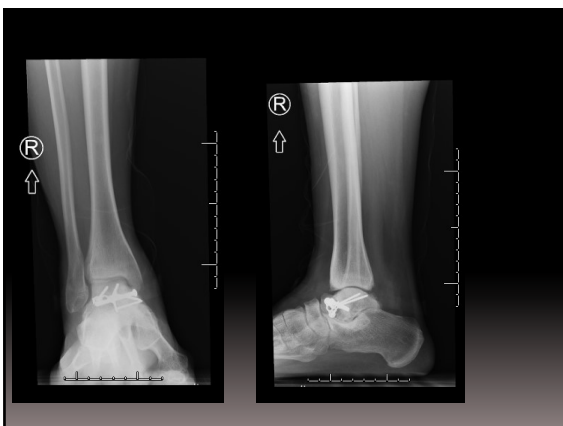




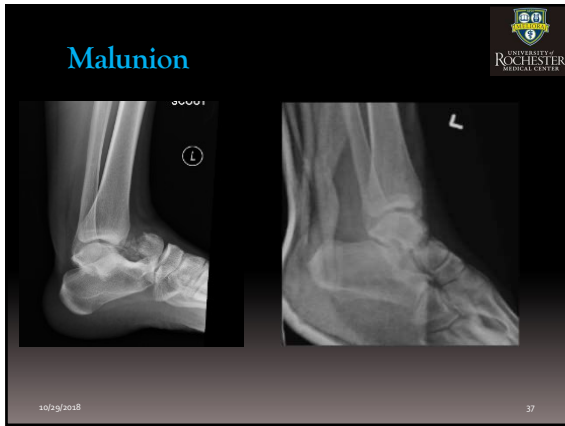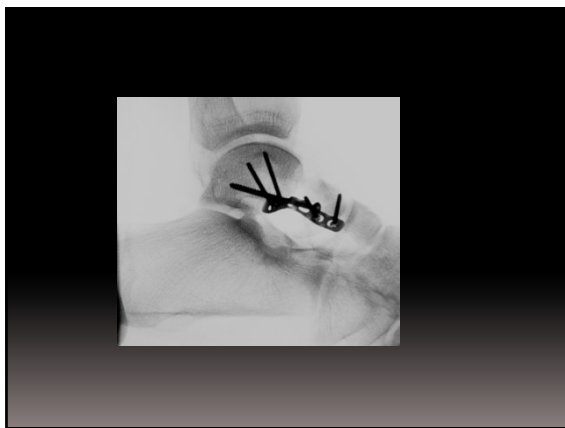




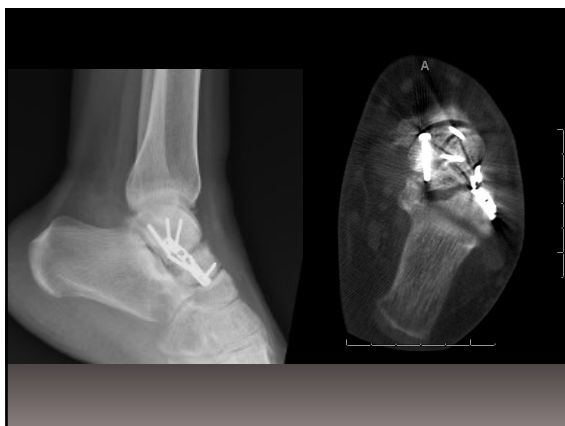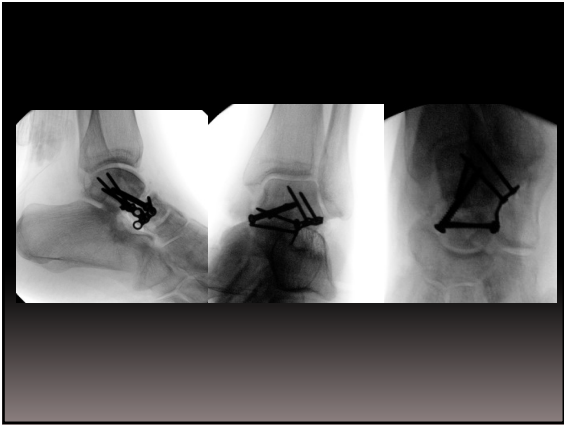








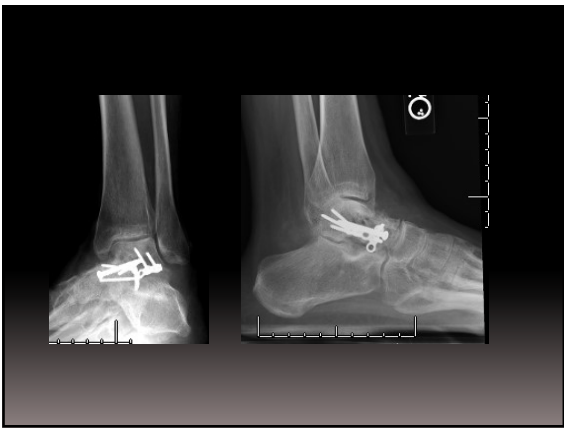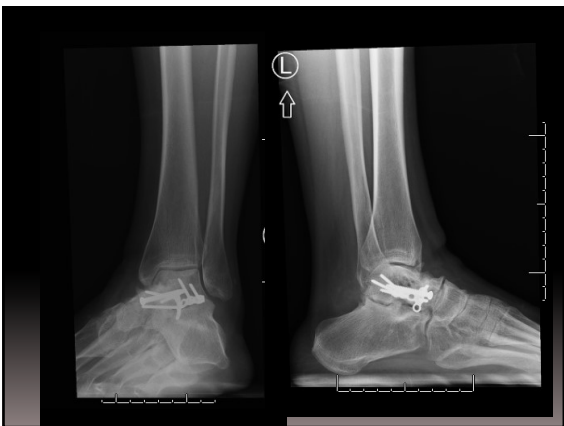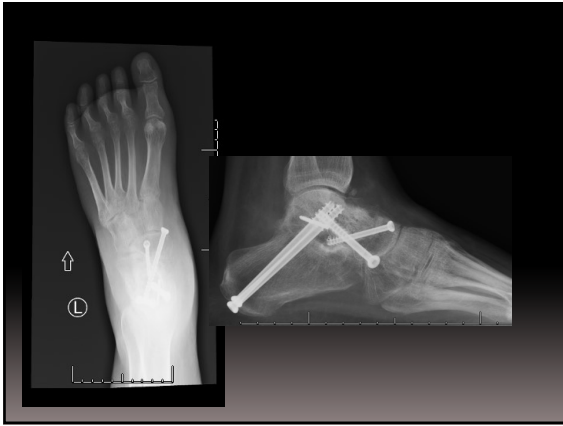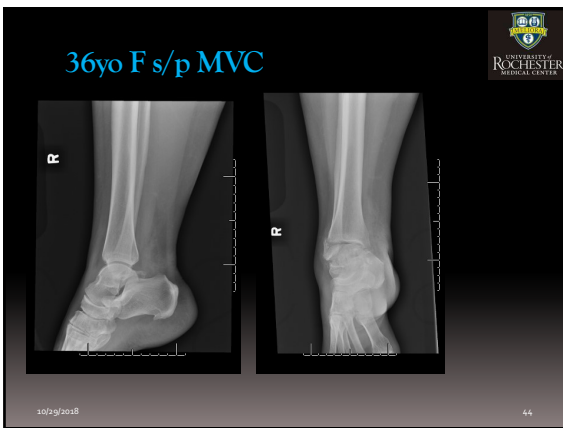


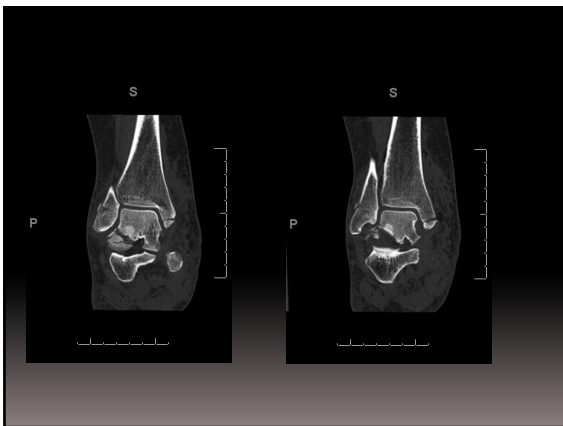


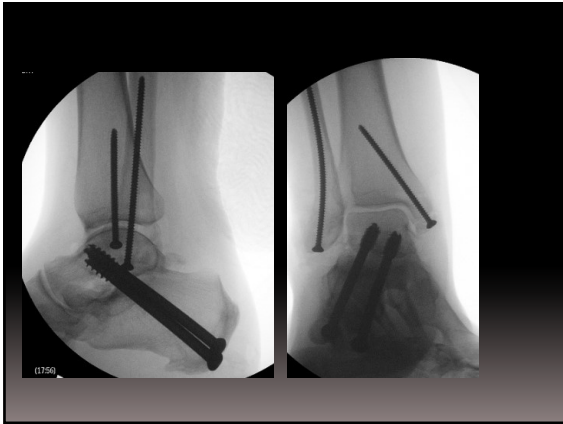


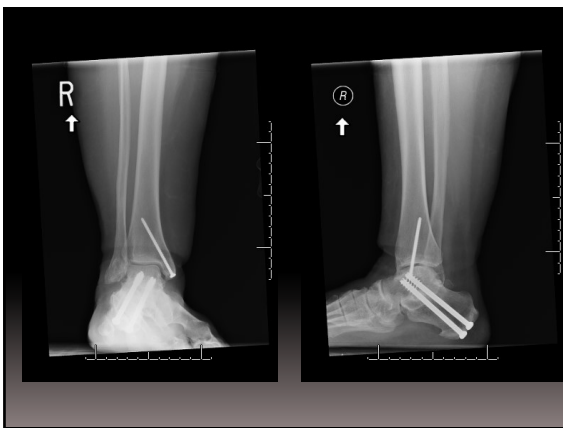






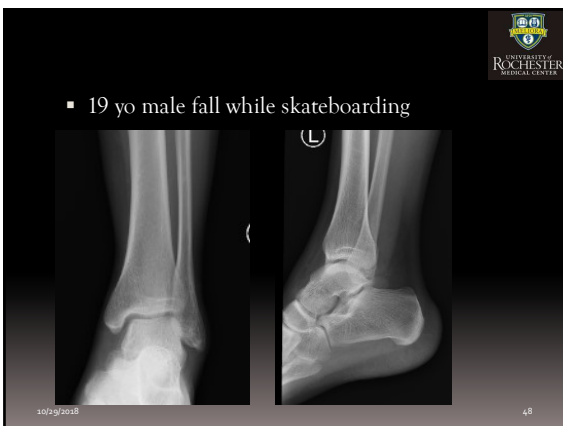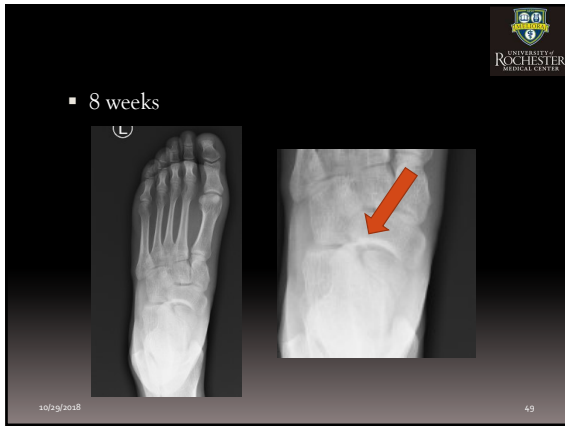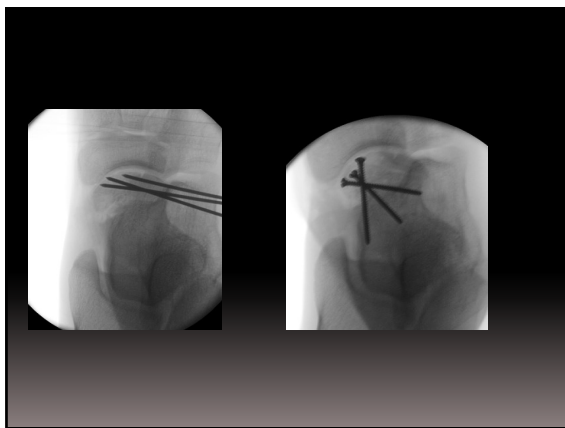


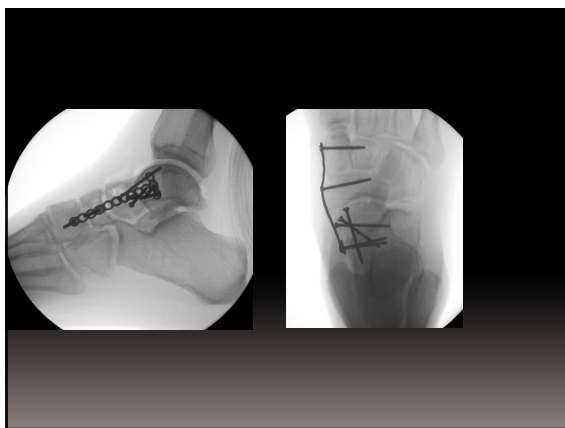

















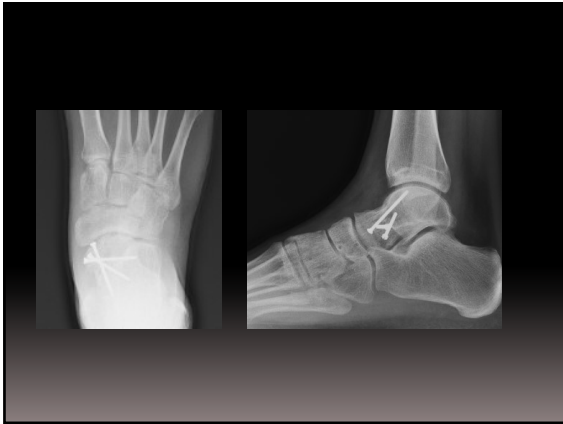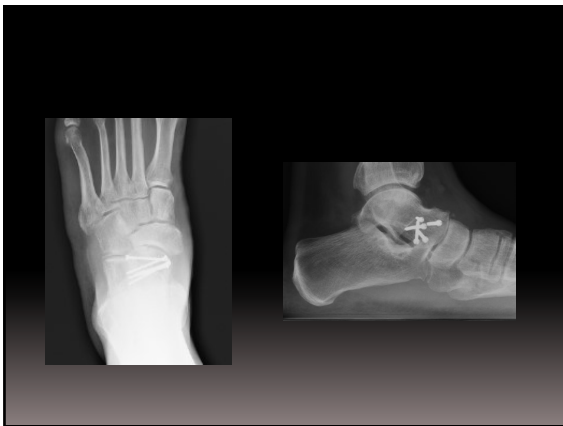TECHNICAL TRICK


**Operative Treatment of Talar Head Fractures:
Surgical Technique**

Michael R. Anderson, DO, John P. Ketz, MD, and Adolph Sam Flemister, MD



Summary

- TWO INCISIONS IS GOLD STANDARD
- URGENT IF DISLOCATED
- TYPE IIB FRACTURES BEHAVE LIKE III/IV
- USE LATERAL PLATE FOR COMMINATION

10/29/2018  55
