


My Bunion Surgery Failed...Now What?



Jeremy Schwartz, MD

Disclosures

- Wright Medical Consultant
- No conflict of interest

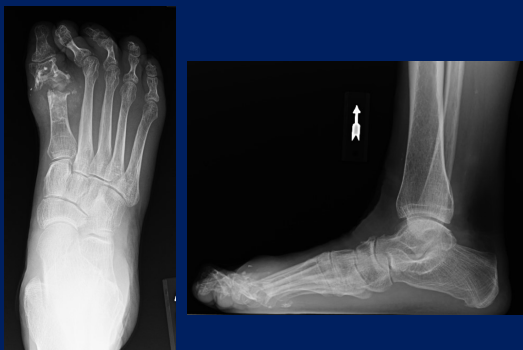Why

- Wrong Plan
- Poor Execution
- Wrong Patient
- Who knows

Now What?

- Tough Cases
- Definitive options
- Pain relief
- Reasonable expectations

CC 76 y/o f



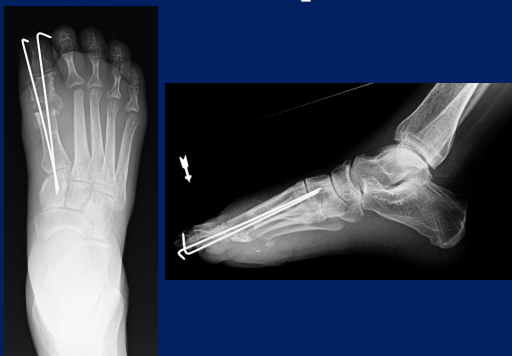What Happened?

- Toe implants
- Short ray
- Elderly low demand and poor ability to maintain NWB

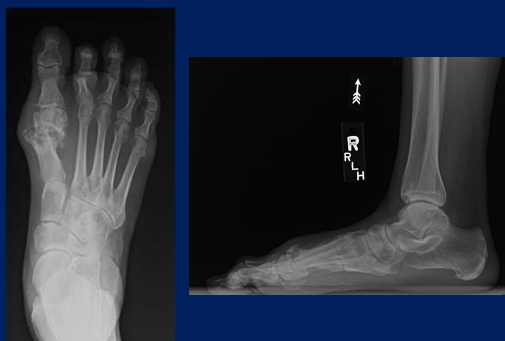Salvage

- Interposition Arthroplasty
- Local Tissue or Graft
- K-wire Stabilization
- Metatarsal Head Excision

Post-Op

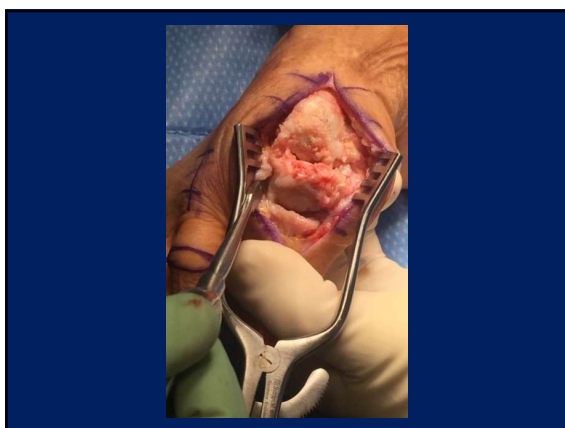


MH 69 y/o f



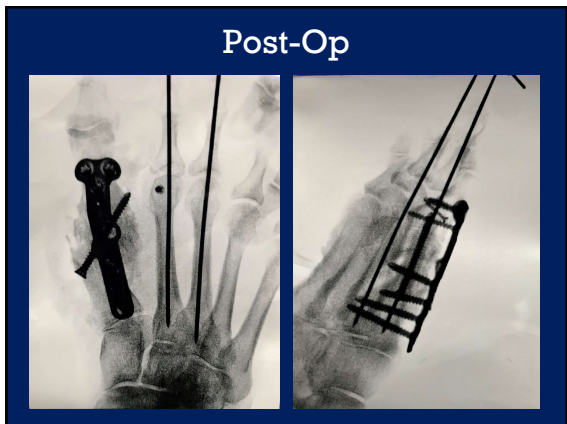
Huh?

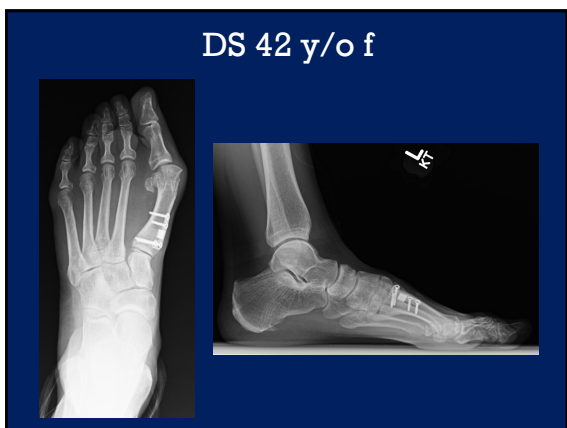
- “No Incision Bunion”
- Wrong Plan and Poor Execution
- Simple Case Made Hard
- Non-Union, Arthritis, Failed Hammertoe



How Did I Fix It?

- Used the Metatarsal Head as a Bone Block
- Fusion
- Weil and Revision Hammertoe





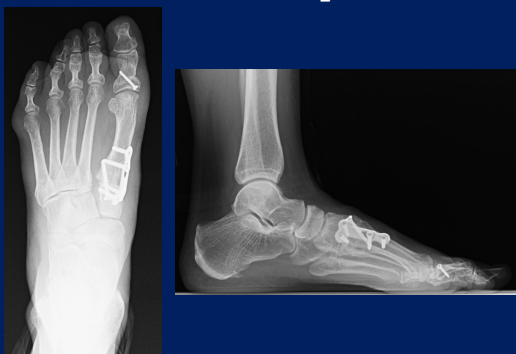Didn't Work...But Why?

- Unrecognized Instability
- Not Enough Surgery
- Opening Wedge...Probably Overused

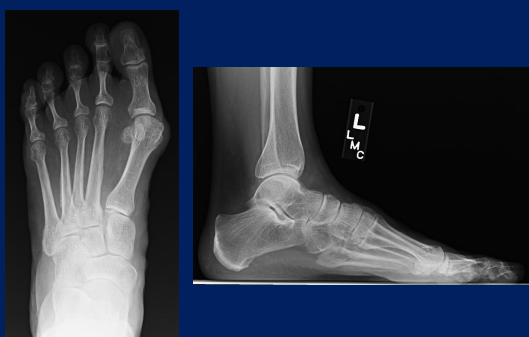Who Came to the Rescue

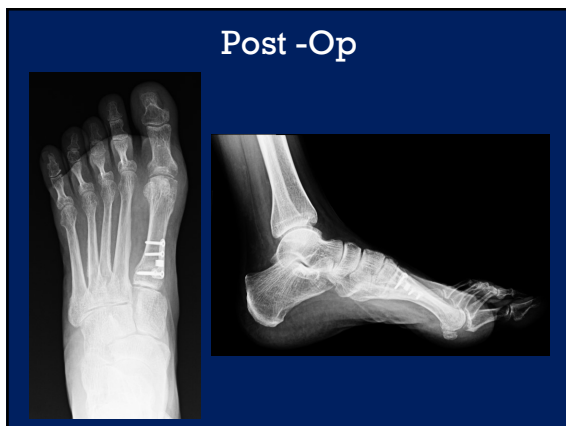- Lapidus and his Sidekick Akin

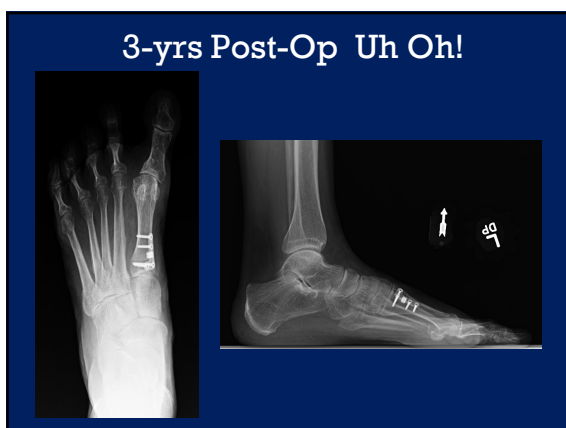DS Post-Op

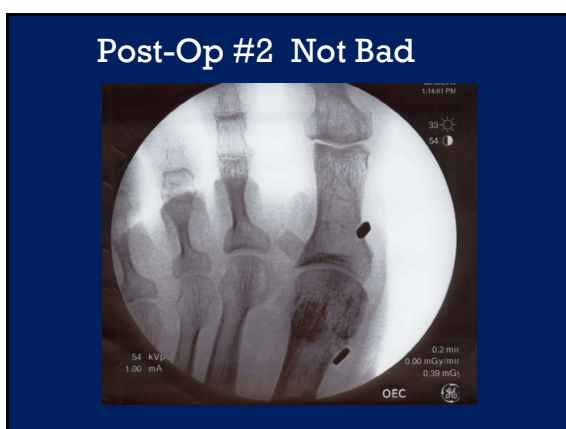

JS 62 y/o f

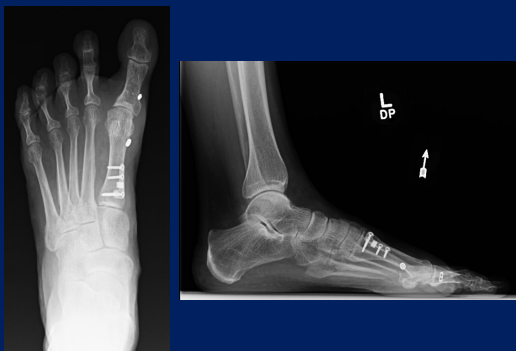







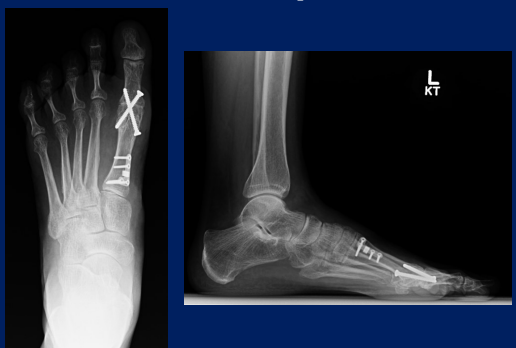Uh Oh!



What the Heck

- Release of the Adductor Hallucis
- Lengthening of the First Ray
- Varus Not Caught Early Enough
- Stiff 1st MTP

Finally



Final Thoughts

- More is Usually Better
- DMAA, 1st Ray Instability and Rotation
 - PROMO
- Make the Revision the Final Case
 - Fusion, Lapidus or Interposition

Thank You
