

COMPLEX ANKLE FUSION


JASON O'DELL, MD
MCLEOD ORTHOPAEDICS
FLORENCE, SC
F.O.R.E. TAMPA FELLOWS REUNION 10.27.18
FELLOWSHIP YEAR 2009-2010

DISCLOSURES

- Medline, Additive Orthopaedics, BESPA
 - Consultant


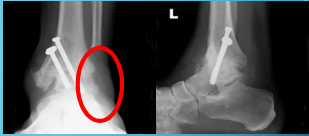
ANKLE

- Constrained articulation of the talus, distal tibia and fibula
- Majority of djd is post-traumatic
- 70% vs 12% inflammatory



ANKLE FUSION

- First described by Albert in 1879
- End stage djd, instability
- Gold standard...
- Still?
- Many techniques for primary fusion



COMPLEX = ?

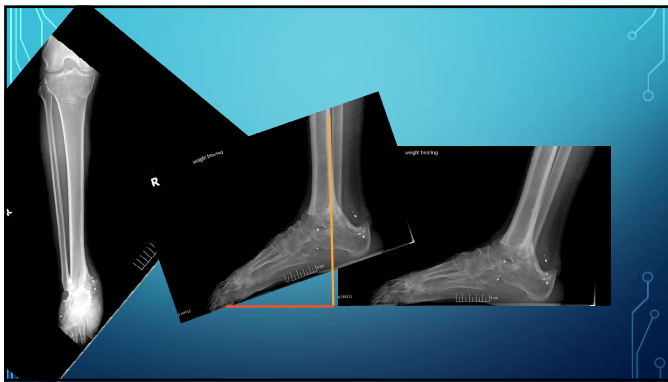
- Charcot
- Bone loss/posttraumatic
- Significant deformity/instability
- Revision of failed surgery or TAR

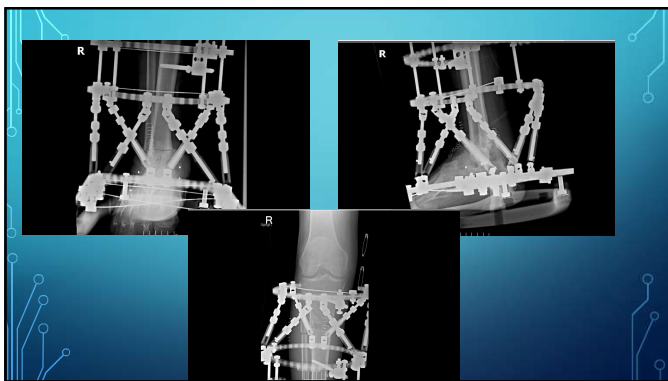
PATIENT FACTORS

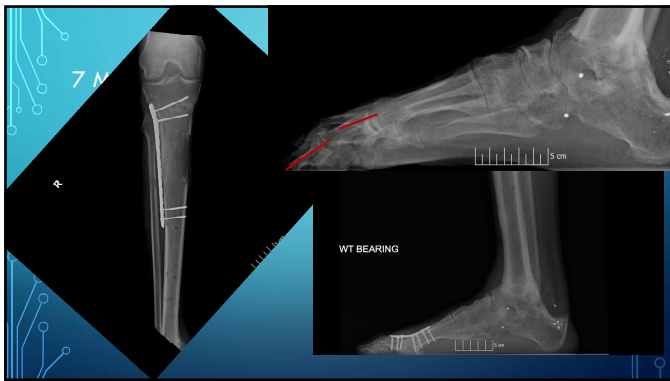
- Diabetic control
 - Neuropathy, increased nonunion rates and delayed frx healing, medial sclerosis
- Smoking
 - 3.75 times nonunion rate in ankle arthrodesis
 - No elective surgery offered
- Vitamin D deficiency
 - Associated with injury but data lacking overall in fusion healing
 - Start looking...25-OH vitamin D levels
 - Ergocalciferol 50k units po qweek x 8 wks

DEFORMITY AND BONE LOSS

- 53 yo male smoker shot with a shotgun in the ankle at age 18.
- Ultimately fused in significant plantar flexion







TALAR ON

- 46 yo female police officer with high speed MVC and floorboard injury
- Initially managed as a sprain at another clinic
- Referred for continued pain and massive swelling.
- Vitamin D level was <10

