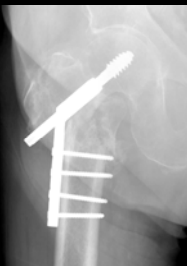

## Intertrochanteric Hip Fractures – Tips and Tricks

Trauma 101  
May 11, 2018

Kyle J. Jeray  
University of South Carolina,  
Greenville  
Greenville, SC



---

---

---

---

---

---

---

---

## I have no potential conflicts with this presentation

My disclosures –Editorial board JOT and JBJS  
Am; Reviewer JBJS, JOT, JAAOS; Consultant  
for Zimmer, Radius; ABOS Oral Board  
Examiner; Chairman of AOA/Own the Bone  
Committee; Research support from  
Department of Defense, CIRH, NIH, AO North  
America, OTA  
Department has received funds for educational  
support from Smith & Nephew, Zimmer,  
Synthes, Stryker

---

---

---

---

---

---

---

---

## Objectives

- Describe fracture patterns as stable or unstable
- Understand fracture anatomy and its contributions to fracture stability
- Review the current literature on treatment of unstable fractures
- Tips and Tricks related to the above

---

---

---

---



---

---



---

---

### Incidence



- 150,000/yr. currently
- 250,000/yr. by 2040
- 90% > 65 yrs. of age
- 50 - 60% unstable and increasing



---

---

---

---

---

---

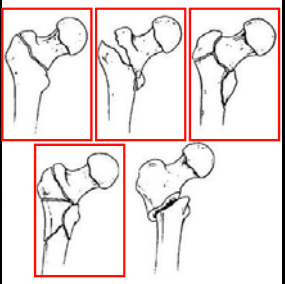
---

---

### Classification

- Many existing classification schemes

- stable
- Unstable
  - More common
  - ↑ age
  - ↓ bone density



---

---

---

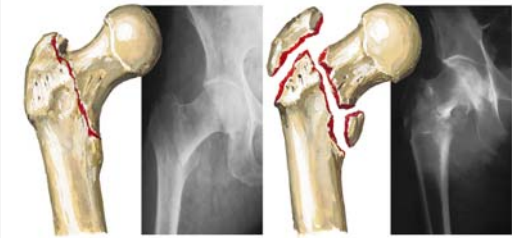
---

---

---

---

---



---

---

---

---

---

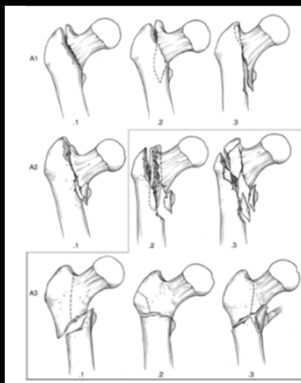
---

---

---

**OTA Classification**

Disruption/ comminution  
of medial buttress  
Trochanteric comminution  
Reverse obliquity  
Subtrochanteric extension  
Transverse



---

---

---

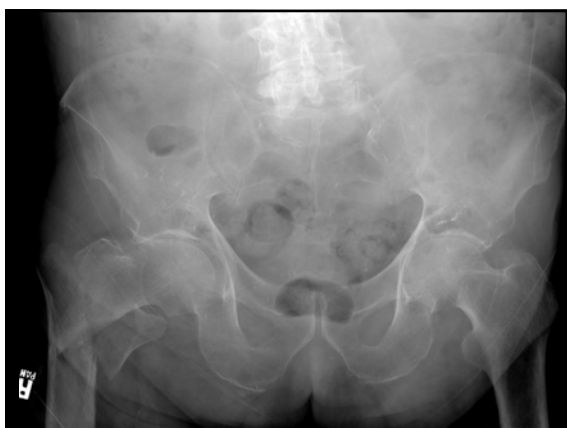---

---

---

---

---



---

---

---

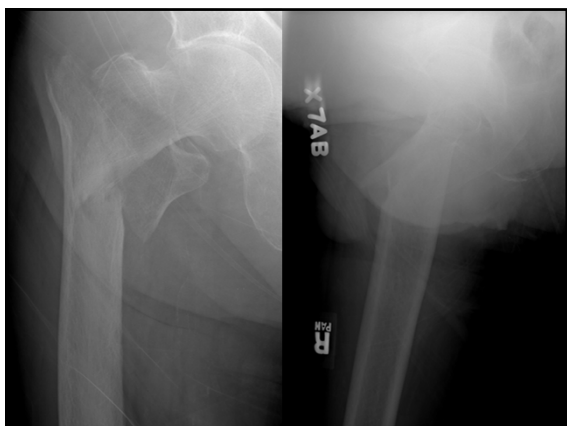
---

---

---

---

---



---

---

---

---

---


---

---

---

**IS THIS FRACTURE STABLE?**

A. YES  
B. NO  
C. DON'T KNOW



---

---

---

---

---

---

---

**TREATMENT OPTIONS**

A. Sliding Hip Screw  
B. Intramedullary Hip Screw  
C. Prosthetic Replacement  
D. Other

---

---

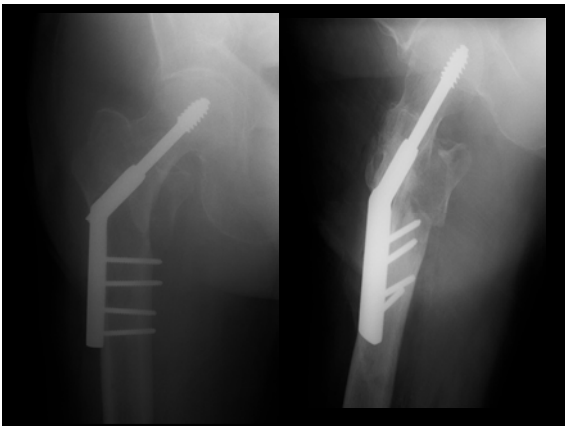
---

---

---

---

---



---

---

---

---

---

---

---

## CRITIQUE FIXATION

- A. Looks Great
- B. Ok. Will probably get away with it
- C. What were they thinking?

---

---

---

---


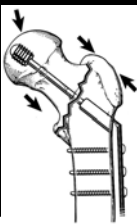
---

---

---

## SLIDING HIP SCREW

- Overall excellent results in stable fractures
- Tip apex distance
- 5%-25% failure rate (screw cutout) particularly in unstable fracture patterns



---

---

---

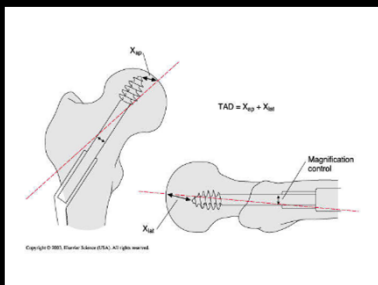
---

---

---

---

## Tip #1: Tip-Apex Distance



---

---

---

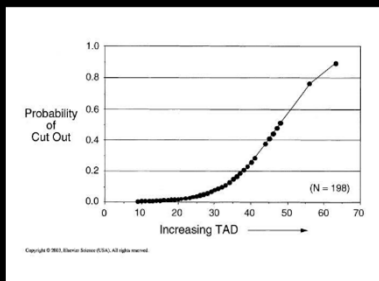
---

---

---

---

### Tip #1: Tip-Apex Distance Applies to Nails as well?



---

---

---

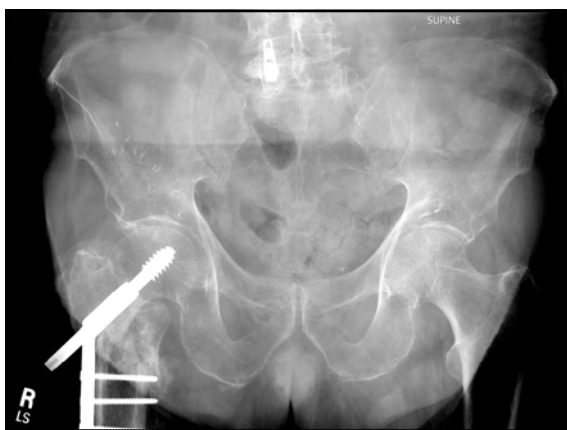---

---

---

---

---



---

---

---

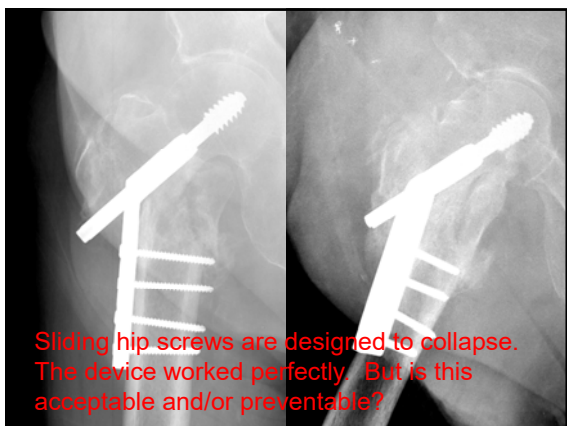
---

---

---

---

---



---

---

---

---

---

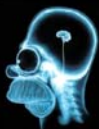---

---

---

## Tip #2 – RECOGNIZE UNSTABLE FRACTURES

- Unstable
  - Posteromedial comminution with loss of lesser trochanteric buttress
    - “3 part” - some judgement
    - “4 part” - no thinking required



---

---

---

---

---

---

---

---

## SHORTENING/COLLAPSE CAN BE PROBLEMATIC

- Limb shortened, abductor tension shortened
- 15 mm sliding associated with failure and pain in unstable fractures

Jacobs, Rha, Steinberg, Baixauli

---

---

---

---

---

---

---

---

## Tip #2 – RECOGNIZE UNSTABLE FRACTURES

- Large or comminuted posteromedial cortex
- Loss of the lateral cortical wall
- Reverse oblique or transverse fracture pattern
- Intertrochanteric with subtrochanteric extension

---

---

---

---

---

---

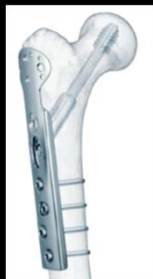---

---



### Tip #3 -TREATMENT OPTION FOR UNSTABLE FX IN OR

- Trochanteric buttress plate



---

---

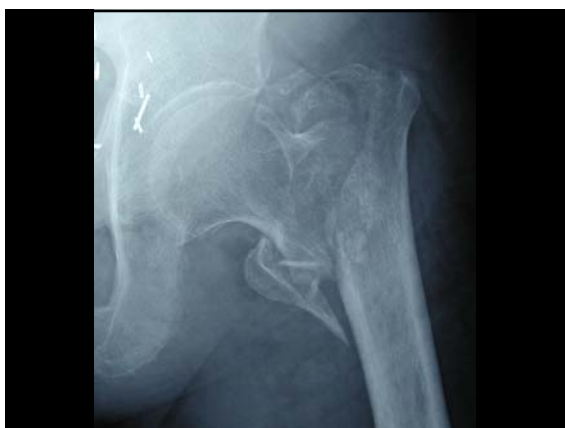---

---

---

---

---



---

---

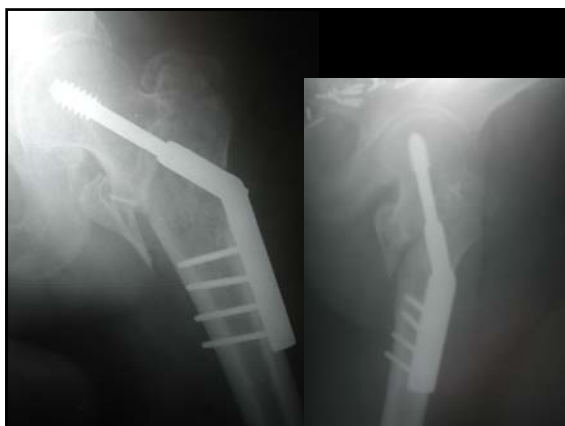---

---

---

---

---



---

---

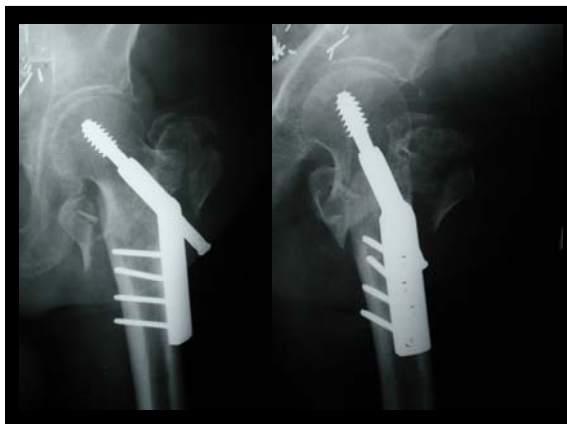
---

---

---

---

---



---

---


---

---

---

---

---



---

---

---

---

---

---

---

### Why change to IM Device?

- IM Device Theoretical Advantages
  1. Implant more central, smaller bending moment, effectively stronger
  2. Implant may provide buttress to resist shortening
  3. Less hardware irritation?
  4. Less surgical trauma?
    - Less blood loss/transfusion
    - Improved healing
  5. Shorter operative and fluoroscopy times?

---

---

---

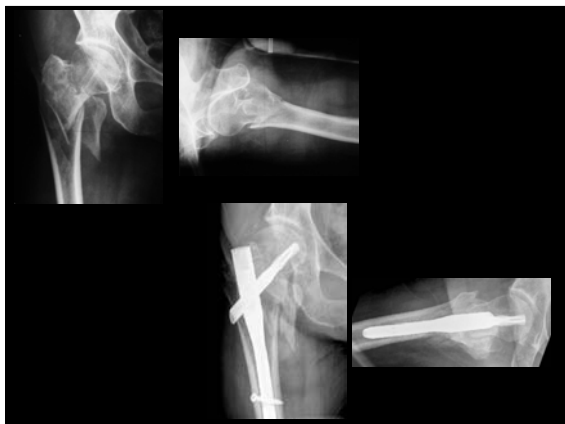---

---

---

---





---

---

---

---

---

---

---

**Tip #4 - Cost**



 CHS ~ \$600 - \$800

 IM Device ~ \$1500 - \$2500

---

---

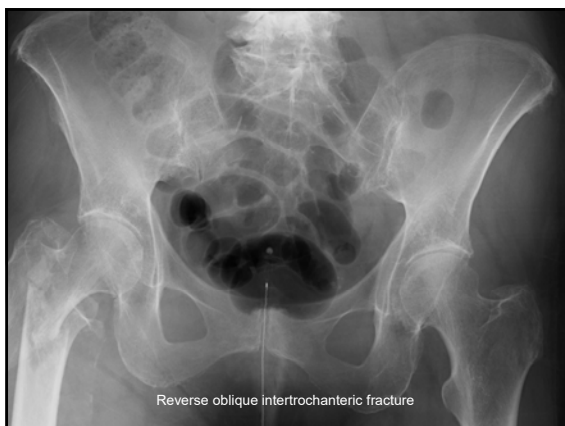---

---

---

---

---



---

---

---

---

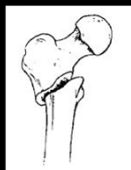
---

---

---

## Tip #5 – Recognize Reverse Obliquity Fractures

- “high subtroch”
- “reverse obliquity”
- ao/ota 31-a3
  - good evidence to suggest superiority of



**IM implant!!!!!!**

Kregor, et al., JOT, January 2005  
Unstable Pertrochanteric Femoral Fractures  
- failure rates with CHS too high for recommended use  
(evidence-based literature review)

---

---

---

---

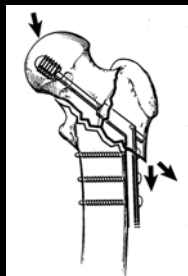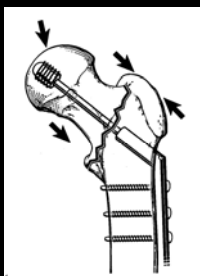
---

---

---

---

## Reverse Obliquity Fractures



---

---

---

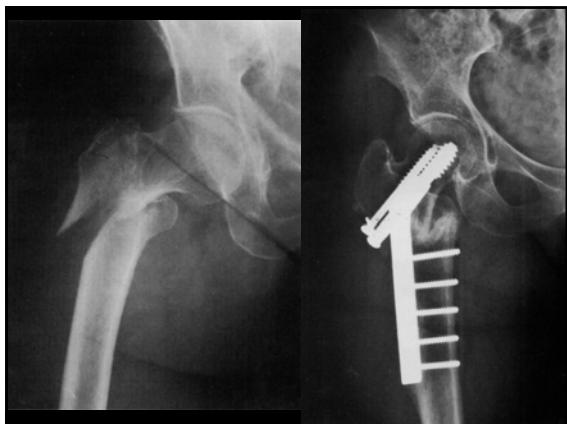---

---

---

---

---



---

---

---

---

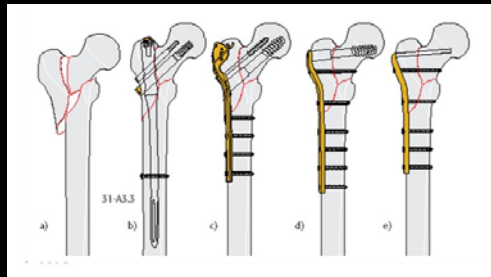
---

---

---

---

## Reverse Obliquity Fractures



---

---

---

---

---

---

---

---

## REVERSE OBLIQUE FRACTURES

- **95° fixed angle devices performed significantly better than SHS** for reverse obliquity fractures
- Results worse for fracture with poor reduction and poorly placed implant

Haidukewych (2001)

---

---

---

---

---

---

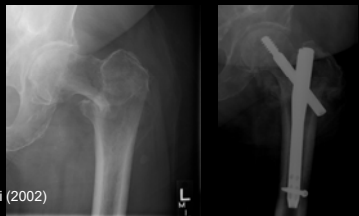---

---

## REVERSE OBLIQUE and TRANSVERSE IT FRACTURES

IMHS or 95° Screw Plate

- **IM Nail shorter operative time, less blood loss and shorter hospital stay**



---

---

---

---

---

---

---

---

### Tip #6 - Fracture Reduction

- Neck / Shaft Axial Alignment
- Translational Displacement
- Anatomic Reduction of Individual Fragments Not Necessary
- Reduction Maneuver
  - Traction
  - Internal Rotation

---

---

---

---

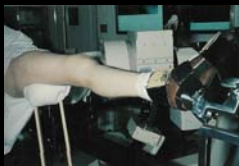---

---

---

### Posterior Sag

- Typically NOT a problem in stable fracture pattern
- External device
- Internal device



---

---

---

---

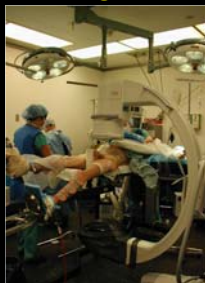---

---

---

### Tip #7 - Intra-Operative Positioning and Starting Point

- Scissors Position
  - un-injured limb
    - Extended Hip
    - Femoral nerve palsy



---

---

---

---

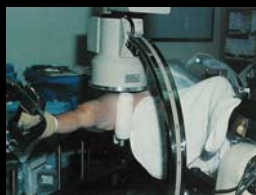---

---

---

### Intra-Operative Positioning

- Hemilithotomy Position
  - un-injured limb
    - Hip Flexed
    - Abducted
    - Knee Flexed
- Difficult in some pts



---

---

---

---

---

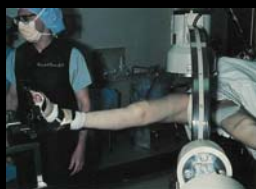---

---

---

### Intra-Operative Positioning

- Abducted and Extended Position
  - un-injured limb
    - Hip Abducted
    - Knee extended



---

---

---

---

---

---

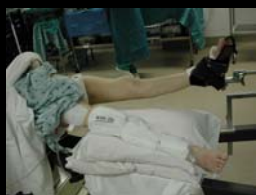---

---

### Intra-Operative Positioning

- Scissors Position
  - un-injured limb
    - Extended Hip
    - Femoral nerve palsy

Pillows for support



---

---

---

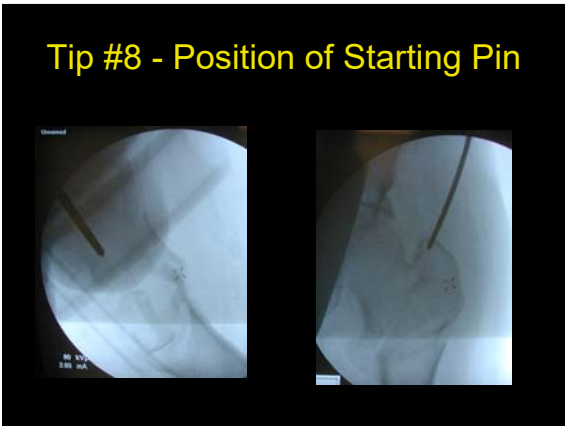
---

---

---

---

---



---

---

---

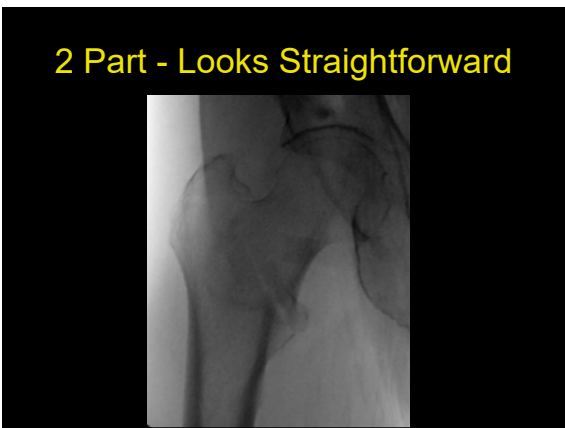
---

---

---

---

---



---

---

---

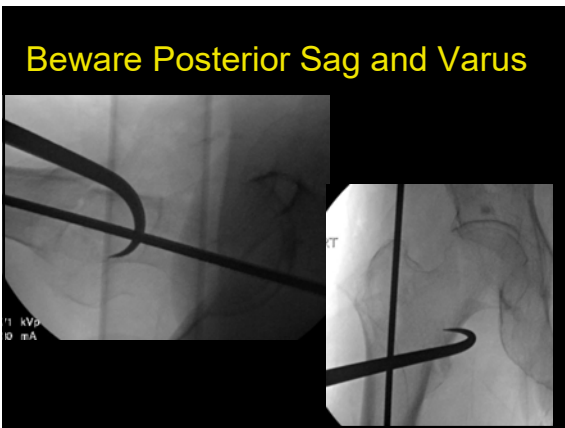
---

---

---

---

---



---

---

---

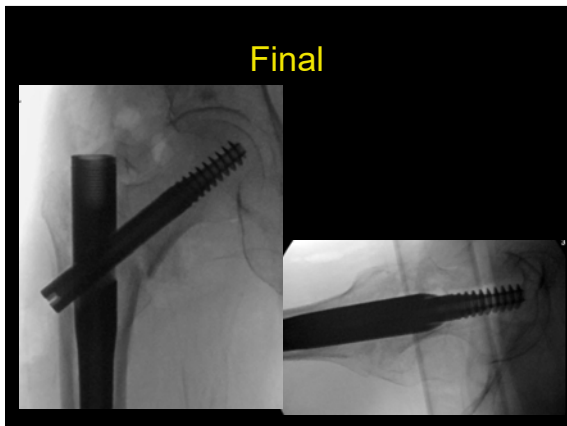
---

---

---

---

---



---

---

---

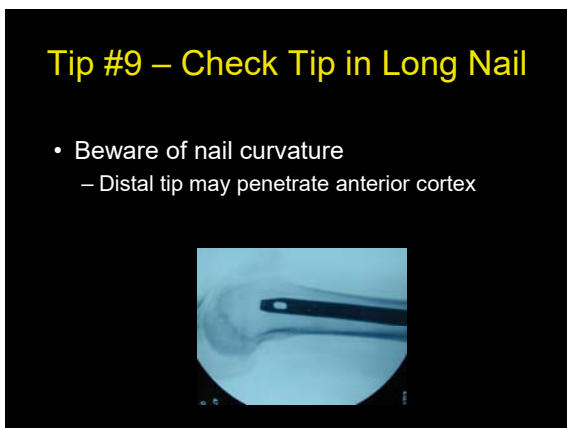---

---

---

---

---



---

---

---

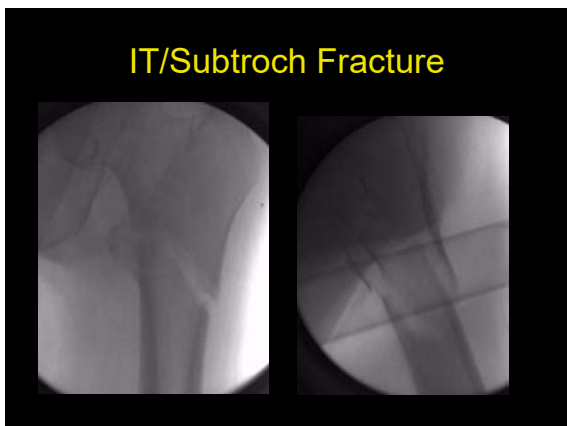
---

---

---

---

---



---

---

---

---

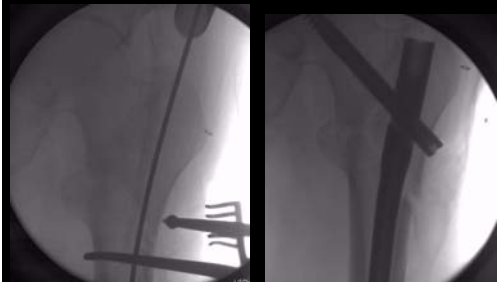
---

---

---

---

Tip #10 - Use of Bone Hook



---

---

---

---

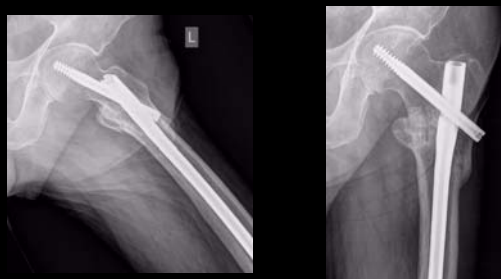---

---

---

---

Healed Fracture



---

---

---

---

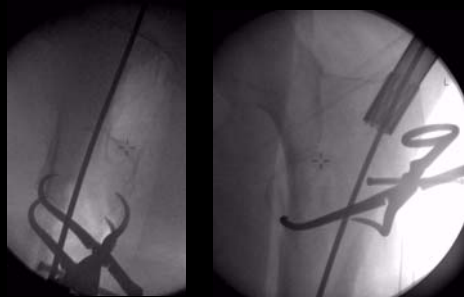
---

---

---

---

Tip #11 – Open the Fracture!  
Use Clamps



---

---

---

---

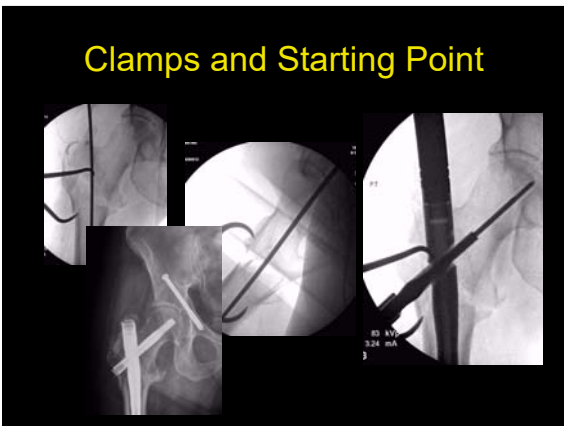
---

---

---

---

### Clamps and Starting Point



---

---

---

---

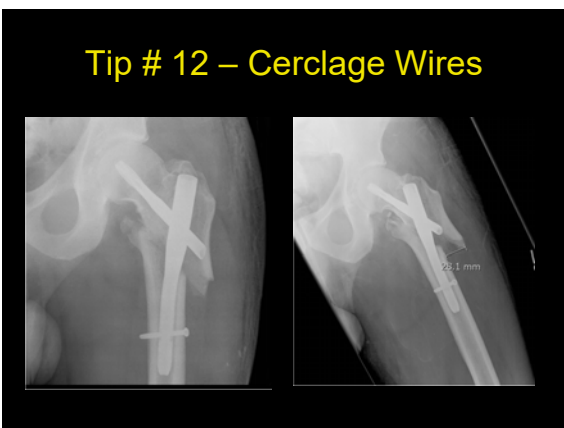
---

---

---

---

### Tip # 12 – Cerclage Wires



---

---

---

---

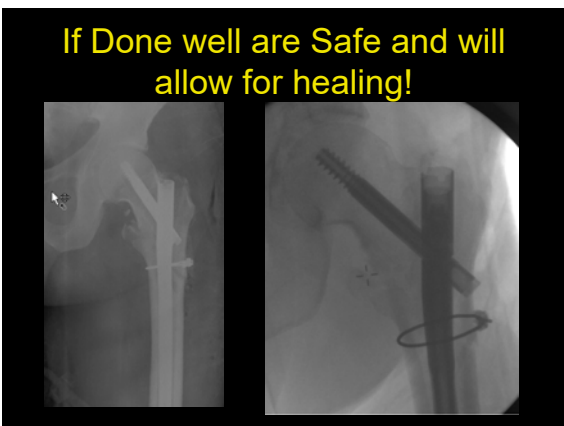
---

---

---

---

If Done well are Safe and will allow for healing!



---

---

---

---

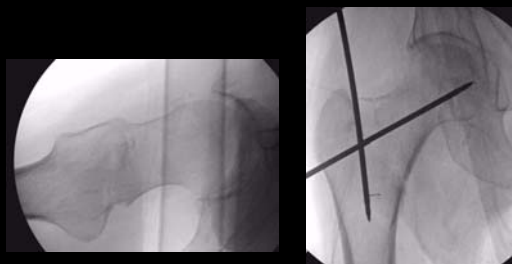
---

---

---

---

Tip # 13 – Basicervical Fractures



---

---

---

---

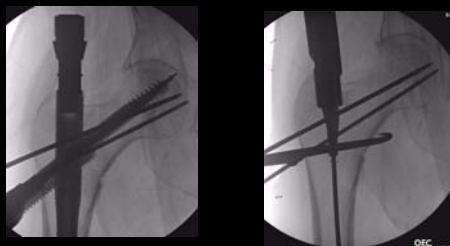
---

---

---

---

Rods MAY work BUT Recommend Side Plate!



---

---

---

---

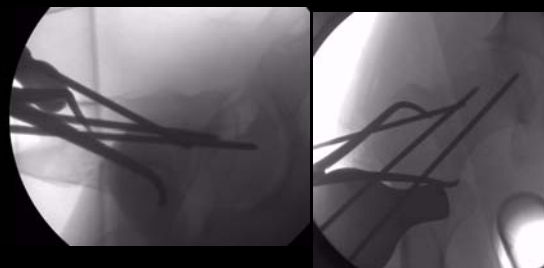
---

---

---

---

Basicervical Fracture - Pins



---

---

---

---

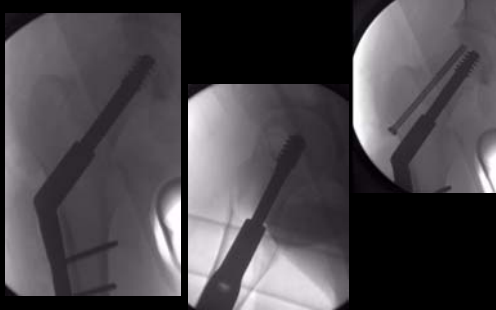
---

---

---

---

### Basicervical Fixation – Side Plate!



---

---

---

---

---

---

---

---

### Summary

1. Reduce Fracture – whatever it takes (pins, clamps, bone hooks, Ball spike pushers, cerclage wires)
2. Remember TAD
3. Stable versus Unstable to select implant
4. Cost may play a role at your institution?
5. Starting Point KEY to success AVOID VARUS!
6. The set up will make life easier supine or lateral
7. Long Nails check distally

---

---

---

---

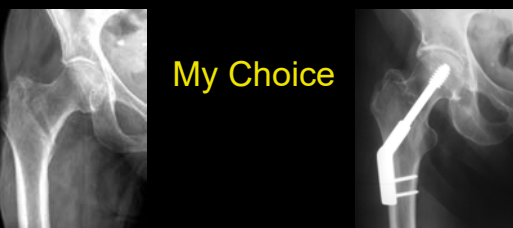
---

---

---

---

### My Choice



- Stable
  - chs (2 hole side plate)
    - Consider variable angle
      - ∩ inventory
      - intra-op ability to adjust

---

---

---

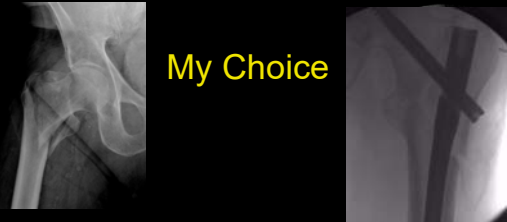
---

---

---

---

---



**My Choice**

- Unstable
  - Im device
    - Helps decrease shortening
    - Short if no shaft extension
      - Distal locking screws
      - Beware anterior cortex cutout

---

---

---

---

---

---

---

---

**Thank you**

---

---

---

---

---

---

---

---