

Posterior Instability of the Shoulder: *Trauma 101: Shoulder Session #1*

Brian Grawe, MD

Assistant Professor

Orthopaedics & Sports Medicine

5/10/2018



Brian Grawe, MD

Assistant Professor

Phone Number: 513-558-4516

Email: grawebn@ucmail.uc.edu

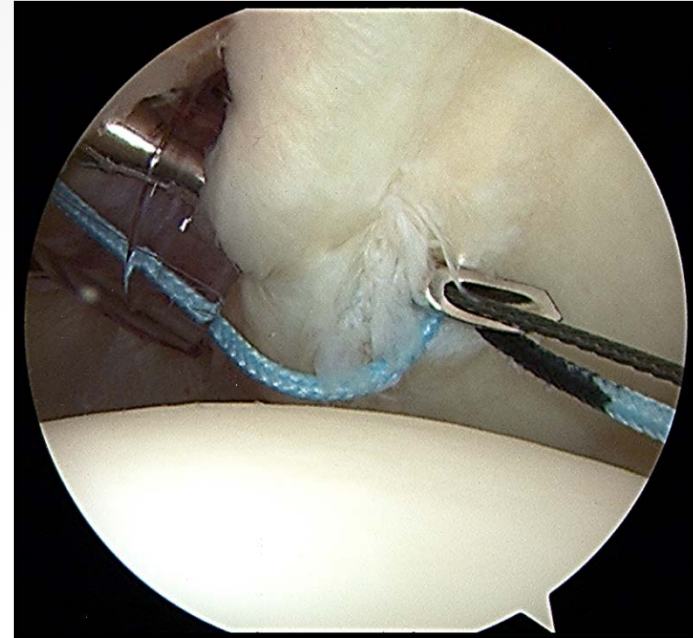


I HAVE NO DISCLOSURES or COI



Outline

- Background
- Anatomy
- Pathogenesis
- Evaluation
- Treatment
- Summary



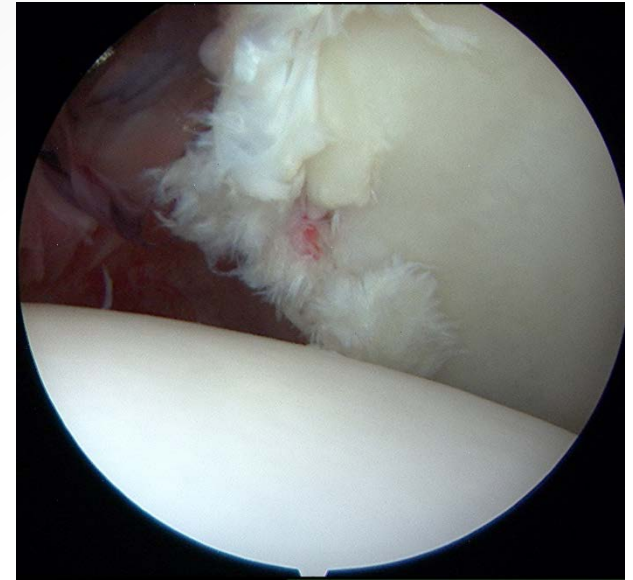
Background

Diagnosis & management

- DIFFICULT (??? Spectrum ???)
- 2-10% of instability (rare)
- Ø Concrete dx criteria
- Painful & delayed
- Referral ≠ unstable

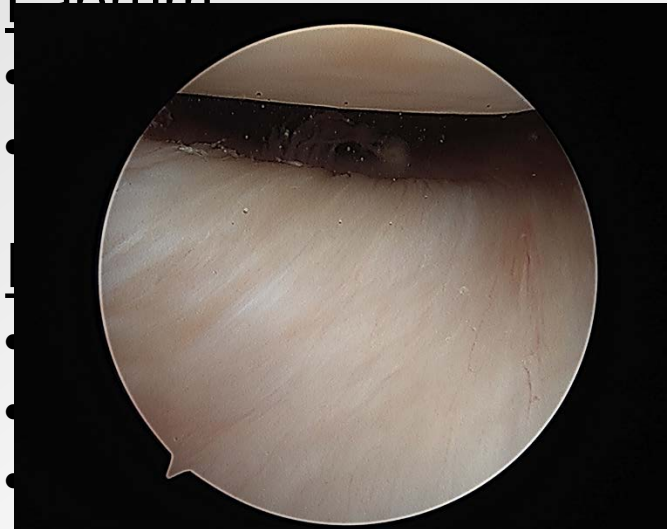Epidemiology

- Males > females
- ~ 50% w/ discrete injury
- 25% w/ relocation event

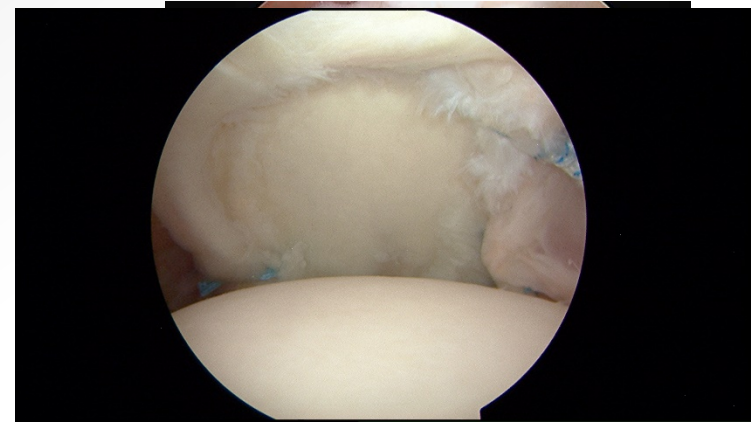


Anatomy: Static Stabilizers

Labrum



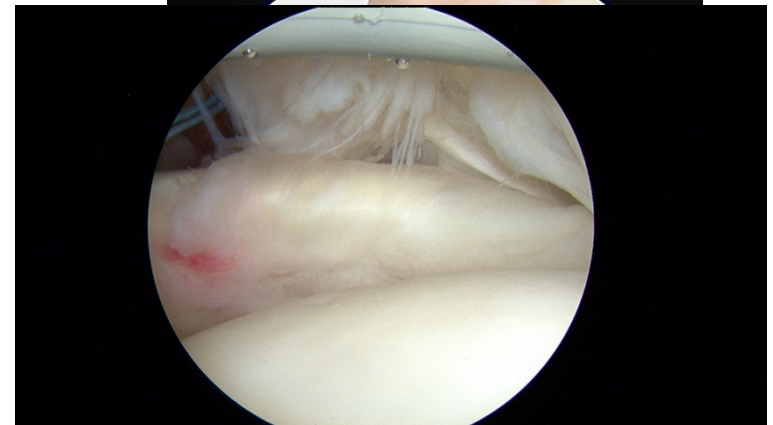
(ete)



- Thin, thin, thin (not resistant)

Rotator Interval ?, SGHL ?

- Diagnosis of exclusion
- The circle is not PB&J



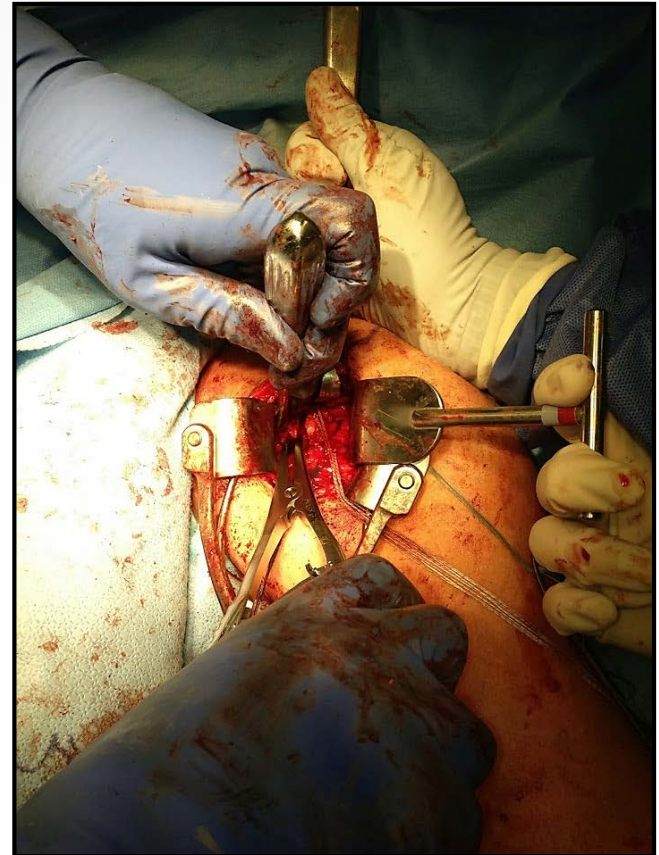
*subscapularis is most important
dynamic stabilizer

*Scapulothoracic
*****MDI

Anatomy: The Glenoid

Higher likelihood

- Retroversion
 - Parada et al Arthrosc 2017
 - Privitera et al JSES 2016
- Dysplasia
 - Galvin et al AJSM 2016
- Increased capsular area
 - Dewing et al AJSM 2008
- **Outcome not effected**
 - Mauro et al AJSM 2016
(Width mattered)



Pathogenesis: Global Organization

1. Repetitive microtrauma

- Most common (unlike anterior)
- Cumulative: bench press, swimming, rowing, blocking (lineman), climbing
- Posterior laxity... ST problems

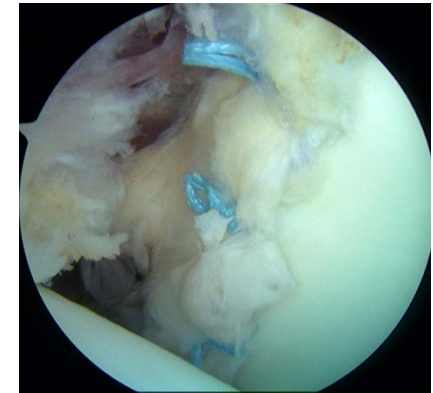
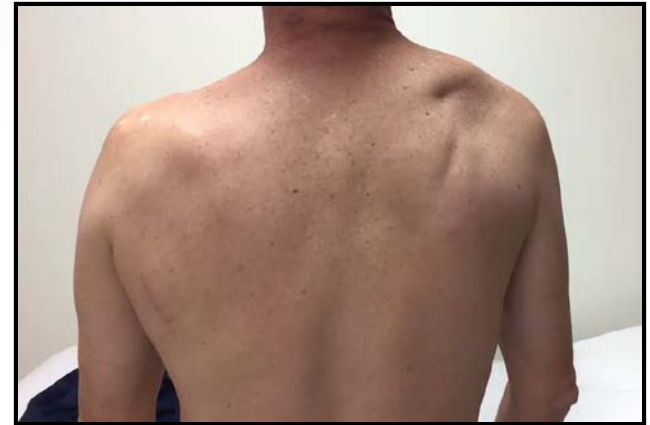2. Acute traumatic

- Discrete injury
- Reverse Bankart

3. Atraumatic

- EDS spectrum (check)

***MDI



Evaluation: Presentation

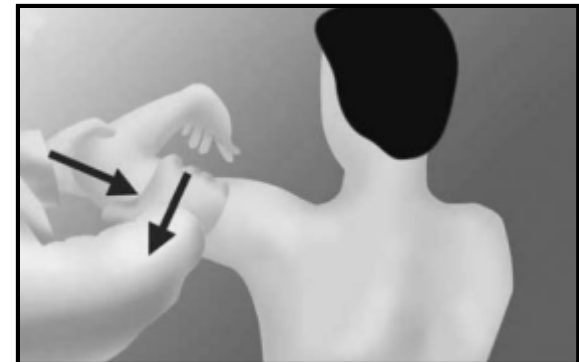
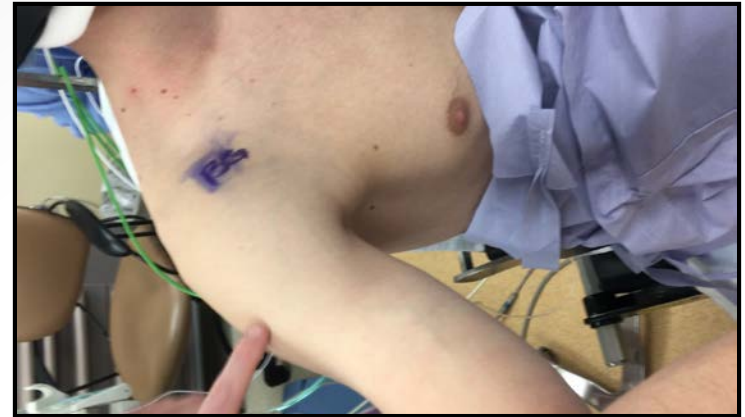- Pain, pain (generalized), pain (deep), PAIN
 - Bench press/push-up ↓
 - Confused referral
 - Rule it out... see it

- Voluntary positional
 - Surgery
- Voluntary muscular
 - MDI
 - No surgery



Evaluation: Physical Examination

- Palpation
 - Posterior joint line pain
- Provocative maneuvers
 - Jerk, Kim, stress test, load & shift
 - Subtly different
 - Kim + Jerk = 97% sensitivity (AJSM 2005)
- START w/ THESE



Evaluation: Imaging

Radiographs

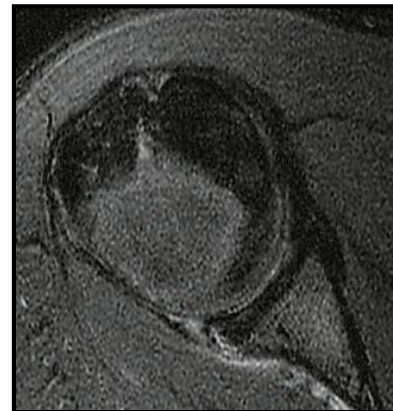
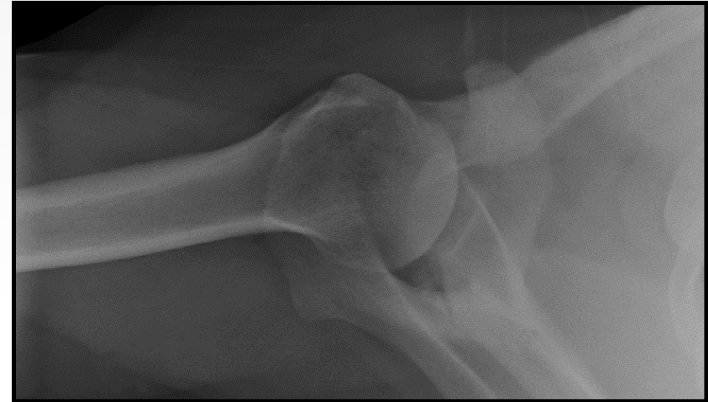
- Glenoid views:
axillary, west point,
& notch

CT

- Osseous injury,
dysplasia & version

MR

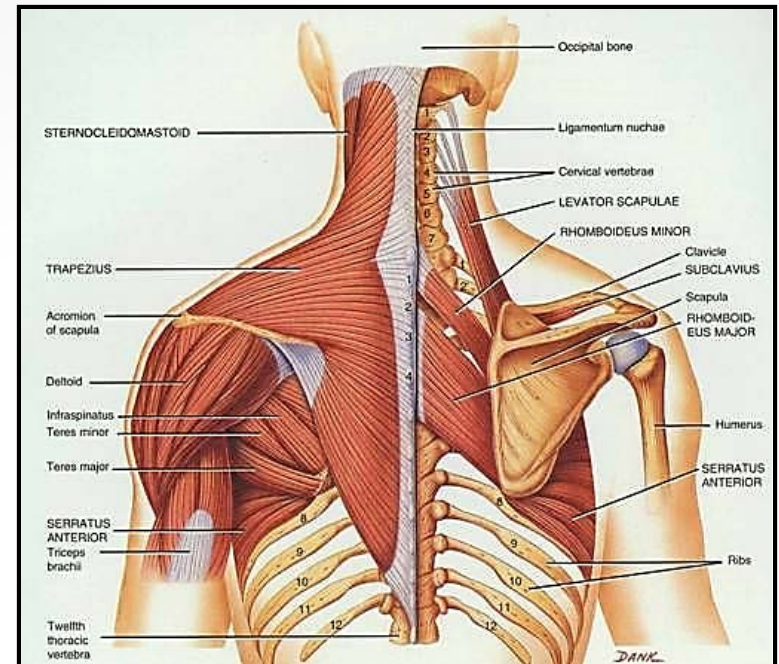
- All soft tissue
structures



Treatment: Non-operative

Majority of patients

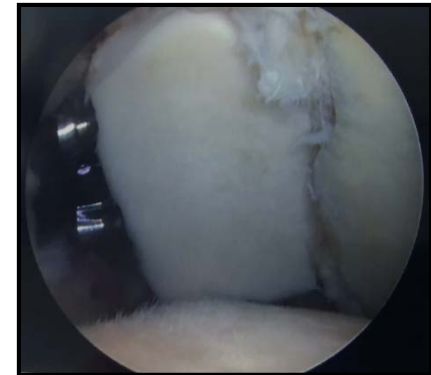
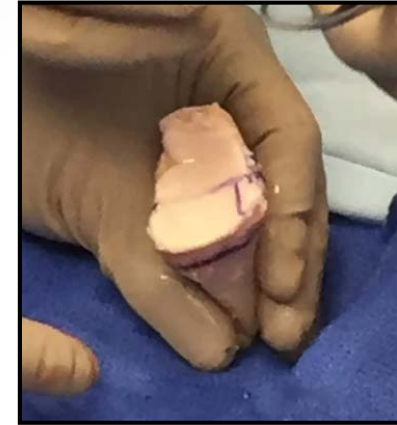- Focus
 - Periscapular muscles
 - Rotator cuff
 - ST mechanics
 - Punch that ceiling
- Bad actors
 - Known dx
 - Positive jerk test



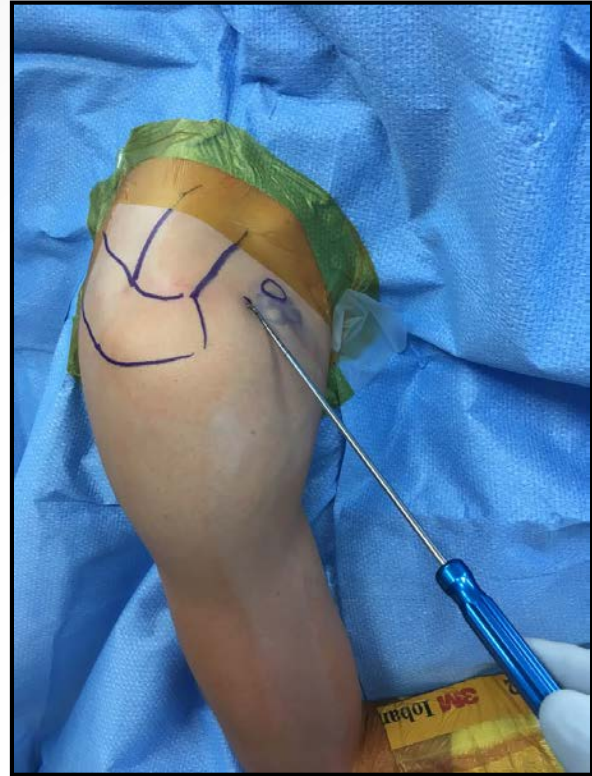
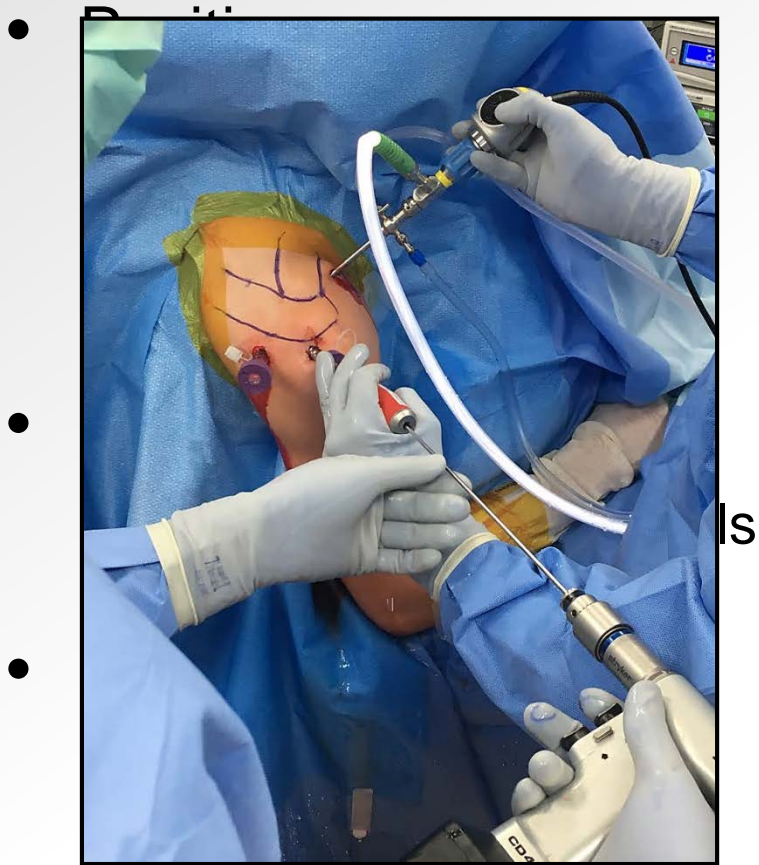
Treatment: Operative

- *Treat the shoulder as an organ and the patient as a whole*
 - Timing
 - Expectations & goals
 - Previous treatments
 - Bone (11mm from bare spot) (no track)

- What we know
 - Unidirectional = better
 - Suture anchors = better
 - Scope = better
 - Throwers = bad



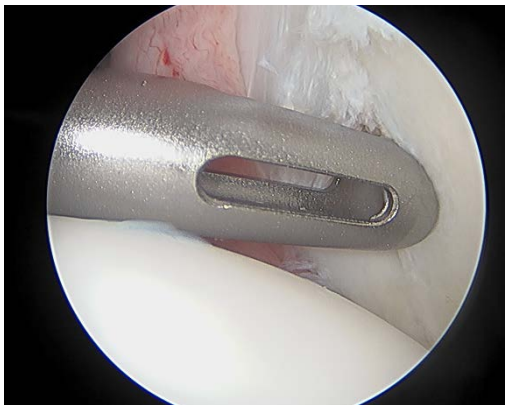
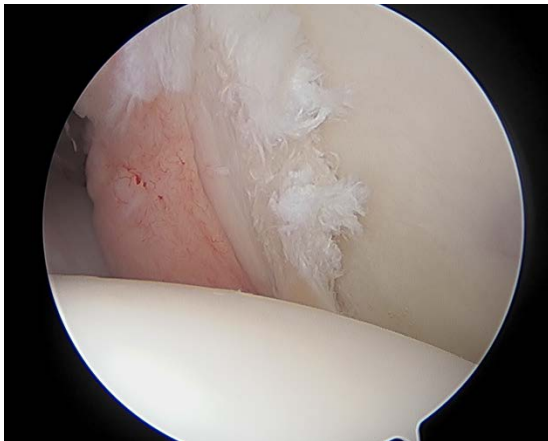
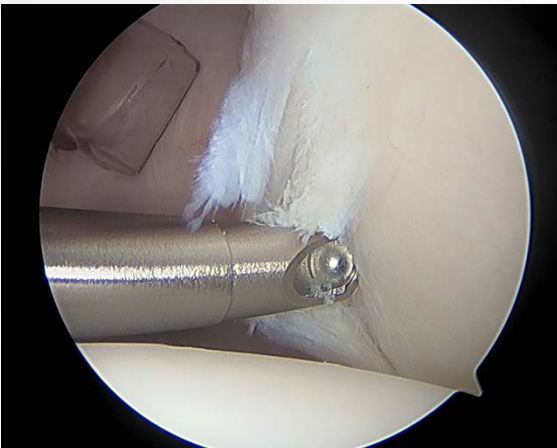
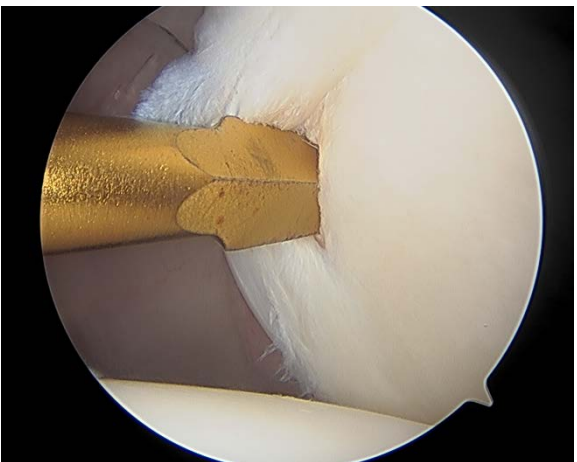
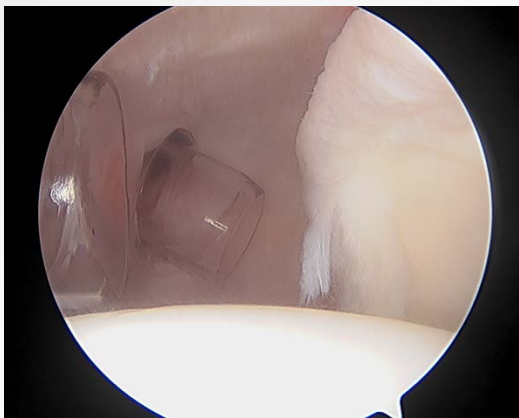
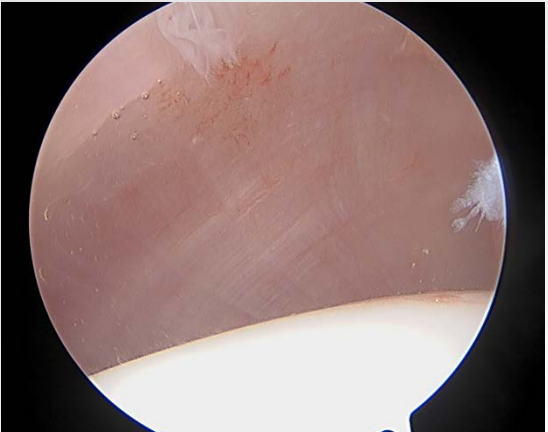
Treatment: "How I Do It"



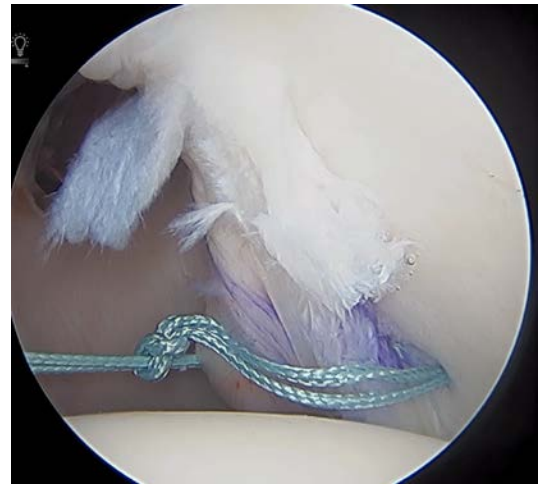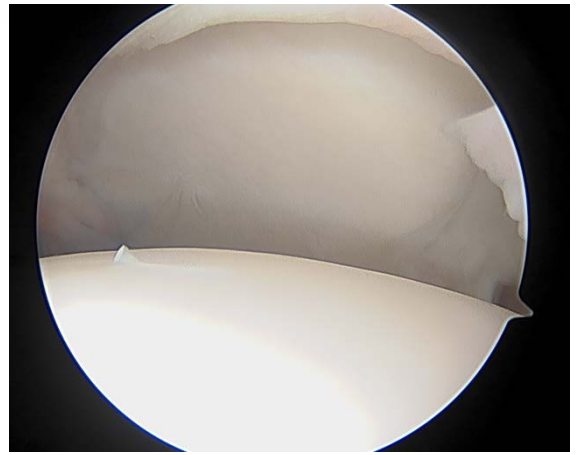
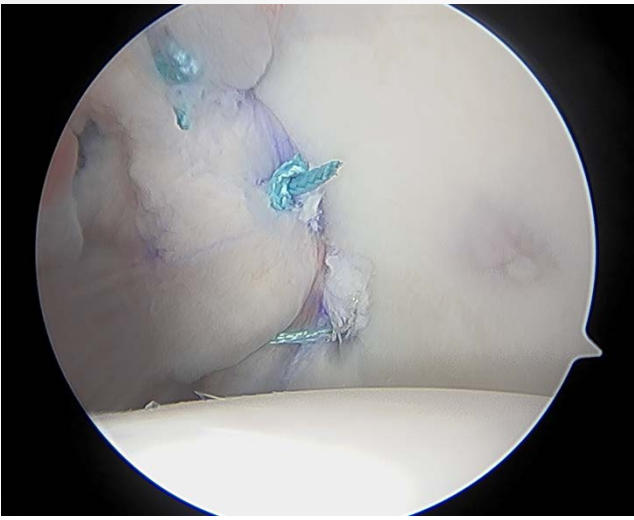
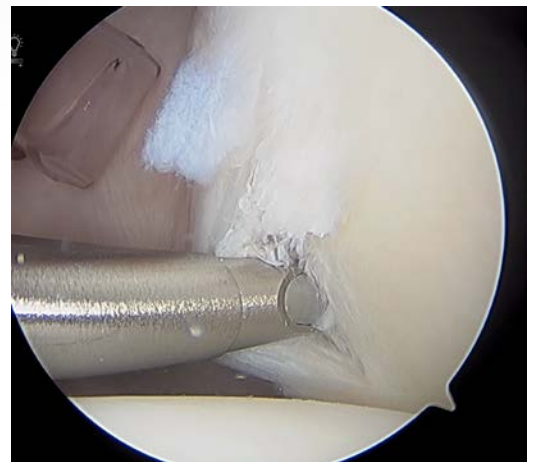
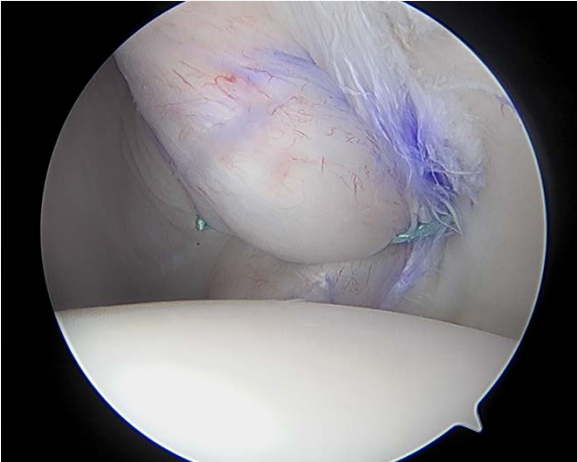
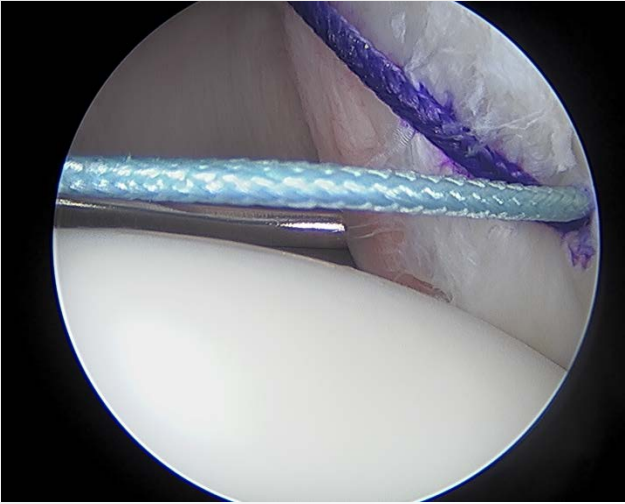
Mind your angle
*subscap *nerve



Treatment: "How I Do It"



Treatment: "How I Do It"



Summary

- Let pain be your guide
- Don't expect "instability"
- Modern day techniques work well
- Don't forget alphabet soup
 - RHAGL
 - POLPSA
 - Reverse bony Bankart
 - Chondrolabral erosion



END



Thank you!
Questions / Comments

