

## Patella Fracture



---

---

---

---

---

---

---

## 57 YO Female

- Snowmobile accident
- Grade 2 open distal femur
- Ipsilateral segmental tibia
- Antibiotics, I+D, ex fix



---

---

---

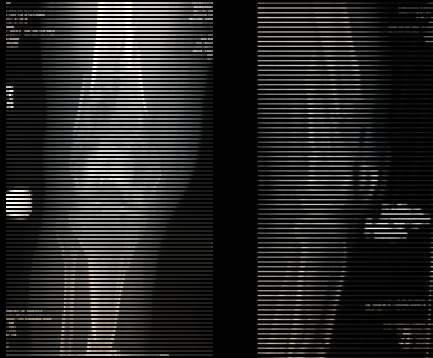
---

---

---

---

## Distal Femur



---

---

---

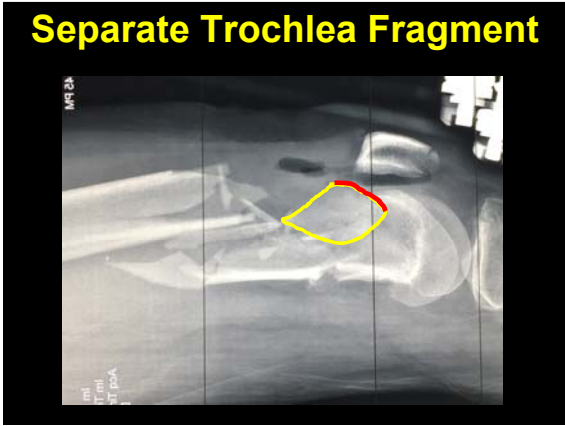
---

---

---

---

### Separate Trochlea Fragment



---

---

---

---

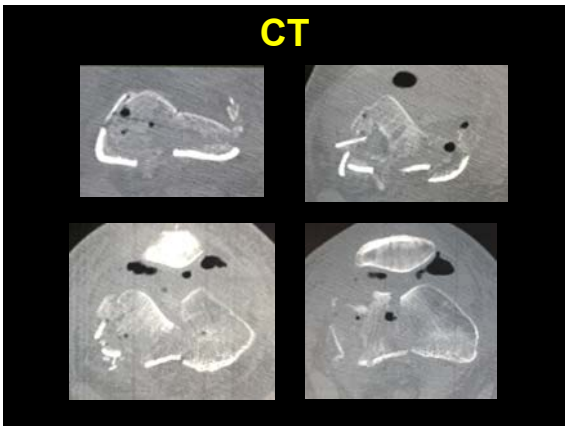
---

---

---

---

### CT



---

---

---

---


---

---

---

---

### Oh, and....



---

---

---

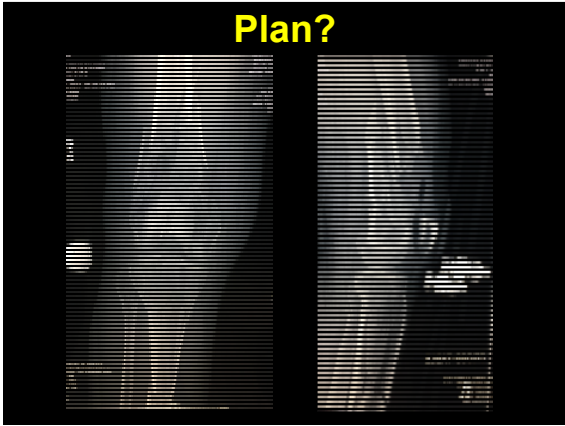
---

---

---

---

---



---

---

---

---

---

---

---

---



---

---

---

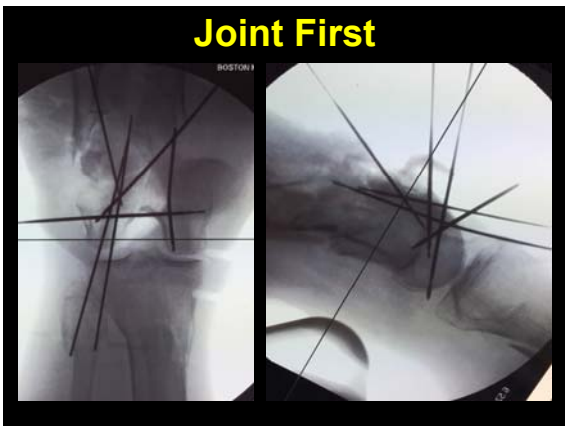
---

---

---

---

---



---

---

---

---

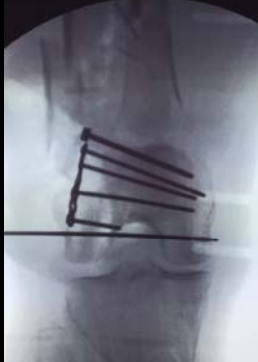---

---

---

---

### Joint Fixation



---

---

---

---


---

---

---

---

### Temp Fixation



---

---

---

---


---

---

---

---

### Bend Plate to Fit



---

---

---

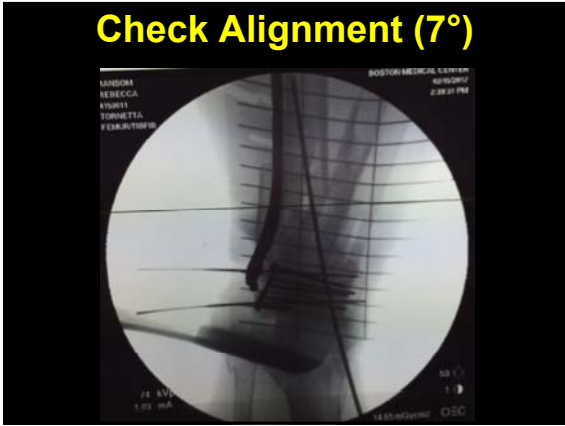
---

---

---

---

---



---

---

---

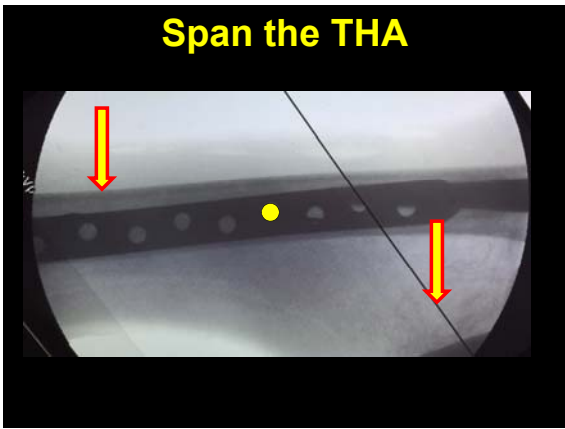
---

---

---

---

---



---

---

---


---

---

---

---

---



---

---

---

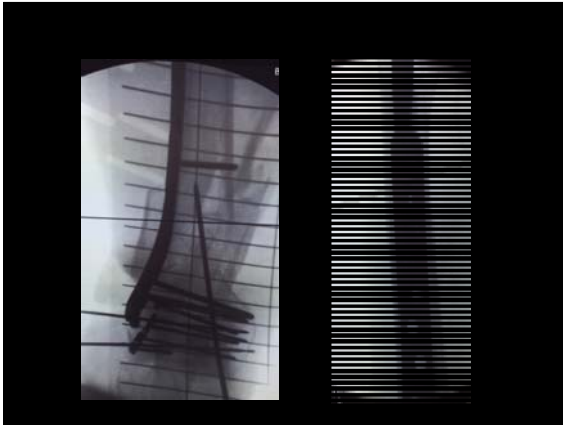
---

---

---

---

---



---

---

---

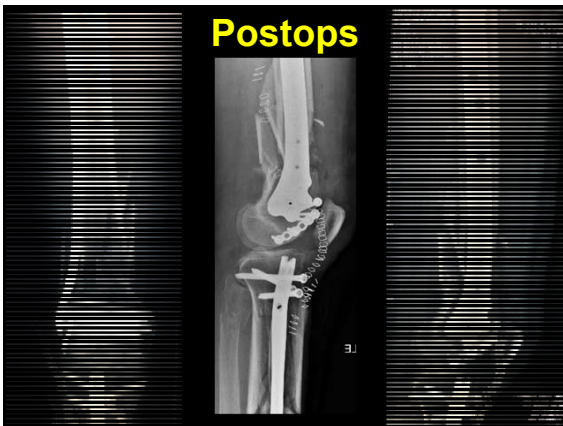
---

---

---

---

---



---

---

---

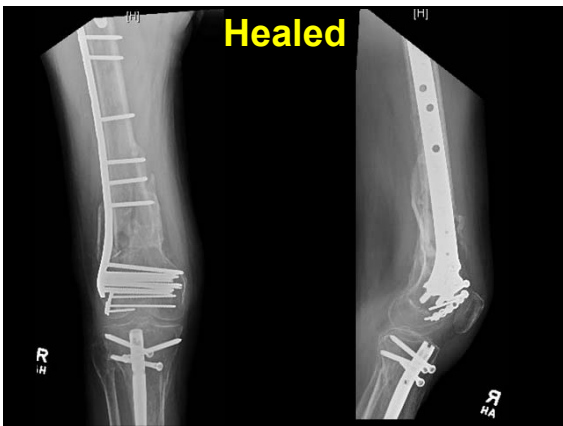
---

---

---

---

---



---

---

---

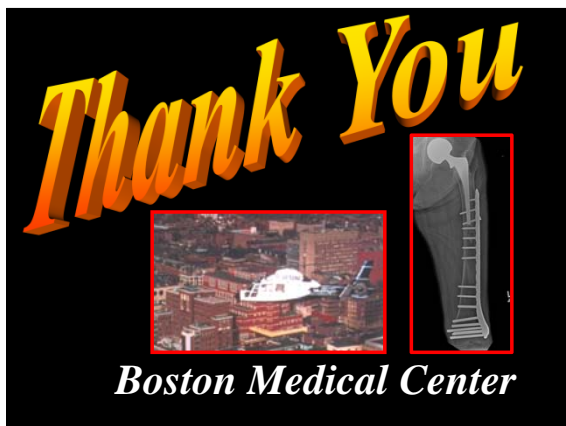---

---

---

---

---



---

---

---

---

---

---

---

---