

30<sup>th</sup> Annual Trauma Update 2018

## The VAC Sponge – Where It Works & Where It Doesn't

R. Kumar Kadiyala MD, PhD  
Columbia University Medical Center  
Dept. of Orthopedic Surgery

NewYork-Presbyterian Columbia University Department of Orthopedic Surgery College of Physicians & Surgeons

---

---

---

---

---

---

---

---

---

---

### Wonders of the VAC (NPWT)

**V.A.C.® Therapy Creates an Environment that Promotes Wound Healing**

The application of uniform negative pressure delivered by V.A.C.® Therapy induces a physical response (Macrostrain) and a biological response (Microstrain). Macrostrain draws wound edges together, removes exudate and infectious material, reduces edema, and promotes perfusion. Microstrain creates tissue microdeformation, causing cells to stretch. Cell stretch leads to cell migration and proliferation that result in the formation of granulation tissue.

1) Draws wound edges together  
2) Removes exudate/infectious material  
3) Reduces edema  
4) Promotes perfusion

4) In vitro studies show that cell stretch under negative pressure stimulates cellular activity in the wound. In granulation tissue formation.

5) In vitro also studies show that cells that have been exposed to negative pressure experience tissue microdeformation that leads to cell proliferation.

© 2013 KCI Licensing, Inc. All rights reserved. OSL#13-0205 (4/13)

NewYork-Presbyterian Columbia University Medical Center Department of Orthopedic Surgery

---

---

---

---

---

---

---

---

---

---

### 52 y.o. Male Presents to Our ER

6 weeks prior sustained a Grade II open proximal tibia fracture

Underwent initial debridement and application of spanning Ex-Fix

Two weeks later definitive fixation with dual plating

By report, did not FU as requested, did not adhere to weight-precautions

NewYork-Presbyterian Columbia University Medical Center Department of Orthopedic Surgery

---

---

---

---

---

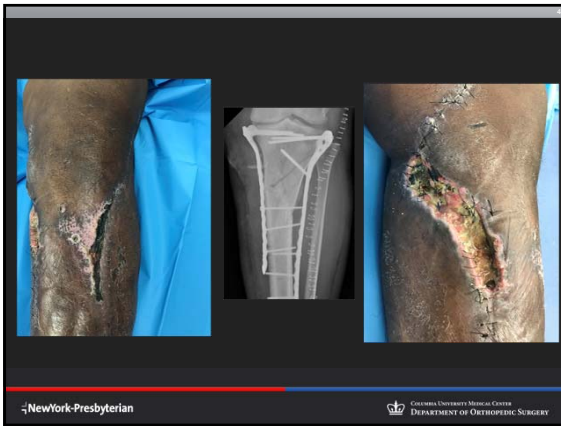---

---

---

---

---



---

---

---

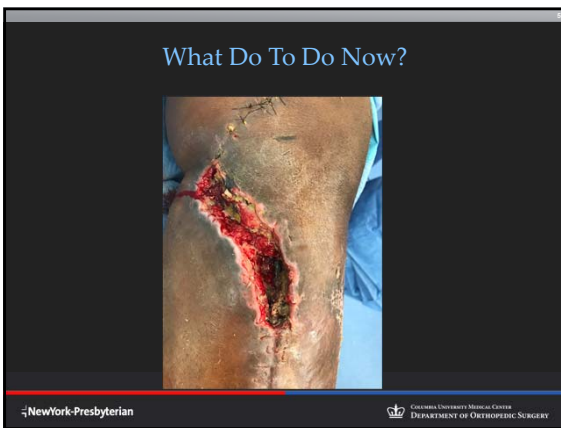---

---

---

---

---



---

---

---

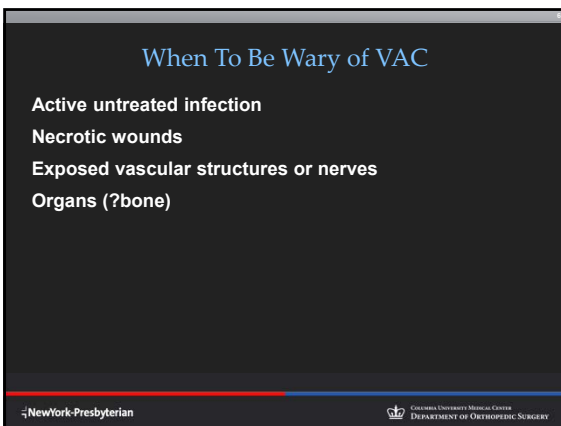
---

---

---

---

---



---

---

---

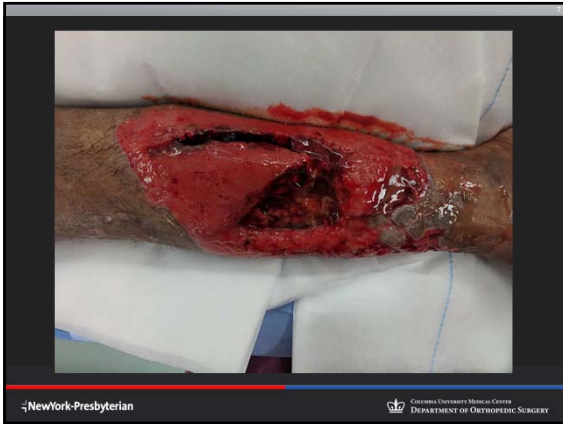---

---

---

---

---



---

---

---

---

---

---

---

---

**Hospital Course**

- 6 debridements Initial Wet to Dry dressings with medial plate removal after thorough debridement
- Subsequent antibiotic bead pouch
- 4 additional debridements with VAC and removal of lateral plate
- Combined medial plate application and medial gastroc flap
- Skin graft

NewYork-Presbyterian Columbia University Medical Center DEPARTMENT OF ORTHOPEDIC SURGERY

---

---

---

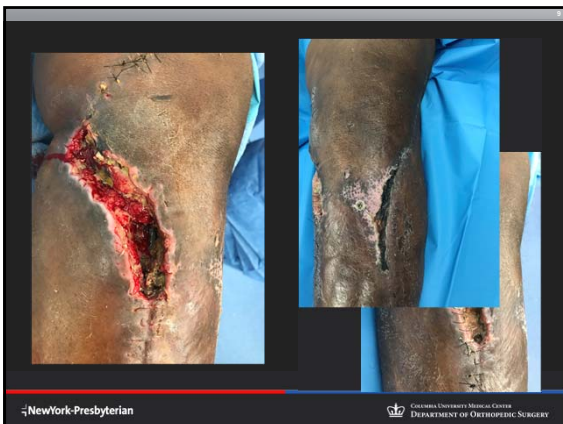---

---

---

---

---



---

---

---

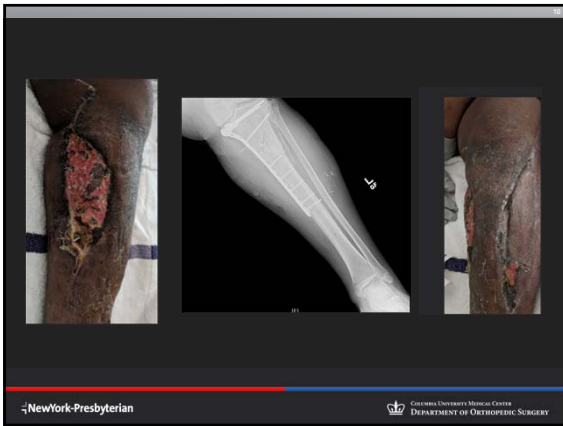---

---

---

---

---



---

---

---

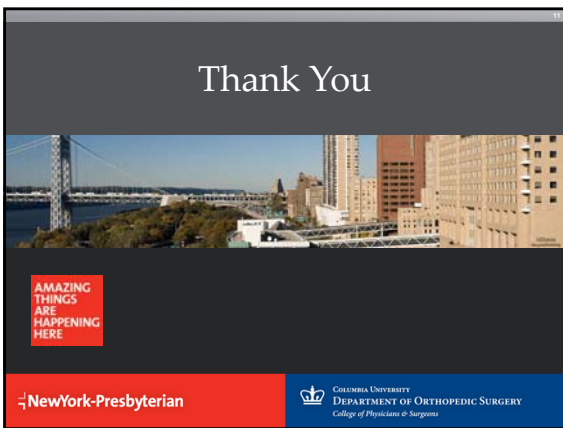
---

---

---

---

---



---

---

---

---

---

---

---

---