



Infected Non-Union Of The Femur Current Concepts



Donald Wiss MD Cedars-Sinai Medical Center Los Angeles
California


Infected Non-Union Of The Femur Introduction

- Uncommon Condition (Compared To Tibia)
- Difficult To Successfully Treat
- Patient Morbidity High
- Treatment Often Prolonged
- Functional Impairment Common




Infected Non-Union Of The Femur Goals In Treatment

- Eradicate Infection
- Restore Length & Alignment
- Fracture Healing
- Functional Rehabilitation




Infected Non-Union Of The Femur Risk Factors

- Open Fractures
- Prior Surgery
- Other Known Risk Factors
 - Obesity
 - Smoking
 - Diabetes
 - Meds
- Psycho-Social Issues




Infected Non-Union Of The Femur Diagnosis

- Broad Range Of Presentation
 - Subtle
 - Obvious
- CBC, ESR, CRP
- Nuclear Medicine Studies
- Positive Culture



Infected Non-Union Of The Femur Treatment Options

- Antibiotic Nail
- Bead Pouch / Spacer / Masquelet
- External Fixation
- Fine Wire Circular Ring Fixation
- Amputation

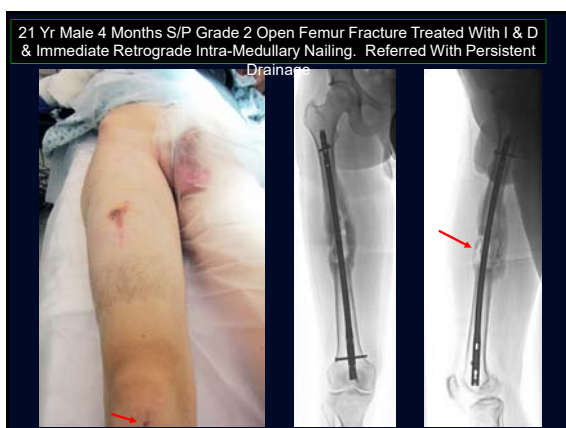

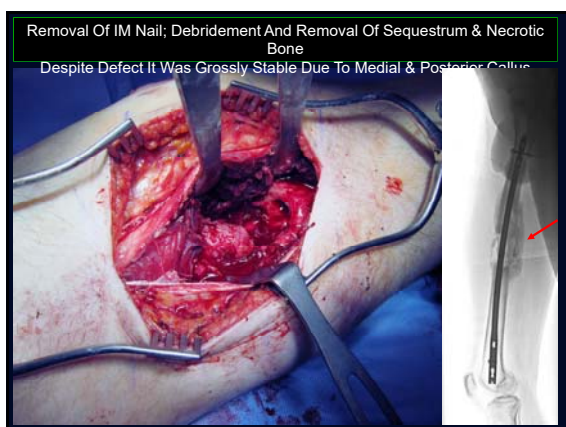3 Illustrative Cases

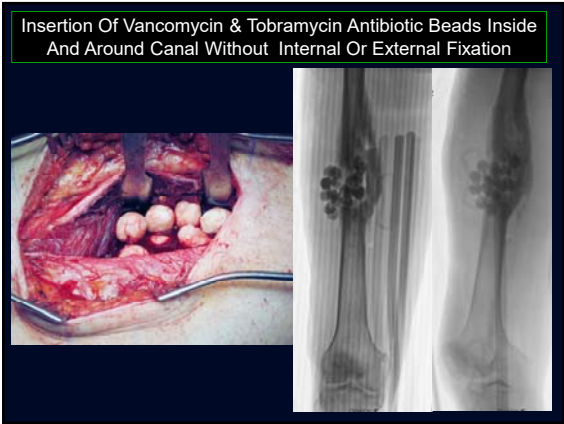Straightforward

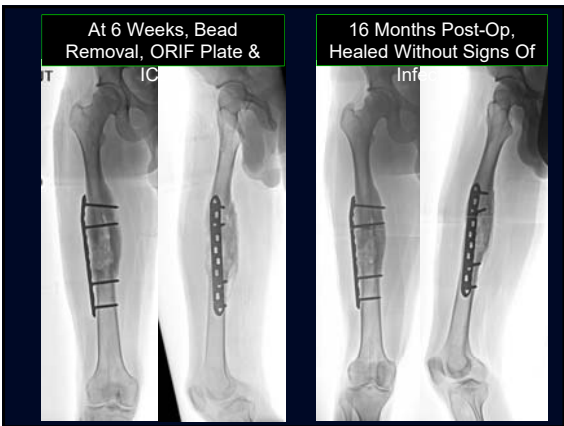Intermediate

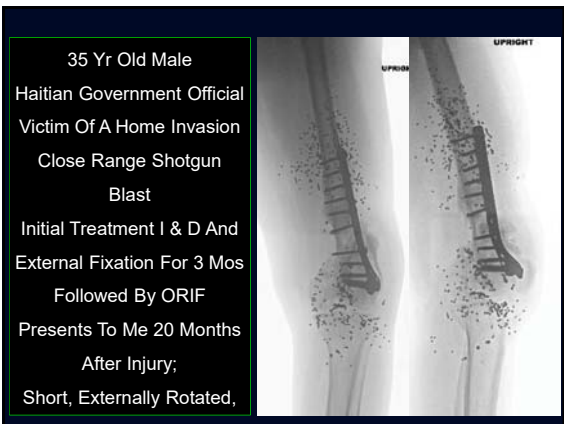Chronic

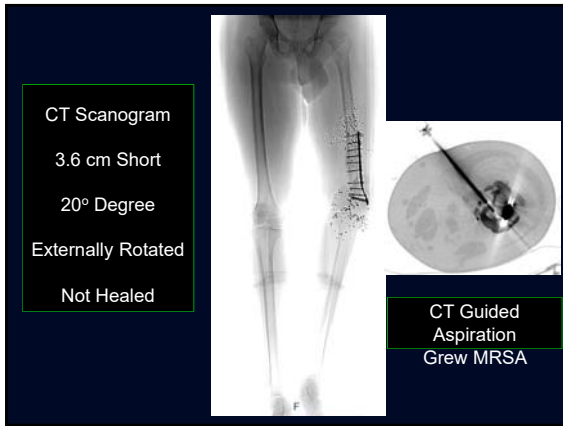


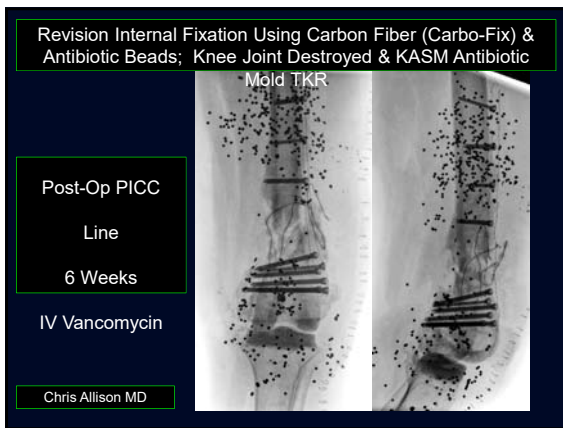


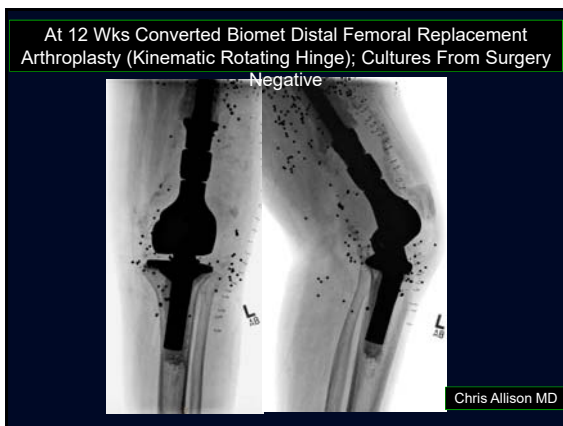




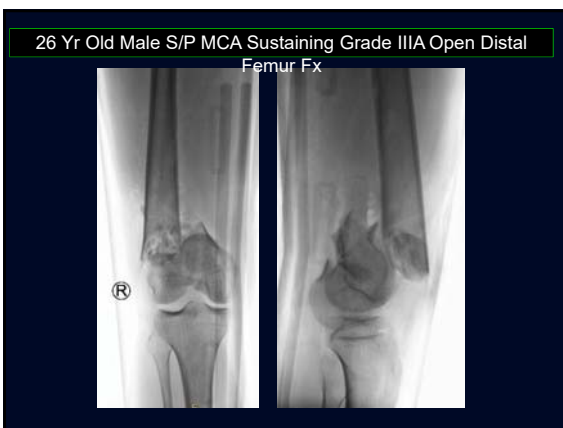


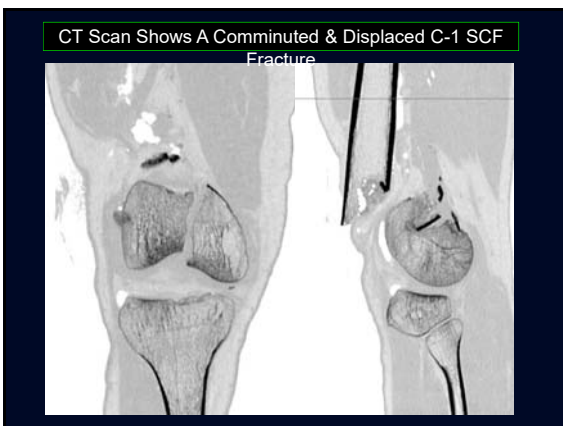


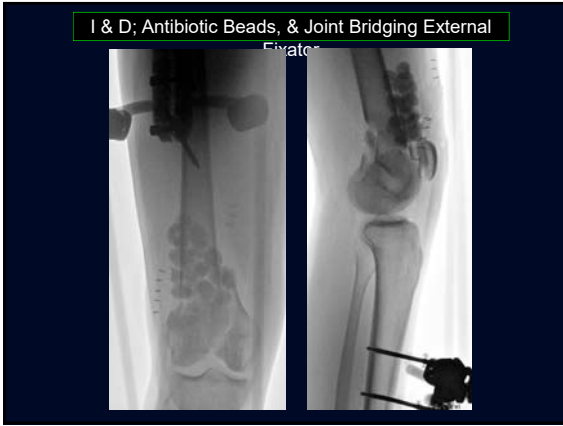

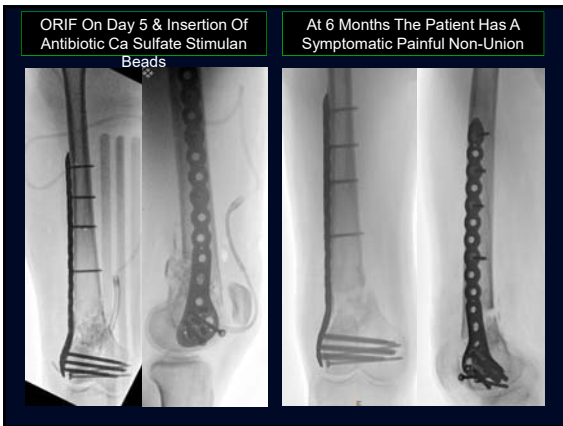



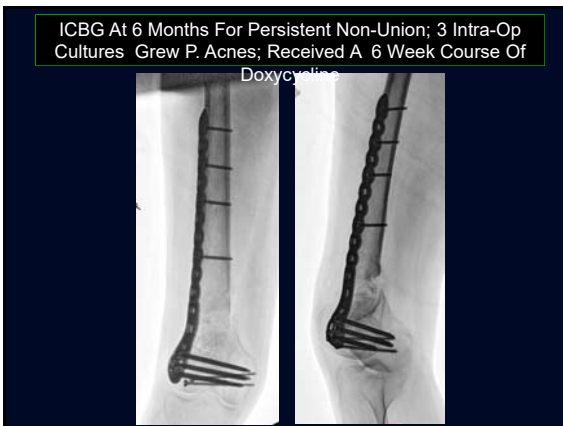
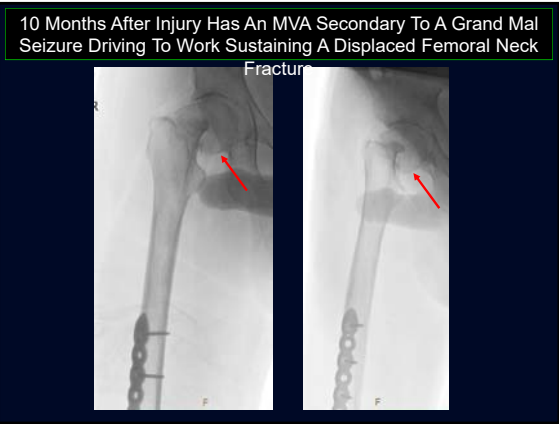


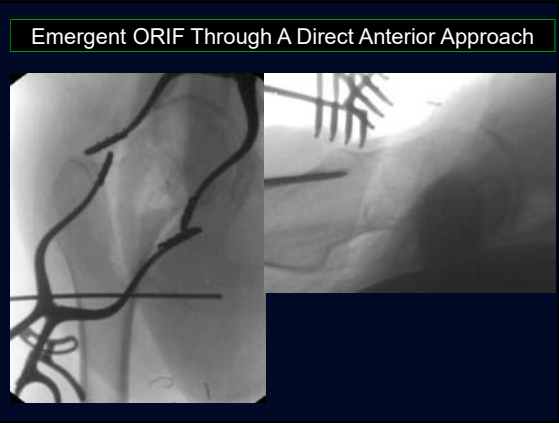




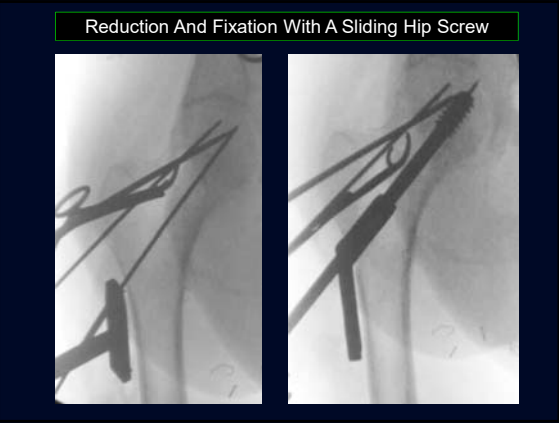




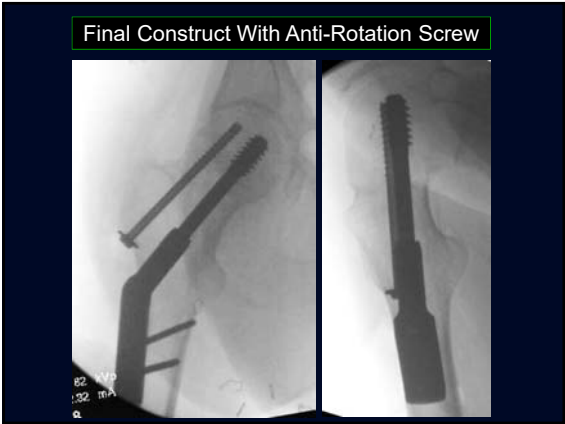




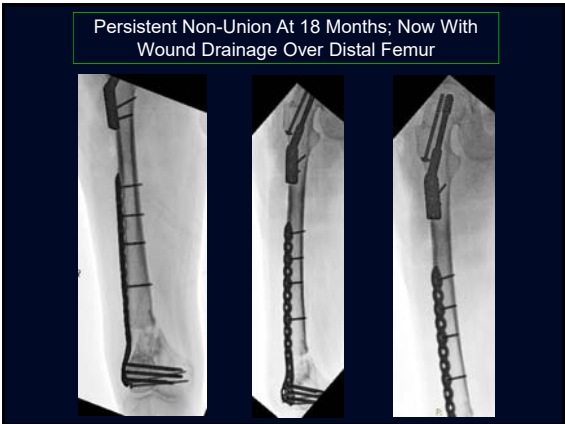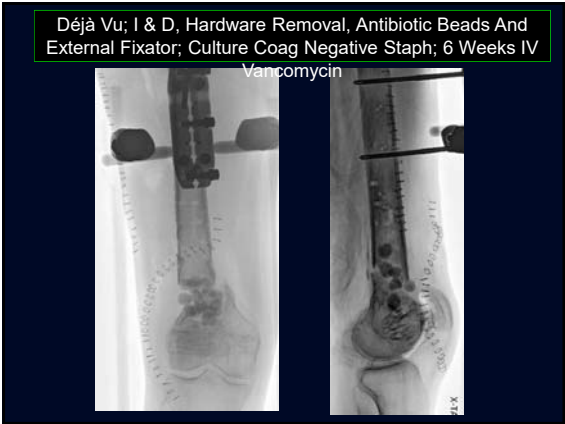Final Construct With Anti-Rotation Screw



Persistent Non-Union At 18 Months; Now With Wound Drainage Over Distal Femur




Déjà Vu; I & D, Hardware Removal, Antibiotic Beads And External Fixator; Culture Coag Negative Staph; 6 Weeks IV Vancomycin



2 More I & D's, Bead Exchange; And Then Acute Shortening And Fixation With A 95° AO Blade Plate

Bone Loss Forced
Blade Insertion More Distal
A Bit Too Long



Latest Follow-Up Fracture Healed
ROM Knee 0°-35°; 3 cm Short
No Clinical Sign Of Infection

10 Procedures Total

- I & D's x 5
- External Fixation x 2
- ORIF Femur x 3
- ORIF Hip
- Bone Graft x 2 (ICBG & RIA)



Infected Non-Union Femur Conclusions

- Challenging Clinical Problem
- Significant Patient Morbidity
- Results Unpredictable
- Drain On Health Care Resources