

A Tale of Two Cities
30th Annual Trauma Update, New York, NY

Iliac Crest Bone Graft: The Gold Standard

J. Turner Vosseller, MD
Assistant Professor
Department of Orthopaedic Surgery
Columbia University Medical Center

NewYork-Presbyterian

COLUMBIA UNIVERSITY
DEPARTMENT OF ORTHOPEDIC SURGERY
College of Physicians & Surgeons

Graft Properties

- Osteoconductive
 - Graft acts as a scaffold onto which the host bone grows



NewYork-Presbyterian

COLUMBIA UNIVERSITY
DEPARTMENT OF ORTHOPEDIC SURGERY

Graft Properties


- Osteoinductive
 - Graft induces the host cells to commence laying down new bone through mediators
- Osteogenic
 - Graft directly provides cells that will produce bone including primitive mesenchymal stem cells, osteoblasts, and osteocytes

NewYork-Presbyterian

COLUMBIA UNIVERSITY
DEPARTMENT OF ORTHOPEDIC SURGERY

Graft Properties

- Cortical
 - Osteoconductive, minimally osteoinductive and osteogenic
 - Best suited for structural defects



NewYork-Presbyterian Columbia University DEPARTMENT OF ORTHOPEDIC SURGERY


Graft Properties

- Cancellous
 - Osteoconductive, osteoinductive, osteogenic
 - Most commonly used source of autogenous graft
 - Rapid incorporation; no immediate structural stability
- Cortical-cancellous
 - Combines the best of both above; iliac crest most common donor site

NewYork-Presbyterian Columbia University DEPARTMENT OF ORTHOPEDIC SURGERY

Overview of bone healing

- Bone graft incorporates via five stages:
 - Inflammation
 - Vascularization
 - Osteoinduction
 - Osteoconduction
 - Remodeling




NewYork-Presbyterian Columbia University DEPARTMENT OF ORTHOPEDIC SURGERY

Slide 6

- MOU1** Influx of infl cells in the first week followed by granulation tissue by the second week
Microsoft Office User, 5/2/2018
- MOU2** Vasc and OI occur together; vasc allows for influx of osteoprogenitor cells
Microsoft Office User, 5/2/2018
- MOU3** OC happens when the graft acts as a structural hub onto which the host grows bone. Once it's there, then it remodels
Microsoft Office User, 5/2/2018

ICBG




- The Gold Standard
- Advantages
 - Provides the most flexibility in terms of autograft options
 - Can provide a large volume of graft material
 - ❖ Graft volume generally from 15 to 30 cm³

NewYork-Presbyterian Columbia University DEPARTMENT OF ORTHOPEDIC SURGERY



ICBG

- Disadvantages
 - Infection and deep hematoma most common
 - Persistent donor site pain has been commonly cited



NewYork-Presbyterian Columbia University DEPARTMENT OF ORTHOPEDIC SURGERY

ICBG



- Many of the studies of the complications of ICBG come from the spine literature
- Carragee et al
 - Scathing editorial
 - Cited weaknesses of ICBG studies:
 - ❖ Unvalidated donor site pain assessment

NewYork-Presbyterian Columbia University DEPARTMENT OF ORTHOPEDIC SURGERY

ICBG

- Carragee et al.
 - RCTs (three FDA-regulated, randomized, non-blinded IDE trials for rhBMP-2 and one for OP-1 approval, all versus ICBG)
 - ❖ No increase in pain scores or functional disability in those patients that received ICBG
 - Further, many of the spine studies do a poor job of differentiating spine-related pain from graft site pain

– NewYork-Presbyterian COLUMBIA UNIVERSITY DEPARTMENT OF ORTHOPEDIC SURGERY

What about BMAC?

- Gianakos et al
 - Meta-analysis of 35 studies
 - ❖ 100% showed increase in bone formation with BMAC
 - ❖ 90% significant improvement in bone healing on histologic/histomorphometric assessment
 - ❖ 81% significant increase in bone area on micro-CT

– NewYork-Presbyterian COLUMBIA UNIVERSITY DEPARTMENT OF ORTHOPEDIC SURGERY

Case #1

- 68 year old male comes in 4 weeks out from 5th metatarsal fracture for second opinion. Had been struggling with WBAT in post-op shoe.



– NewYork-Presbyterian COLUMBIA UNIVERSITY DEPARTMENT OF ORTHOPEDIC SURGERY

Case #1

- Still having pain at three months



NewYork-Presbyterian Columbia University DEPARTMENT OF ORTHOPEDIC SURGERY

Case #1

- Somewhat better at 6 months, but still has pain



NewYork-Presbyterian Columbia University DEPARTMENT OF ORTHOPEDIC SURGERY

Case #1


- Still has limiting pain at 9 months; wants something more aggressive but not invasive



NewYork-Presbyterian Columbia University DEPARTMENT OF ORTHOPEDIC SURGERY

Case #1

- BMAC injection was performed at 11 months from the original injury
- Three months later:



NewYork-Presbyterian Columbia University DEPARTMENT OF ORTHOPEDIC SURGERY

Case #1

- No pain at final follow up:



NewYork-Presbyterian Columbia University DEPARTMENT OF ORTHOPEDIC SURGERY

Case #2

- 55 year old female accosted by paranoid-schizophrenic nephew (i.e. "I'm going to kill you), and so she jumped out a 3rd story window
- This happened about six months prior to coming to me

NewYork-Presbyterian Columbia University DEPARTMENT OF ORTHOPEDIC SURGERY

Case #2

- Bilateral calc fx's
 - L side was an open fx
 - Washed out at OSH
 - Open wound healed, no apparent infxn
 - No attempt at ORIF
 - Has been more or less NWB in a wheelchair for six months

NewYork-Presbyterian COLUMBIA UNIVERSITY DEPARTMENT OF ORTHOPEDIC SURGERY

Case #2


• L foot



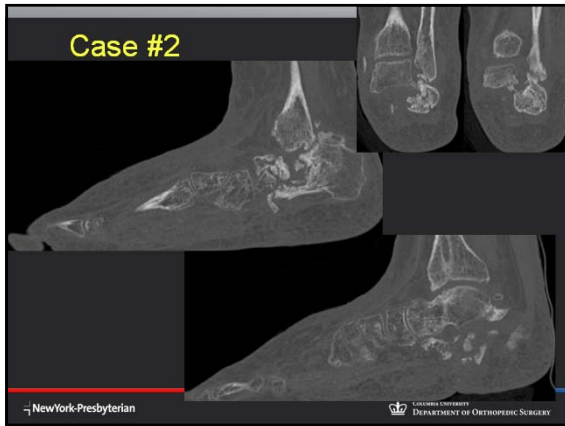NewYork-Presbyterian COLUMBIA UNIVERSITY DEPARTMENT OF ORTHOPEDIC SURGERY

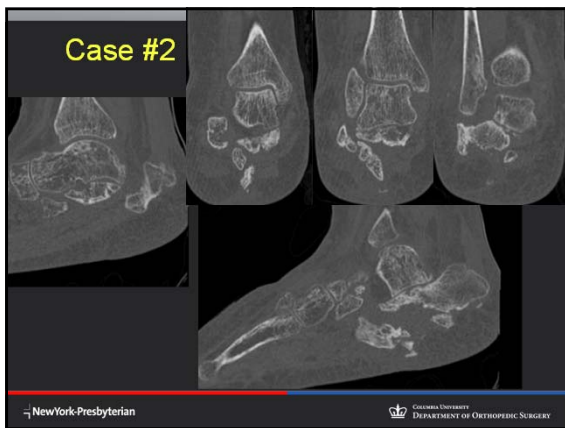Case #2

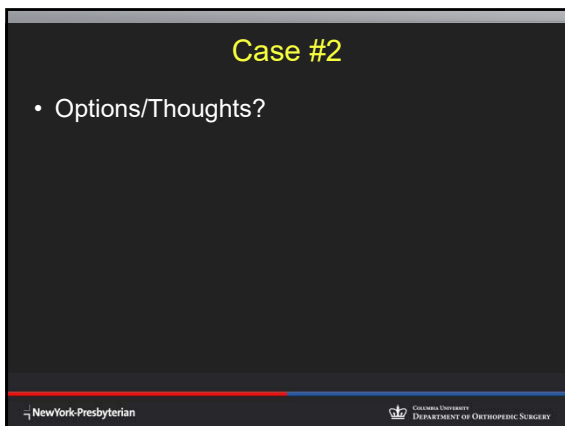
• R foot



NewYork-Presbyterian COLUMBIA UNIVERSITY DEPARTMENT OF ORTHOPEDIC SURGERY







Case #2

- Plan
 - Staged (R, then L)
 - Open Achilles Z-lengthening
 - Distraction bone block arthrodesis
 - ❖ Femoral head allograft
 - ❖ BMAC

NewYork-Presbyterian Columbia University DEPARTMENT OF ORTHOPEDIC SURGERY

Case #2

NewYork-Presbyterian

Case #2

NewYork-Presbyterian Columbia University DEPARTMENT OF ORTHOPEDIC SURGERY

Case #3

- 72 year old male with right foot pain and deformity. Unclear story; distant foot trauma, presents with foot pain/deformity.



The image shows three X-ray views of a right foot: two dorsal views and one lateral view. The bones appear somewhat irregular, consistent with the text's mention of 'distant foot trauma'. The text 'ERECT' is visible on the X-rays.

NewYork-Presbyterian Columbia University DEPARTMENT OF ORTHOPEDIC SURGERY

Case #3

- Difficulty palpating DP pulse distally
- Recent h/o CABG
- h/o alcohol induced neuropathy, TIAs
- Cleared by
 - PCP
 - Cardiology
 - Vascular surgery
 - Neurology

NewYork-Presbyterian Columbia University DEPARTMENT OF ORTHOPEDIC SURGERY

Case #3




The image shows two X-ray views of a foot after surgery. The dorsal view on the left shows a large metal plate and several screws across the midfoot. The lateral view on the right shows the same hardware from a different angle. The text 'PORTABLE CROSS-TABLE' is visible on the right side of the image.

NewYork-Presbyterian Columbia University DEPARTMENT OF ORTHOPEDIC SURGERY

Case #3

- Grossly noncompliant; WB at 2-3 weeks
- X-rays show early failure at 6 weeks



NewYork-Presbyterian Columbia University DEPARTMENT OF ORTHOPEDIC SURGERY

Case #3

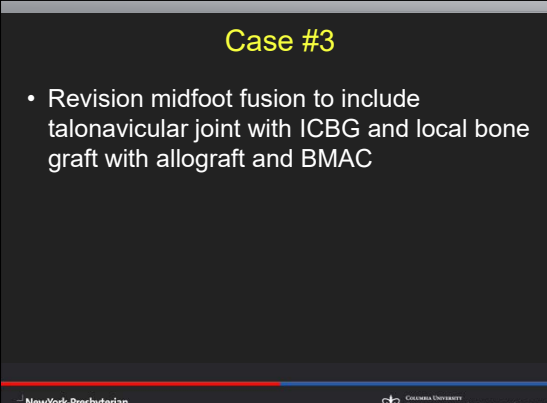
- 6 months
- Failed midfoot fusion



NewYork-Presbyterian THORPEIC SURGERY

Case #3

- Revision midfoot fusion to include talonavicular joint with ICBG and local bone graft with allograft and BMAC



NewYork-Presbyterian Columbia University DEPARTMENT OF ORTHOPEDIC SURGERY



