


**Stemless Shoulder Arthroplasty,**  
*Debate stemless versus stem*  
**Shoulder Course Tampa**

**Frank Gohlke**



Upper Limb Reconstruction Center – Bad Neustadt / Saale

---

---

---


---

---

---


---

---

**Disclosure** 

The author (F.G.) has no conflict of interest

- consultant for Wright/Tornier
- involved the development of a revision system of Wright – without accepting royalties
- receives no royalties from any manufacturer related to this subject



---

---

---


---

---

---


---

---

**Do we need stems ?**  
 - Potential disadvantages - 

**Possible complications**

- Risk of intraoperative humeral fracture
- humeral periprosthetic fractures
- stress shielding, bone loss
- Difficult to revise in case of
  - infections
  - instability
  - rotator cuff insufficiency
  - glenoid loosening



**Revisions for isolated complications of the shaft: 1,1 % (Bohsali, JBJS 2006, Desmukh, JSES 2005)**

---

---

---

---

---

---

---

---

### Stem sparing humeral components

- Make revision easier, for complications on both sides, humeral and glenoid side:
  - ✓ infections
  - ✓ periprosthetic fractures
  - ✓ conversion to RSA in case of glenoid loosening, glenoid erosion, and instability .....

**Clear trend to bone preseving implants !**

---

---

---

---

---

---

---

---

### Release of „stemless“ anatomical humeral components

„TESS“ → „Nano“ (2004, 2012 Biomet)		
„Eclipse“ (2005, Arthrex)		
„Affinis Short“ (2009, Mathys)		
„Simpliciti“ (2010, Tornier) Release USA 2015		
Sidus Short, (2012, Zimmer)		

---

---

---

---

---

---

---

---

### Stemless SR: Restores anatomy ?

**Pre-/post-OP geometry**

- Prospective study of n=70 TESS
- “the critical step is to determine the correct level of bone cut to avoid varus or valgus humeral head inclination and ensure correct head size”
- Tendency to increase of lateral offset

*Kadum et al. 2015*

**Standardized technique (intramedullary adjustment may be used)**

*Kadum et al. (2015 and 2016): Int Orthop*

---

---

---

---

---

---

---


---



### Eclipse (Arthrex) personal experience 2006-2011

**Main indication**

- Extra-articular posttraumatic deformity
- Fracture sequelae in need of osteotomy for implantation of a stem
- **Cage screw design of metal backed glenoid component 2008 abandoned**



Posttraumatic malunion: OP in 2007, revision in 2012 because of glenoid loosening

RHÖN KLINIKUM  
KLINIK FÜR ORTHOPÄDIE

---

---

---

---

---

---

---

---

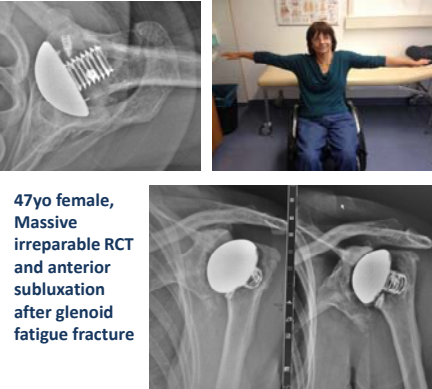
---

---

### Long-term results of Eclipse ?

**Excessive loads**

- Traumatic syringomyelia with anteroinferior glenoid fatigue fracture and advanced wear
- **Weightbearing shoulder**
- **11 years post-OP**
- Still painfree, graft (humeral head) and glenoid healed



47yo female, Massive irreparable RCT and anterior subluxation after glenoid fatigue fracture

---

---

---

---

---

---

---

---

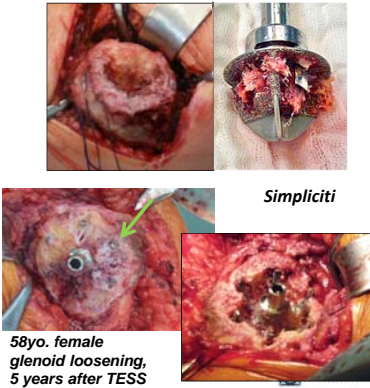
---

---

### Stemless humeral implants personal experience with revisions

**TESS, Simpliciti, Eclipse .....**

- Bone ingrowth in all, but design related difference
- Metaphyseal bone stock still available for possible glenoid reconstruction in TSA
- Tuberosities could be preserved, no fractures or cracks
- Mostly converted to short stem RSA



**Simpliciti**

58yo. female glenoid loosening, 5 years after TESS

---

---

---

---

---

---

---

---


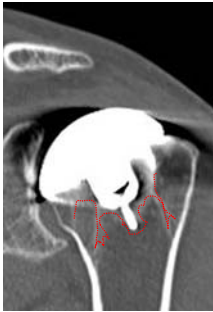
---

---

### Bone ingrowth and remodelling?

**Current analysis of 156 Simpliciti prospectively followed up, OP 2011-2013 (FU > 4 years)**

- 4 centers:
  - Bad Neustadt / FG
  - Würzburg / DB
  - Hausham / UB
  - Osnabrück / BW
- No Loosening: migration / tilt
- **Bone remodelling or resorption related to force distribution**

2 years after Hemi in 32yo male, instability arthropathy, still pain by glenoid erosion, implant in valgus position, see trabeculae in CT scan after 6 months but not in X-ray!

---

---

---

---

---

---

---

---

---



---

### Short stem: „Salvage procedure“ for stemless



- saving time for long-term survival -

**As short as possible, and convertible to reverse SA ?**

- Stemless SA provides bonestock for further revisions!

**Failed stemless SA can successfully be converted to a short stem platform system**

Glenoid erosion and subscapularis insufficiency:  
Revision to cementless short stem RSA with onlay-tray

---

---

---

---

---

---

---

---

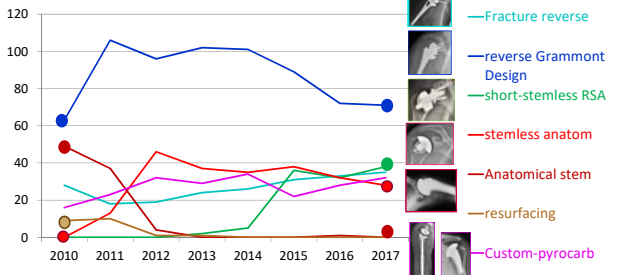
---

---

### Shoulder Arthroplasty – varia?

- personal series -

**8 different designs (2010-2017\*): n=1488**



- Fracture reverse
- reverse Grammont Design
- short-stemless RSA
- stemless anatom
- Anatomical stem
- resurfacing
- Custom-pyrocarb

**Since 2012 no standard stemmed anatomical TSA needed!**

---

---

---

---

---

---

---

---

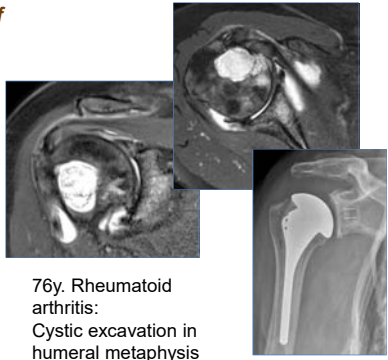
---

---

### Stemless arthroplasty - Limits -


**Advanced bone loss of proximal humerus**

- Fractures
- Non-union
- Advanced cystic deformation
- Severe osteoporosis
- AHN with metaphyseal collapse



76y. Rheumatoid arthritis:  
Cystic excavation in humeral metaphysis

**stem should always be kept in the background**




---

---

---

---

---

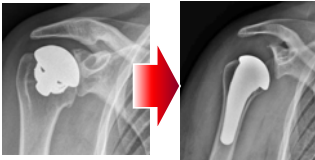
---

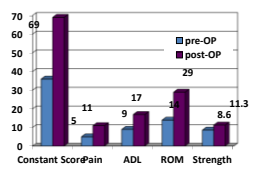
---

---

### German multicenter study 2015

780 cases, > 2 years / 103 cases > 5 years






Parameter	pre-OP	post-OP
Constant Score	38	69
Pain	5	11
ADL	9	17
ROM	14	29
Strength	8.6	11.3

**Late complications (0.6%)**

- ◆ Aseptic humeral loosening 2
- ◆ Glenoid loosening 4
- ◆ nerve lesion 1
- ◆ rotator cuff failure 10

**Clinical results stable over 5 years!**




---

---

---

---

---

---

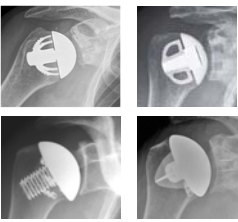
---

---

### Conclusion


**Stemless (anatomical) SA:**

- Low complication rate
- Low revision rate (mostly related to metal backed glenoid and RC insufficiency)
- implant-related problems of humeral components uncommon



**Comparable results to 3<sup>rd</sup>. generation stemmed humeral anatomic components !**

*Hawi et al. (2016): Anatomic stemless shoulder arthroplasty and related outcomes: a systematic review. BMC Musculoskelet Disord. 17(1):376*




---

---

---

---

---

---

---

---

Over 50 years proud stems .....



*It's only canal-sparing fixation ...  
..... but I like it!*



The „Rolling Stones“:  
Mick Jagger and Keith  
Richards 1968 and 2018



---

---

---

---

---

---

---

---