

ROTHMAN
INSTITUTE

Sidney Kimmel
Medical College
at Thomas Jefferson University

B2 Glenoid

Augment **VS** Reverse

Joseph A. Abboud, M.D.
Professor of Shoulder and Elbow Surgery
Senior Vice President, Rothman Institute

Tampa Shoulder Course
February 2nd, 2018

Disclosures

• Joseph A. Abboud, MD

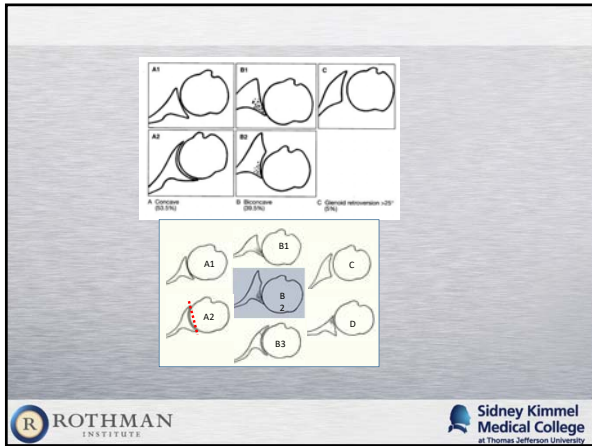
- Depuy Synthes - Research Support
- Zimmer - Research support
- Tornier - Research Support, Paid Speaker
- Arthrex - Research Support
- OREF - Research support
- Wolters Kluwer Health - Lippincott Williams & Wilkins - Royalties
- Integra - Royalties, Research Support
- DJO - Royalties
- Cayenne - Royalties
- Minimvasive - Scientific Advisory Board
- OrthoSpace - Research support
- Aevumed - Stock
- Mid Atlantic Shoulder and Elbow Society - Board of Directors
- Globus - Royalties
- Parvizi Surgical Innovation - Stock
- Shoulder JAM LLC - Co-Founder
- OBERD
- Marlin Medical Alliance, LLC

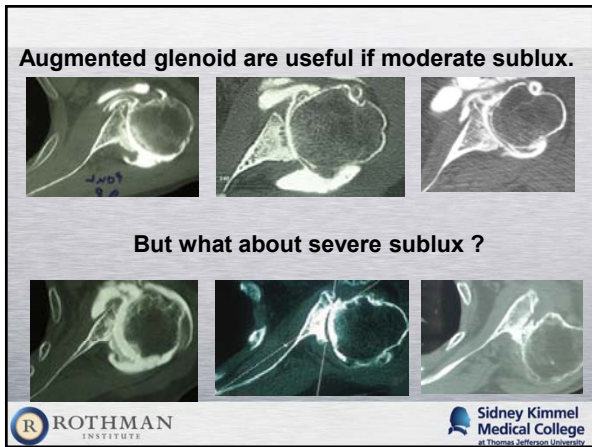
ROTHMAN INSTITUTE

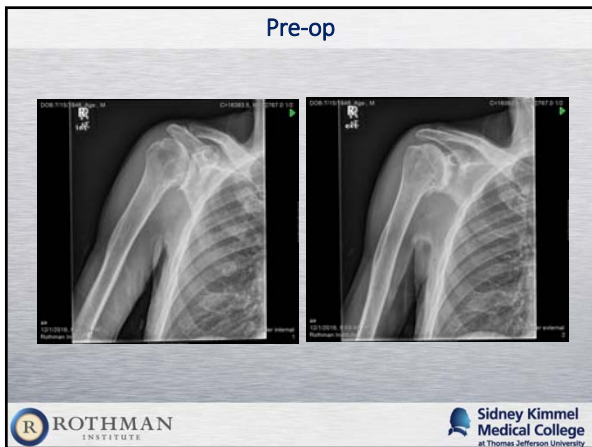
Sidney Kimmel
Medical College
at Thomas Jefferson University

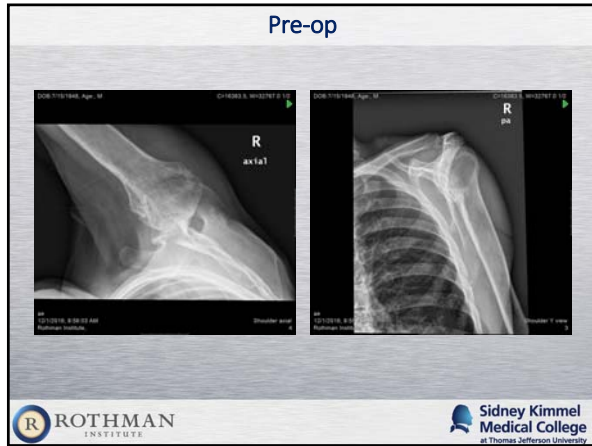
Lines and Angles

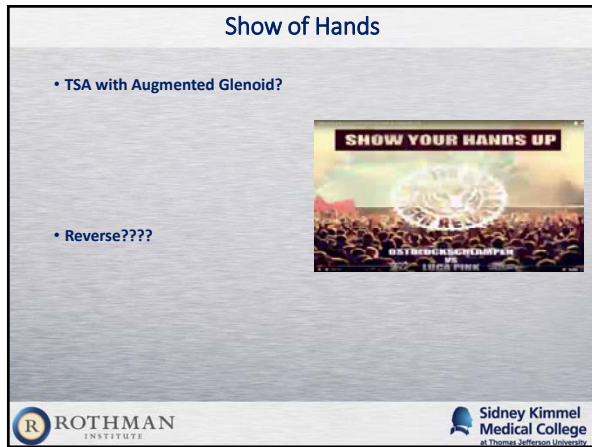
- Line ED - Friedman Line from medial scapular tip to center of glenoid
- Line AB - Native (paleo) glenoid
- Angle between ED and AB is native glenoid angle
- Line AC - Intermediate glenoid
- Line BC - Neoglenoid

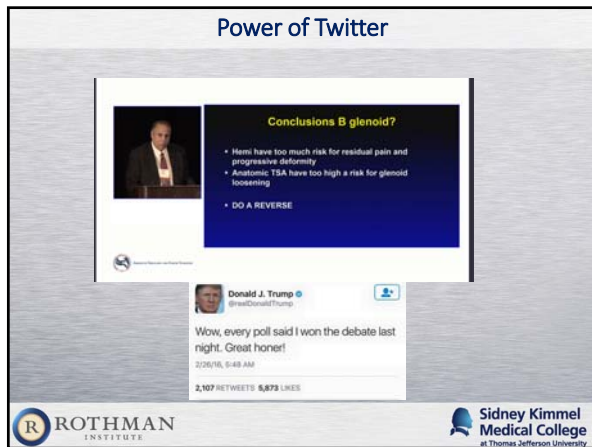




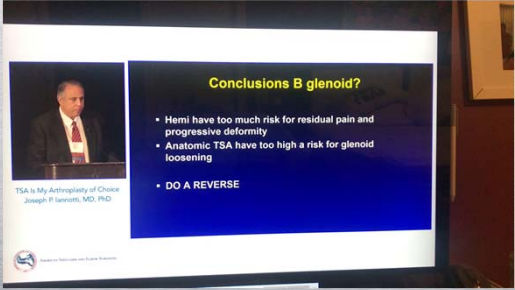








I love Sound Bytes




TSA is My Arthroplasty of Choice
Joseph P. Iannotti, MD, PhD

- Hemi have too much risk for residual pain and progressive deformity
- Anatomic TSA have too high a risk for glenoid loosening
- DO A REVERSE

ROTHMAN INSTITUTE Sidney Kimmel Medical College at Thomas Jefferson University


Why Does Dr. Iannotti Say That?



ROTHMAN INSTITUTE Sidney Kimmel Medical College at Thomas Jefferson University

What is the weak link in TSA: Augmented or Not? The Glenoid

- Cement and Glenoid Loosening
 - Hard to Believe that augmented glenoids will do better with this?????
 - Meta Analysis by Gonzales et al 2011 estimate 14.3 % incidence of glenoid loosening with a 28.5 % revision rate
 - 2014 study by Reiss et al of cemented TSA with minimum of 15 yrs of follow up reported 73% of shoulders had radiographic loosening by final follow up, 31% were revised
 - Young et al 2011
 - Multicenter study of cemented PE glenoid components by demonstrated 80.3% survivorship at 10 years and 33.6% survivorship at 15 years with radiographic loosening as endpoint



ROTHMAN INSTITUTE Sidney Kimmel Medical College at Thomas Jefferson University

Other Weak Link??????

ROTATOR CUFF

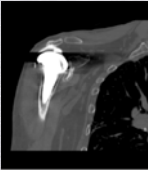





Int J Shoulder Surg. 2016 Apr-Jun;10(2):78-84. doi: 10.4103/0973-0642.190720.

Rotator cuff tears after total shoulder arthroplasty in primary osteoarthritis: A systematic review.
 Leisy DM¹, Abrams GD², Harris JD³, Bach BR, Jr⁴, Nicholson GP⁵, Romeo AA¹





1: Author information

- Systematic review of 15 studies reporting on markers of rotator cuff dysfunction
- Mean f/u of 6.6 years +/- 3.1 years
- **29.9% of shoulders demonstrated radiographic superior migration**
- **12% Showed anterior migration of the humeral head**
- **Do we expect this to be less of a problem as we tension the posterior cuff with an augment????**



RTSA vs ATSA

- **RSA provides greater surgical flexibility in B2 Glenoids**
 - Avoid Cement failure and glenoid loosening
 - Easier to bone graft
 - Easier to soft tissue tension


Reverse TSA



- Indications Rapidly Evolving
- Most Literature is out of Date based on Early adoption of New Technology
- Current Literature is Lacking but Growing
- Need Current Data with 2nd and 3rd generation RSA implants
- Need Better Comparison of Outcomes with prospective studies looking at RSA versus augmented glenoids for B2s
 - Complications
 - Function
 - Ease of Use
 - Cost

Is RSA Easier for the Low Volume Surgeon and B2 Glenoid????



- Low volume surgeons and low volume centers have increased complications with a ATSA
- ATSA requires **greater technical skills** to balance soft tissues

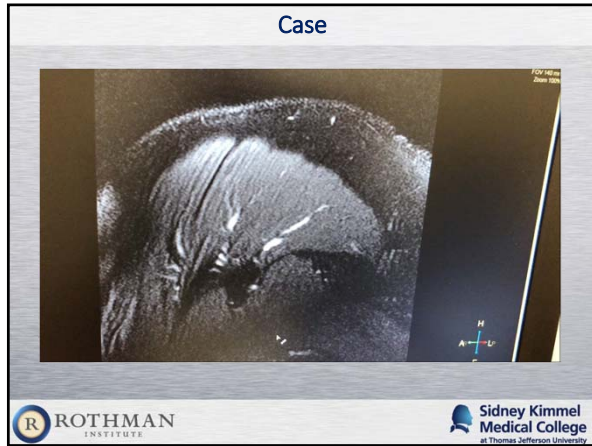

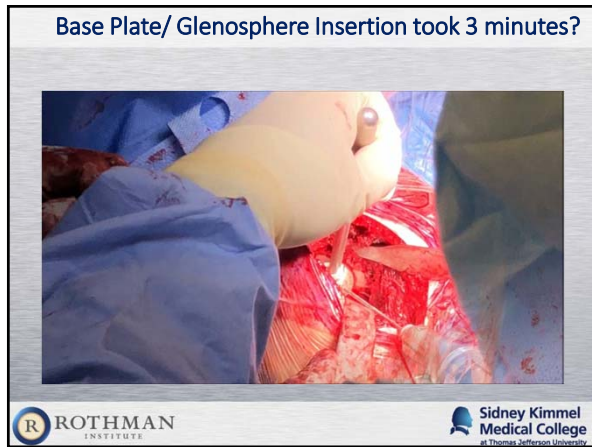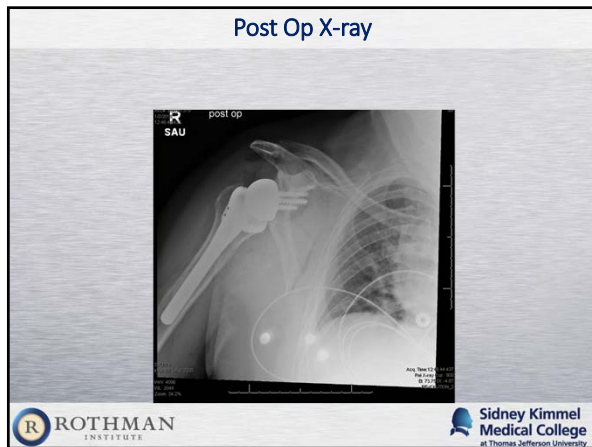How much of the glenoid can be left unsupported in TSA vs RSA

- 10%
- 20%
- 25%
- 30%
- 40%
- 50%










CONCLUSIONS
B2 glenoid



- Preoperative quantification (retroversion *AND* subluxation) is critical
- Posterior subluxation likely recurs in mid term
- Absolute RSA indications
 - Neoglenoid retroversion: > 35°
 - Subluxation / scapula: > 80%





Iannotti who did poor

- More fatty infiltration
- More B3
- More medialization of joint line

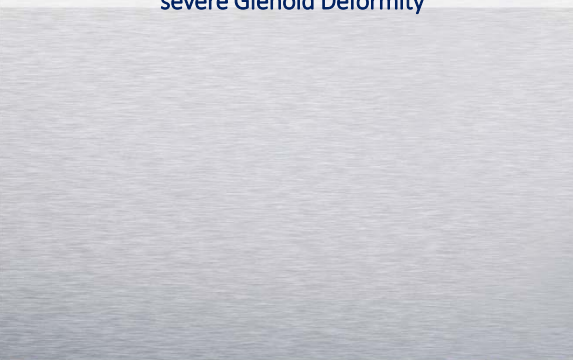
 

Final Thought

Prospective comparative study of reverse TSA versus anatomic TSA using augmented glenoid component needed to define which patients best treated with each prosthetic type

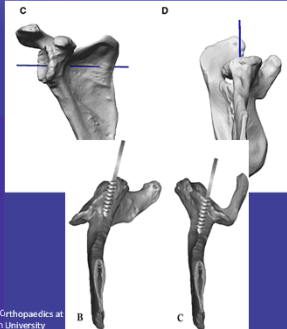
Technical pearls to consider in severe Glenoid Deformity



ROTHMAN INSTITUTE Sidney Kimmel Medical College at Thomas Jefferson University

Alternate Center Line

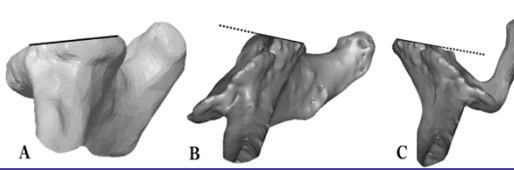
- In line with the scapular spine



Rothman Institute of Orthopaedics at Jefferson University

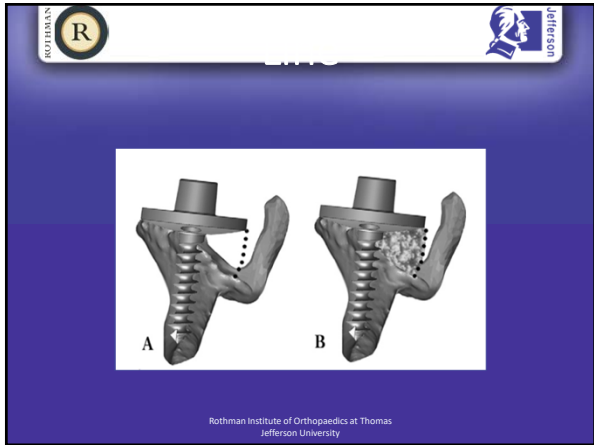
Alternate Center Line


- Ream perpendicular to the ACL
- Graft under baseplate if <80% contact




Rothman Institute of Orthopaedics at Thomas Jefferson University







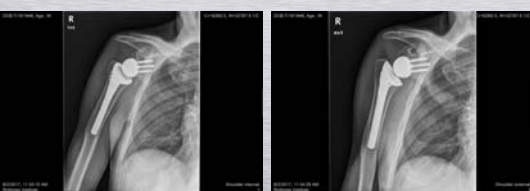
What did I do with the Initial Case?



ROTHMAN
INSTITUTE

Sidney Kimmel
Medical College
at Thomas Jefferson University

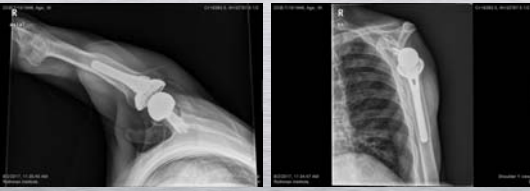
7 Months Post-op



ROTHMAN
INSTITUTE

Sidney Kimmel
Medical College
at Thomas Jefferson University

7 Months Post-op



ROTHMAN
INSTITUTE

Sidney Kimmel
Medical College
at Thomas Jefferson University



