




Humeral Head Replacement With Glenoid Reaming Arthroplasty "Ream and Run"

Andrew Green, MD
Chief of Division of Shoulder and Elbow Surgery
Warren Alpert Medical School, Brown University






Disclosures

- Wright, Inc- royalties, consulting, research support
- DJO- speakers panel, research
- Journal of Bone and Joint Surgery Deputy Editor
- Details on AAOS website



What is Youth?

- Age
- Activity level and expectations
- Medical status and co-morbidities
- 55 yo commonly cited as young



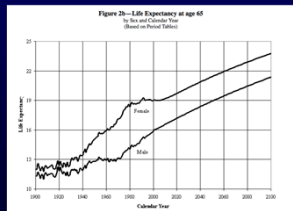
What is Long-Term?

- Arbitrarily defined as 10 years



Life Expectancy

- Life expectancy of 65 year olds is increasing
- 65 year old has 50% chance of living past 85



US Life Expectancy

Age	Male	Female
55	27.5	30.7
65	19.3	21.7
75	11.8	13.6



<https://www.ssa.gov/planners/lifeexpectancy.html>



Total Shoulder <65 Years Old



- 2008 - 30% US TSA patients were younger than 65 years
- Australian Registry 2008-2013- 22% less than age 65

Age Years	#TSA	% of Total
18-44	429	1.6
45-64	7316	27.4
65-84	17856	66.8
≥ 85	1118	4.2

Kim et al JBJS-A 2011



Figure 5T1: Primary Total Shoulder Replacement by Age and Gender

Australian Registry 2014



Goals of Arthroplasty in Younger Patients

- Pain relief
- Functional restoration
- Avoid early complications and need for short-term revision surgery
- Predictable long-term outcome

Patient Expectations

- Younger patients more active
- Outcome goals and expectations differ from older patients
- Return to labor, sports, heavier vigorous activities

Activity After Shoulder Arthroplasty

- McCarty et al AJSM 2008
 - Patients who participated in sports or recreation before arthroplasty
 - 64% had surgery to be able to participate in sports or recreation
- Zarkadas et al JSES 2011
 - TSA 89% participated in medium and high demand activities and sports after arthroplasty



Anatomic Arthroplasty Options



- Humeral head replacement
 - without glenoid preparation
 - biologic glenoid resurfacing
 - "Ream and run"
- Total shoulder arthroplasty



A Comparison of Pain, Strength, Range of Motion, and Functional Outcomes After Hemiarthroplasty and Total Shoulder Arthroplasty in Patients with Osteoarthritis of the Shoulder. A Systematic Review and Meta-Analysis


Dianne Bryant, Robert Litchfield, Michael Sandow, Gary M. Gartsman, Gordon Guyatt and Alexandra Kirkley
J Bone Joint Surg Am. 2005;87:1947-1956. doi:10.2106/JBJS.D.02854

- Meta-analysis- RCTs; min 2 yr f/u
- 112 patients
- aTSA better functional outcome than HHR
- 6% HHR revised to TSR within 24 months
- 20% HHR revised to TSR within 48 months
- aTSA the "gold standard" for advanced glenohumeral arthritis




"Ream and Run"


Matsen, et al JOR 2005




Normal-canine




10 weeks




24 weeks



Reamed



BROWN Alpert Medical School

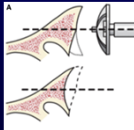


The Prognosis for Improvement in Comfort and Function After the Ream-and-Run Arthroplasty for Glenohumeral Arthritis


An Analysis of 176 Consecutive Cases JBJS-A 2012

Brian B. Gilmer, MD, Bryan A. Gomstock, MS, Jocelyn L. Jette, BS, Winston J. Warne, MD, Sarah E. Jenkins, PT, and Frederick A. Matsen III, MD


- Level II prognostic
- 176 cases- 162 min 2 year fu
- Post op improvement slow-up to 1.5 years
- Mean SST for GHOA=10.3
- 10 (6%) revision arthroplasty
- 7 (4%) revised to TSA



- Best prognosis-males >age 60 yrs, primary osteoarthritis, no prior surgeries




BROWN Alpert Medical School




Shoulder hemiarthroplasty with concentric glenoid reaming in patients 55 years old or less

Matthew D. Saltzman, MD^a, Aaron M. Chamberlain, MD^b, Deana M. Mercer, MD^b, Winston J. Warne, MD^b, Alexander L. Bertelsen, PA-C^b, Frederick A. Matsen III, MD^{b,*} JSES 2011

- Level IV case series
- 65 shoulders ; <55yo
- Mean f/u unrevised 43 mth
- 14% revision
- In selected patients 55 years or younger significant improvement in self-assessed shoulder comfort and function








BROWN Alpert Medical School



Humeral Preparation


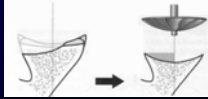


- Standard humeral exposure and preparation
- Lesser tuberosity osteotomy
- Short stem or stemless
- Anatomic humeral head







Glenoid Preparation

- Glenoid exposure
- Resect most of labrum
- Concentric reaming 2-3mm radius of curvature mismatch with humeral head
- Partially correct posterior retroversion
- Peripheral drill holes

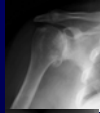
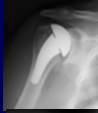










Early Outcome

- 46 patients- 43 males
- GHOA
- Patients selected the procedure
- Mean age 58
- 12-48 mth fu
- One revision- P. acnes PJI


	Pre Op	Post op	aTSA
ASES	32	79	87
AFE	110°	138°	
AER	10°	36°	



Total Shoulder Arthroplasty

- Excellent pain relief and functional restoration
- Faster recovery
- What about long-term outcome?



BROWN Alpert Medical School UNIVERSITY ORTHOPEDICS

48 yo RHD Male "Ream and Run"



BROWN Alpert Medical School UNIVERSITY ORTHOPEDICS

Young Arthritic Shoulder?

- Shared decision making
 - Counsel patient
- Total shoulder
 - most predictable outcome, pain relief, and function
 - glenoid will likely fail
- Humeral head replacement with glenoid reaming arthroplasty
 - high demand physically active patient



18 Kilo Kettle Bell work out

BROWN Alpert Medical School UNIVERSITY ORTHOPEDICS

Thank You!



The slide features a dark blue background with a thin red horizontal line near the top. The text "Thank You!" is centered in a yellow font. At the bottom, there are two logos: on the left, the BROWN Alpert Medical School logo, and on the right, the UNIVERSITY ORTHOPEDICS logo.
