

**Periprosthetic Fracture:  
Now What?**

Lynn A. Crosby, M.D  
Professor and Director of Shoulder  
Dept. of Orthopaedic Surgery  
Medical College of Georgia  
Augusta University, Augusta, Ga.

---

---

---

---

---

---

---

---

**Disclosures**

Consultant  
-Exactech  
Royalties  
-Exactech

---

---

---

---

---

---

---

---

**Fractures**

- Poor bone quality
  - Advanced age
  - Rheumatoid arthritis
  - Osteoporosis
  - **Female Gender**

---

---

---

---

---

---

---

---

## Periprosthetic Fracture

### Incidence:

Humerus – 3%

Scapula

- Acromion – 2-5%

- Scapula spine / body – 4 %

---

---

---

---

---

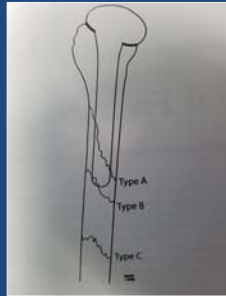
---

---

---

## Periprosthetic Humerus Fractures - Classification

- Cofield/Wright
  - Type A – At the tip extension proximal
  - Type B – At tip extension predominantly distal
  - Type C – distal to tip
- Multiple other classification systems



---

---

---

---

---

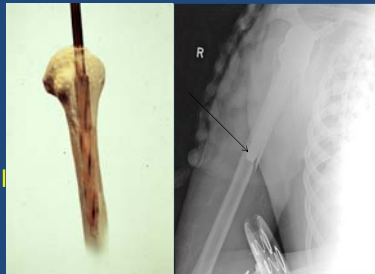
---

---

---

## Intra-operative Fractures

- 0.9% incidence
  - Torque
  - Reaming
  - Trial Reduction
  - Seating humeral component



---

---

---

---

---

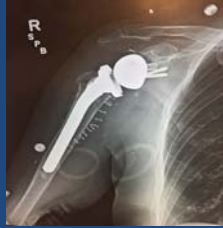---

---

---

## Intraoperative

- Greater tuberosity
  - Suture
  - Fx prosthesis +/- RTSA
- Calcar fx
  - Stable nothing
  - Unstable – cerclage
- Shaft – long oblique/spiral
  - Long stem +/- plate rotation control



---

---

---

---

---

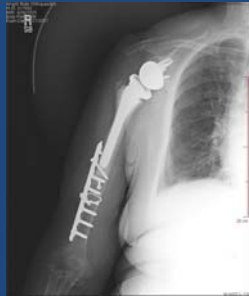
---

---

---

## Intra-operative Fractures

- Humeral shaft
- Brace
  - Long stem revision prosthesis
  - Cerclage wires and or plates and screws



---

---

---

---

---

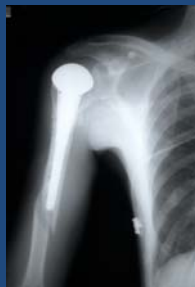---

---

---

## Postoperative Fracture

- Rare 0 - 3%
- Bracing vs ORIF
- Prosthesis loose
  - Revision to long stem



---

---

---

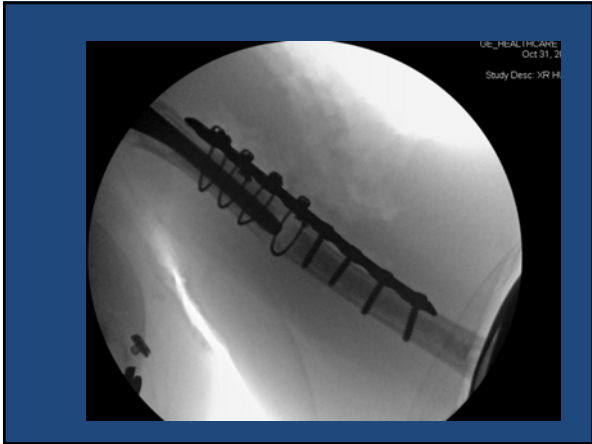
---

---

---

---

---



---

---

---

---

---

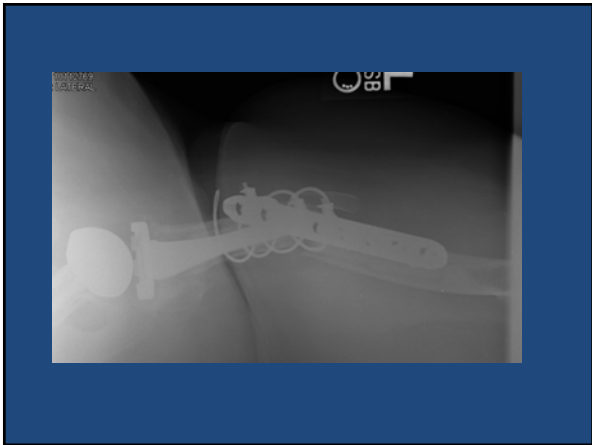
---

---

---

---

---



---

---

---

---

---

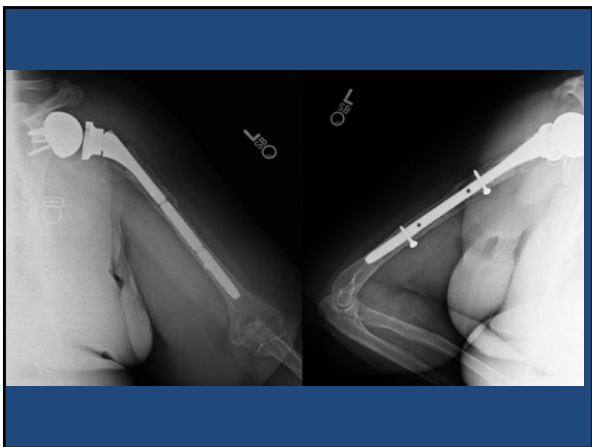
---

---

---

---

---



---

---

---

---

---

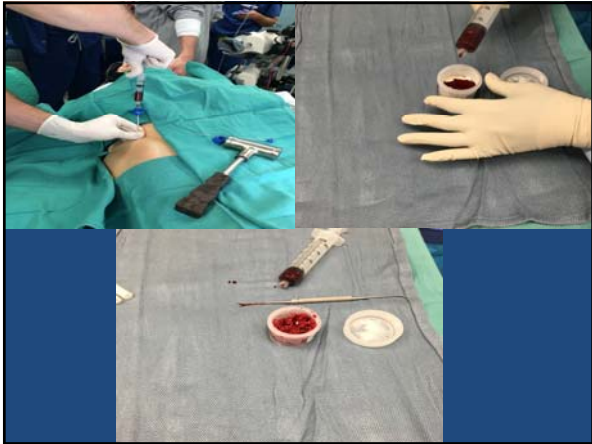---

---

---

---

---



---

---

---

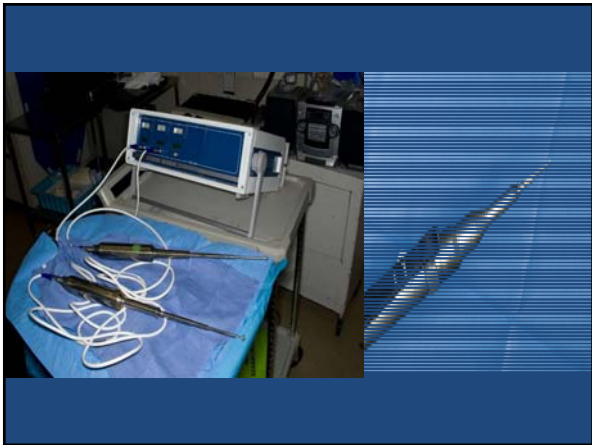---

---

---

---

---



---

---

---

---

---

---

---

---

## Conclusion

- Intraoperative – avoid by good exposure
- Postop – unstable stem
  - Revision RTSA
- Postop – stable fx
  - Fx brace
- Postop – good prosthesis
  - ORIF
- Union rates high/complications high
- Function fair

---

---

---

---

---

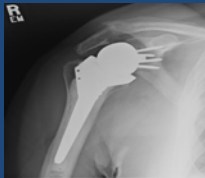---

---

---

Scapular Fractures after Reverse Total Shoulder Arthroplasty:  
Classification and Treatment  
Clinical Orthopaedics and Related Research 2011  
Crosby LA, Hamilton A, Twiss T.

- 400 patients scapular fx incidence was 5.5%
- Classified 3 types based on where on the acromion/scapula the fx occurred.



---

---

---

---

---

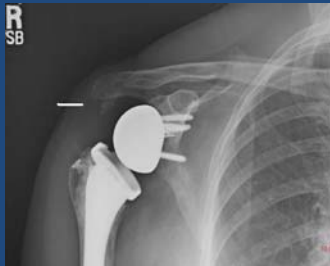
---

---

---

### Type I

- A fracture or avulsion of the anterior acromion



---

---

---

---

---

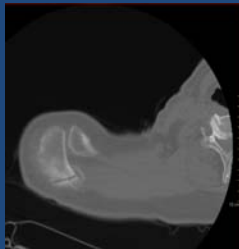
---

---

---

### TYPE II

- A fracture through the acromion posterior to the (AC) joint  
CT scan often needed to make diagnosis



---

---

---

---

---

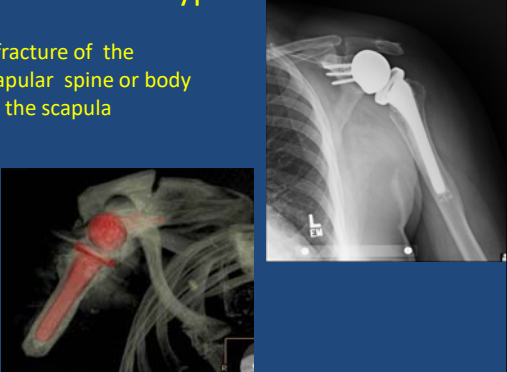
---

---

---

**Type III**

- A fracture of the scapular spine or body of the scapula



---

---

---

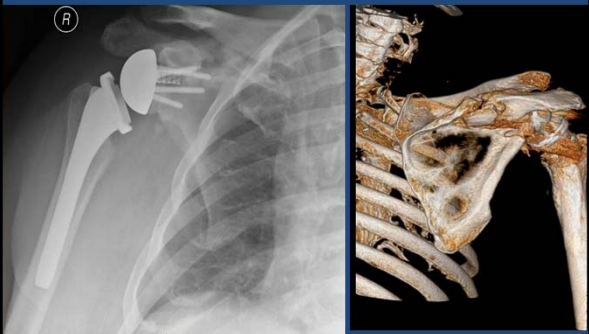
---

---

---

---

---



---

---

---

---

---

---

---

---

Classification of Postoperative Acromial Fractures Following Reverse Shoulder Arthroplasty  
JBJS 2013  
Levy JC, Anderson MS and Samson A

- 18 patients over 56 months
- Recommended CT scan to evaluate
- Classification based on Deltoid origin
  - Type 1 - anterior and middle deltoid
  - Type 2 - middle deltoid and posterior deltoid
  - Type 3 – entire middle and posterior deltoid

Non operative treatment produced inferior function results

---

---

---

---

---

---

---

---

### Scapula Fracture Incidence in Reverse Total Shoulder Arthroplasty Using Screws Above or Below Metaglene Central Cage: Clinical and Biomechanical Outcomes

JSES June 2017

- Kennon, Lu, McGee- Lawrence and Crosby

---

---

---

---

---

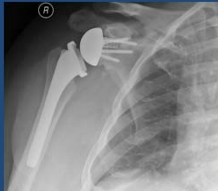---

---

---

### Type III Scapular Fx

- 2009 - 2013 - 207 pts had screws placed above the central cage  
8 type III fx in 207 pts (3.9%) with screws placed above the central cage



---

---

---

---

---

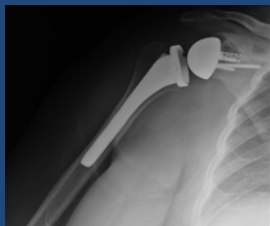---

---

---

### Type III Scapular Fx

- 2013 - 2015 - 107 pts that had no screws placed above the central cage  
NO fx in 107 pts (0%)



---

---

---

---

---

---

---

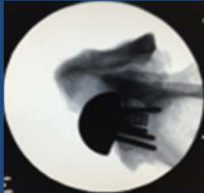

---

### Type III Scapular Fx

- Biomechanical testing
  - 16 cadaveric scapula specimens
  - Matched for BMD with Dexa scans

Two groups

1. Metaglene implanted with screws below the central and 1 screw above



---

---

---

---

---

---

---

---

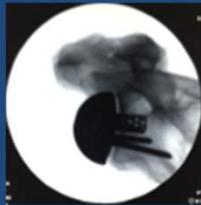

---

---

### Type III Scapular Fx

2. Metaglene implanted with only screws below the central cage and no screw above

Tested with isokinetic compression force



---

---

---

---

---

---

---


---

---

---

### Type III Scapular Fx

- Biomechanical Results:
  - No difference in age of the specimens or bone mineral density (BMD)
  - Scapula with a screw placed above the central cage revealed a 45% lower ultimate load to fracture. 1077N vs 1979N  $P=0.001$



---

---

---

---

---

---

---

---

---

---

**Acromial / Scapular Fx  
Recommendation**  
REHABILITATION

- Data suggesting type II acromial fx occur at 45 degrees of abduction in scapular plane
- Need more information regarding areas of stress and when the maximum forces are applied to the acromion
- Adjusting the rehab in the first 6-12 weeks may be able to decrease the incidence

---

---

---

---

---

---


---

---

**Acromial / Scapular Fx  
Recommendation:**

Acromial Fracture Type II

- If non displaced and pain relieved with rest
  - Non operative treatment if normal AC joint
- Symptomatic
  - Consider AC joint resection if binding
- Operative treatment
  - Recommend intramedullary screws with tension band fixation.
  - Hook Plate ?



---

---

---

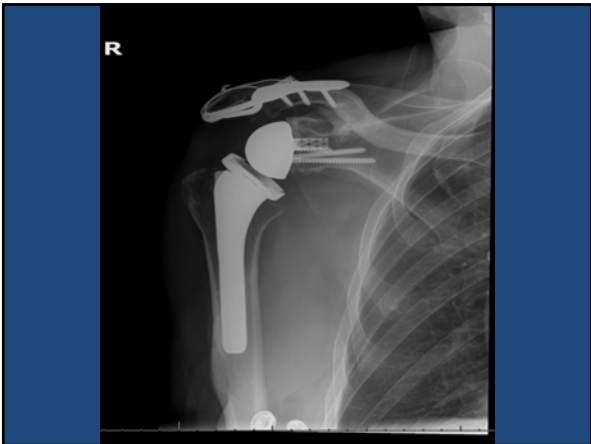---

---

---

---

---



---

---

---

---

---

---

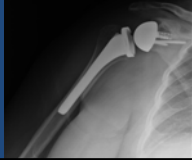---

---

## Type III Scapular Fx

Type III scapular fx

- "Prevention is best treatment"
- Recommend no screws be placed above central cage, peg, or screw unless needed for stability of the implant.



---

---

---

---

---

---

---

---



---

---

---

---

---

---

---

---