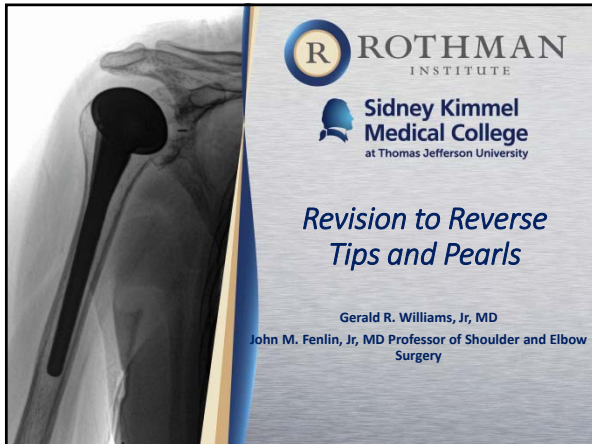

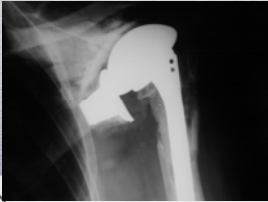
Conflict of Interest Slide



- **Royalties**
 - DJO: shoulder arthroplasty
 - Depuy: shoulder arthroplasty
 - Lippincott, Williams, and Wilkins: shoulder texts
 - IMDS/Cleveland Clinic: arthroplasty
- **Research: Tornier, Depuy, Synthasome**
- **Stock Ownership: CrossCurrent Business Analytics, LLC, OBERD, LLC, Force Therapeutics**



Definitions



- Failed anatomic prosthesis
- Revised to a reverse in one or more stages
- No infection







Surgical Challenges

- Surgical planning-- implants, instruments, ancillary equipment, virtual planning tool
- Soft-tissue management
- Implant removal
- Cement removal
- Bone deficiency-- glenoid, humerus
- Soft-tissue deficiency-- especially subscapularis
- Nerve injury

Pre-operative Planning

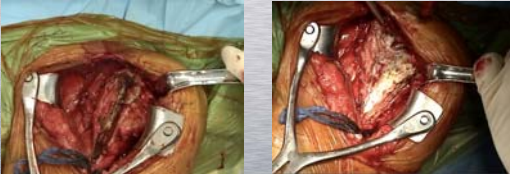
- Know prior implants-- have extraction equipment
- Allograft
- Blood
- Long-stem reverse implants
- Any other custom implants
- All potentially necessary ancillary equipment



 

Surgical technique

Soft-tissue Management



- Preserve anterior soft-tissue if present
- LTO or peel
- Excise inferior capsule
- Identify nerves, esp. axillary






Glenoid Extraction/Preparation

- **Modular humerus**
 - Remove head, leave stem to protect humerus
- **Monobloc**
 - Remove humerus, do glenoid first
- **All poly glenoids easy to remove**
- **Leave well fixed cement**
- **Inferior placement**
 - Eccentric glenosphere





Metal Backed Glenoids

- Some can be extremely difficult to remove
- Consider custom implants






Dillon, M. T.; Zmistowski, B. M.; and Williams, G. R., Jr.: *J Shoulder Elbow Surg*, 18(6): e26-9, 2009.



Humeral Component


- Some stems allow conversion to reverse without extraction
- Must be well-positioned
- Know details of version correction and neck-shaft angle correction





Humeral Component Extraction Cementless Component

- Separate bone from porous surface circumferentially
 - May need medial window
- Remove bone superior to fins
- Use appropriate extractor or medial tamp

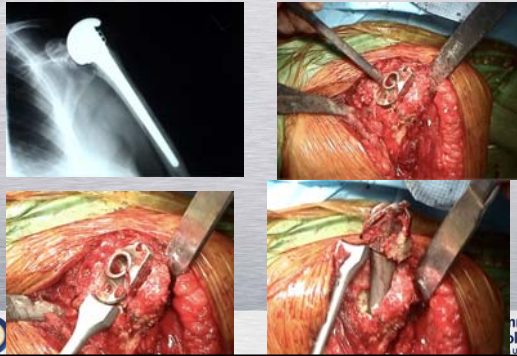


Sperling, J. W., and Cofield, R. H.: *J Shoulder Elbow Surg*, 14(3): 258-63, 2005.

ROTHMAN INSTITUTE

Sidney Kimmel Medical College at Thomas Jefferson University

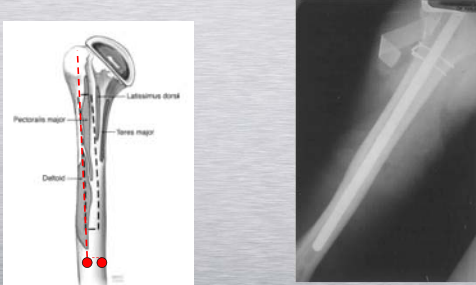
Humeral Component Extraction Cemented Component



ROTHMAN INSTITUTE

Sidney Kimmel Medical College at Thomas Jefferson University

Corticotomies and Windows



Sperling, J. W., and Cofield, R. H.: *J Shoulder Elbow Surg*, 14(3): 258-63, 2005.

ROTHMAN INSTITUTE

Sidney Kimmel Medical College at Thomas Jefferson University

Humeral Cement Management

- Cement smaller stem into previous cement mantle
 - Good cortices
 - No corticotomy or window
- Remove cement, place long stem component
 - C-arm





ROTHMAN INSTITUTE

Sidney Kimmel Medical College at Thomas Jefferson University

Special Issues Glenoid Bone Loss

- Small defects
 - Cancellous chips
 - Base plate usually stable
- Large defects-- cavitory
 - Long central peg-- fixation in native bone
 - Threaded baseplate option probably best
 - Consider iliac crest autograft
 - Glenoid allograft
 - Custom baseplates, augmented baseplates
- Can be staged

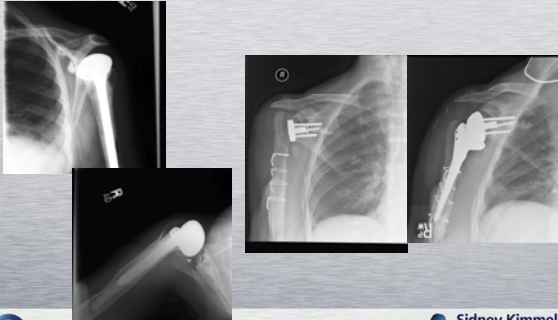


Courtesy: Tom Norris, MD

ROTHMAN INSTITUTE


Sidney Kimmel Medical College at Thomas Jefferson University

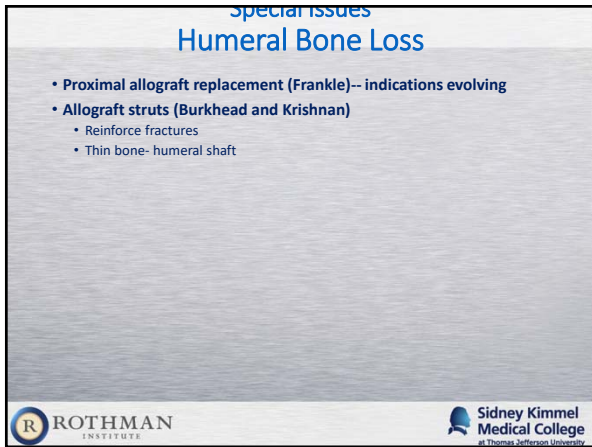
Staged Reconstruction Glenoid Allograft

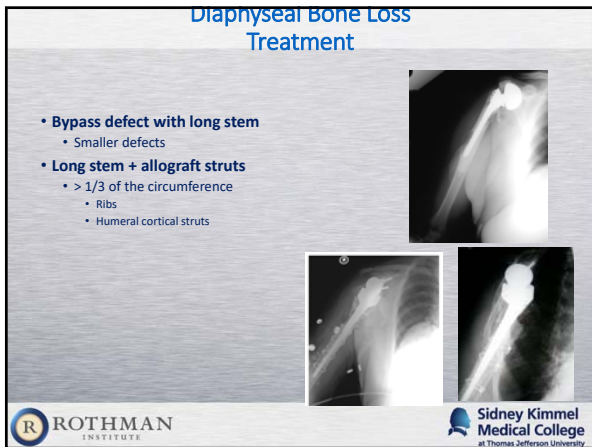


ROTHMAN INSTITUTE

Sidney Kimmel Medical College at Thomas Jefferson University









Metaphyseal Bone Loss Treatment

- Calcar ???
- Tuberosities
 - Ignore
 - Allograft (Frankle)





Bulk Allograft Results



Chacon A. et.al. J Bone Joint Surg 2009;91:119-127






Bulk Allograft Results

	Preoperative*	Postoperative*	Mean Improvement	P Value
ASES score (points)				
Total	31.7 (0-77.5)	69.4 (25-93.3)	37.7	<0.0001
Pain	18.4 (0-45)	38.1 (15-50)	19.7	<0.0001
Function	13.3 (0-32.5)	31.3 (0-43.3)	18.0	<0.0001
SST score (points)				
	1.4 (0-7)	4.5 (0-11)	3.1	<0.0001
Range of motion (deg)				
Forward flexion	32.7 (0-115)	82.4 (2-142)	49.7	<0.0001
Abduction	40.4 (0-90)	81.4 (15-165)	41.0	<0.0001
External rotation	9.9 (-5-35)	17.6 (-10-65)	7.7	0.0793
Internal rotation	Sacrum (greater trochanter to L1)	L4 (greater trochanter to T4)	2 vertebral levels	



* The data are given as the mean with the range in parentheses.

Chacon A. et.al. J Bone Joint Surg 2009;91:119-127




Bulk Allotment Concerns

- **Reported results**
 - Limited
 - No control group
- **Disease transmission**
- **Durability/incorporation**
- **Infection**



Revision to Reverse Arthroplasty

- **Worst results of all reverses**
 - Often no other option
- **Be experienced**
- **Be ready**
- **Be prepared for failure**
- **Bring the "kitchen sink"**



Thank You