

Remplissage is here to stay!!

**2018 CURRENT SOLUTIONS IN
SHOULDER & ELBOW SURGERY**
FEBRUARY 1-3, 2018
TAMPA, FL



E. Rhett Hobgood, M.D.
MS Sports Medicine
Jackson, MS

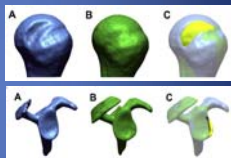


Disclosures

- Consultant for Exactech
- No royalties from any company
- Fellowship support from Mitek, S&N, Arthrex

Three-dimensional quantitative analysis of humeral head and glenoid bone defects with recurrent glenohumeral instability

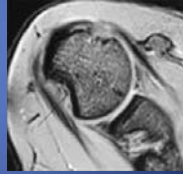
- 90 patients with anterior instability had 3D CT scans
- Bone Defects
 - 96% of glenoids
 - 98% of humeral heads



Matsumura JSES, 2017

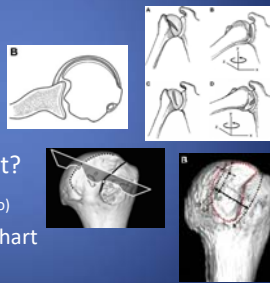
Hill-Sachs Lesions

- Burkhart and De Beer (Arthroscopy 2000)
 - 194 cases
 - 11% recurrent instability after arthroscopic Bankart
 - 67% recurrence with bone defects



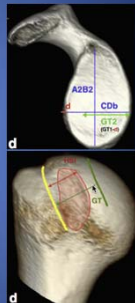
Hill-Sachs Lesions

- What is critical size of Hill-Sachs Lesion?
 - Engaging?
 - Minimum size?
 - Volume?
 - Articular surface?
 - Bipolar involvement?
 - “Off track”? (Yamamoto)
 - Giacomo, Itoi, Burkhart
 - Arthroscopy 2014



Interobserver and intraobserver variability of glenoid track measurements

- 3D CT evaluation
- 71 shoulders
- 3 shoulder surgeons, 1 MSK radiologist
- Glenoid bone loss reliably and reproducibly measured
- HS lesion measurement **HIGHLY variable**





J Shoulder Elbow Surg (2017) 26, 573–579

Treatment of Hill-Sachs Controversial

- Isolated Bankart repair (with large HS) yields ↑ recurrence rates
 - Boileau et al (JBJS 2006)
 - Burkhart and De Beer (Arthroscopy 2000)
- HS defect treatment → ↓↓ recurrence rates
 - Boileau et al JBJS 2012 (Remplissage)
 - Burkart et al Arthroscopy 2007 (Latarjet)

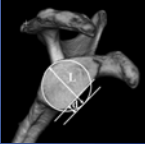
Hill-Sachs Defect Treatment Options

- Address humeral defect
 - Allograft humeral head reconstruction
 - Osteochondral transplant
 - Humeral head replacement
- Limit defect engagement
 - Remplissage (<25%)
 - Latarjet coracoid transfer (>25%)



Critical Value of Anterior Glenoid Bone Loss That Leads to Recurrent Glenohumeral Instability After Arthroscopic Bankart Repair

- 169 anterior instability patients with glenoid erosion
- <17.3% bone loss → 3.7% failure rate
- >17.3% bone loss → 42.9% failure rate
 - No Remplissage performed



AJSM, 2017

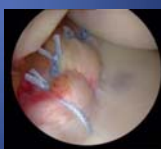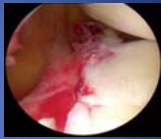The Effect of Subcritical Bone Loss and Exposure on Recurrent Instability After Arthroscopic Bankart Repair in Intercollegiate American Football

- 50 anterior instability reconstruction patients
- <13.5% glenoid boss loss -- **No** patients developed recurrent instability
- >13.5% glenoid boss loss -- **All** patients developed recurrent instability
 - Beach chair position
 - **No Remplissage performed**

AJSM, 2017

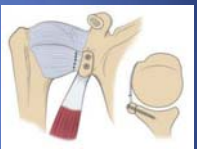Advantages Of Arthroscopic Stabilization

- Unparalleled assessment
 - Labrum
 - Rotator cuff
 - Biceps
- Subscapularis not violated
- Cosmesis
- Access to all pathology
 - Hill-Sachs lesions



Recurrent Anterior Shoulder Instability With Combined Bone Loss

- 52 patients underwent Latarjet for bipolar bone loss and **engaging Hill Sachs**
 - 40 patients -- <25% glenoid loss (15%)
 - 12 patients -- >25% glenoid loss (34%)
- **Recurrent instability (15% vs 17%)**
- ER loss 9° (<25% group) vs 16° (>25% group)
 - p = .001
- **Graft resorption 33%** for both groups
- **Complication rate 25%** for both groups
 - 3 deep infections requiring surgery
 - 5 hardware removal patients



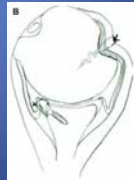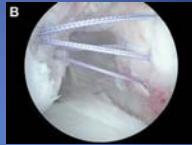
AJSM, 2015

“Remplissage” = to fill



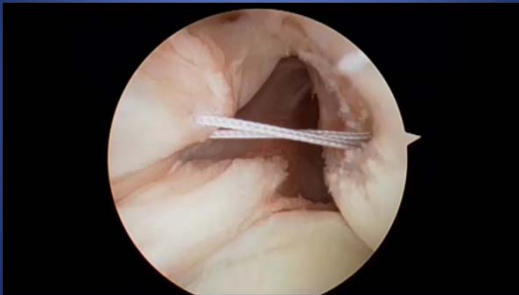Hill-Sachs “Remplissage”: An Arthroscopic Solution for the Engaging Hill-Sachs Lesion

- Arthroscopic alternative to Latarjet
- Tenodesis of posterior cuff/capsule into Hill-Sach lesion
- Converts the Hill-Sach's to an extra-articular lesion
- Prevents engagement



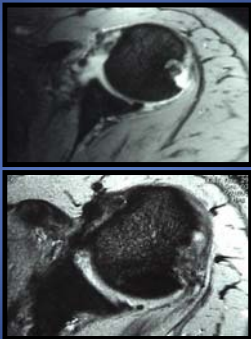
Purchase RJ, Wolf EM, et al. *Arthroscopy* 2008

Remplissage



Purchase RJ, Wolf EM, et al. *Arthroscopy* 2008


Remplissage



Purchase RJ, Wolf EM, et al, Arthroscopy 2008

Remplissage


- Early clinical success as supplement to stabilizations
- Concern over non-anatomic infraspinatus advancement
 - Glenohumeral joint mechanics
 - Distortion of normal anatomy
 - Potential for ROM loss
 - Possible negative effect on rotator cuff function
- Strong biomechanical & clinical evidence to support Remplissage



Remplissage Versus Latarjet for Engaging Hill-Sachs Defects Without Substantial Glenoid Bone Loss

A Biomechanical Comparison

- Created moderate (25%) engaging Hill Sachs lesion in 8 cadaveric specimens
- Intact glenoid bony rim
- Compared Latarjet with Remplissage
 - Resistance to anterior translation
 - ROM
 - Frequency of dislocation
- Both procedures effectively stabilized shoulders
- Latarjet ↓ IR/ER motion in abduction (29%) greater than remplissage
 - (p = 0.01)




COOR 2014

Remplissage of an Off-track Hill-Sachs Lesion Is Necessary to Restore Biomechanical Glenohumeral Joint Stability in a Bipolar Bone Loss Model

Robert U. Hartzler, M.D., M.S., Christopher N. H. Bui, M.D., Woong K. Jeong, M.D., Masaki Akeda, M.D., Alex Peterson, B.A., Michelle McGarry, M.S., Patrick J. Denard, M.D., Stephen S. Burkhart, M.D., and Thavi Q. Lee, Ph.D.

- Cadaveric biomechanical comparison
 - 8 Specimens
 - 15% glenoid bone loss +
 - 15% on track Hill-Sachs OR
 - 30% off track Hill-Sachs
 - Bankart repair alone (without Remplissage) did not prevent engagement in any shoulder with off track lesions (0 of 8 shoulders)
 - Adding Remplissage prevented engagement in all shoulders that had previously engaged



Arthroscopy 2016

Literature Review

- Multiple clinical studies
 - Boileau et al – JBJS 2012
 - Merolla et al – AJSM 2014
 - Wolf et al – JSES 2014
 - McCabe et al – Arthroscopy 2014
- Low recurrence rates
- None to minimal motion loss
- Very low complication rate

Hill-Sachs remplissage, an arthroscopic solution for the engaging Hill-Sachs lesion: 2- to 10-year follow-up and incidence of recurrence

Eugene M. Wolf, MD^{1,*}, Afshin Arianjam, MD²

- 59 patients with remplissage and bankart repair
- 45 available f/u (8 open, 2 scope revisions)
- 2 recurrences (4.4%)
- 58 months avg f/u




JSES. 2014

Primary Versus Revision Arthroscopic Reconstruction With Remplissage for Shoulder Instability With Moderate Bone Loss

Michael P. McCabe, M.D., Douglas Weinberg, M.D., Larry D. Field, M.D., Michael J. O'Brien, M.D., E. Rhett Hobgood, M.D., and Felix H. Savoie III, M.D.

- **20 primary** stabilizations
 - All "engaging" Hill Sachs lesions
 - **No recurrences at 3 ½ years**
 - No motion loss
 - Excellent outcomes at short term f/u
- **11 revision** arthroscopic stabilizations
 - Supplemental Remplissage
 - **36% recurrence**



Arthroscopy, 2013

Outcomes of Arthroscopic Hill-Sachs Remplissage and Anterior Bankart Repair

A Retrospective Controlled Study Including Ultrasound Evaluation of Posterior Capsulotenodesis and Infrapinatus Strength Assessment

- 61 patients (mod/lg HS, < 20% glenoid loss)
- Follow-up 40 months
- **1 patient** with recurrent instability
- 9° loss of external rotation
- **No difference in infrapinatus strength**
- **Ultrasound showed consistent filling**

AJSM, 2014

Literature Review

- **Multiple systematic reviews support Remplissage**
 - Buza et al - JBJS 2014 (167 patients)
 - Longo et al - Arthroscopy 2014 (769 patients)
 - Leroux et al - Arthroscopy 2013 (220 patients)
 - Rashid et al - Knee Sg Tr Arth 2014 (207 patients)
 - Low recurrence rates
 - None to minimal motion loss
 - Very low complication rates

Arthroscopic Hill-Sachs remplissage: a systematic review.
 Buza JA 3rd, Ivenqar JJ, Anakwenze OA, Ahmad CS, Levine WN.

- JBJS 2014 (Systematic Review of Remplissage)
 - 6 studies included (167 patients)
 - 5.4% recurrence rate
 - No studies showed ↓ shoulder motion post-op

Large Hill-Sachs Lesion: a Comparative Study of Patients Treated with Arthroscopic Bankart Repair with or without Remplissage.
 Garcia GH¹, Park MJ², Zhang C³, Kelly JD 4th², Huffman GR³.

- 24 patients with large engaging Hill Sachs lesions (glenoid bone loss <20%)
 - 14 arthroscopic Bankart
 - 10 arthroscopic Bankart + Remplissage
- Bankart group
 - 8 of 14 failed (57%)
- Bankart + Remplissage group
 - 2 of 10 failed (20%)
 - Improved outcome scores

HSS Journal, 2015

Anterior shoulder instability with engaging Hill-Sachs defects: a comparison of arthroscopic Bankart repair with and without posterior capsulodesis.
 Cho NS¹, Yoo JH, Juh HS, Rhee YG.

Knee Surg Sports Arth, 2015

- 72 patients with engaging Hill Sachs lesions
 - 35 Bankart
 - 37 Bankart + Remplissage

	ER Loss	Recurrence
Bankart	3°	26%
Bankart + Remplissage	8° (p=.04)	5% (p=.02)

- No decreased strength in either group

Management of an engaging Hill-Sachs lesion: arthroscopic remplissage with Bankart repair versus Latarjet procedure

Nam Su Cho¹ · Jae Hyun Yoo¹ · Yong Gil Rhee¹


- 37 Bankart + Remplissage vs 35 Latarjet
- All had large engaging Hill-Sachs with glenoid preservation (< 25% bone loss)
- No significant difference between groups
 - ROM
 - 5% recurrence both groups
- Complication rate (p = 0.02)
 - 0% Bankart + Remplissage
 - 14.3% Latarjet

Knee Surg Sports Trauma 2016

Chronic anterior shoulder instability with significant Hill-Sachs lesion: Arthroscopic bankart with remplissage versus open latarjet procedure

A. Bah^{a,*}, G.M. Lateur^b, B.T. Kouevidjin^a, J.Y.S. Bassinga^c, M. Issa^a, A. Jaafar^c, E. Beaudouin^a

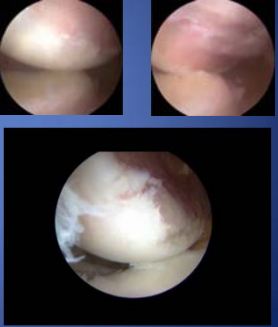
- 43 Bankart/Remplissage, 43 Latarjet
- Large HS, <30% glenoid bone loss
- 9.3% recurrence in B/R, 11.2% in Latarjet
- Slight loss of ER in BR group v/s laterjet



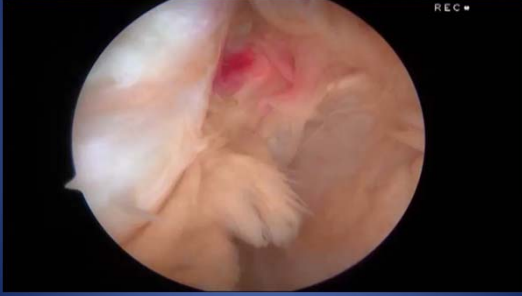Orthopaedics & Traumatology: Surgery & Research xxx (2017)

Remplissage Indications

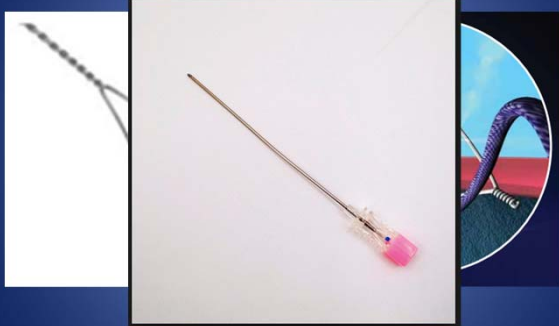- Near universal agreement in literature
 - "Engaging" Hill-Sachs lesions during dynamic arthroscopic assessment
 - No "substantial" glenoid bone loss
 - Most commonly cited in studies as <25%
- Used as supplement for non-engaging lesions?

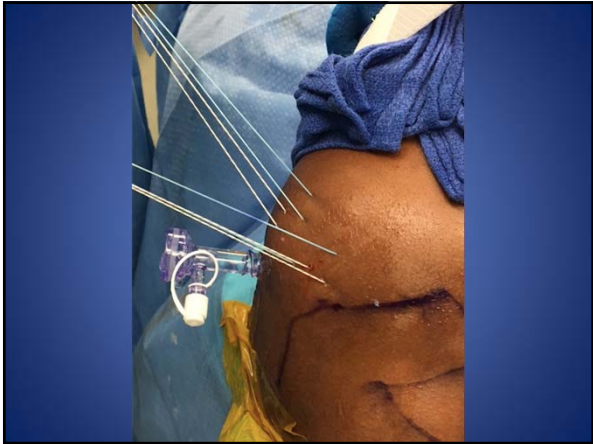


Technique

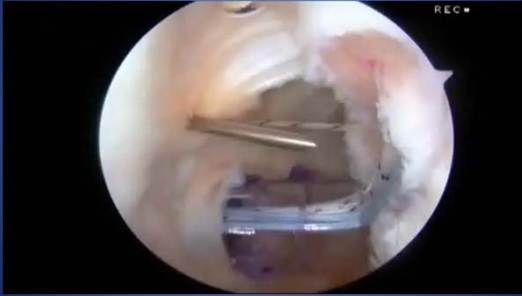

Technique



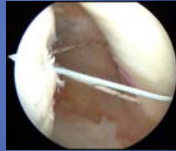

Technique



Summary

- Remplissage valuable and effective
 - Reduces recurrence rates
 - Low complication rate
 - Minimal ROM loss
- Indications important
 - Engaging Hill Sachs lesions
 - Glenoid bone relatively well preserved



THANK YOU