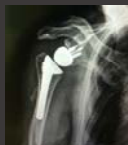
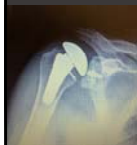
# Reverse Shoulder Arthroplasty: Does the pre-op diagnosis matter?

Derek Cuff, M.D.  
Suncoast Orthopaedic Surgery and Sports Medicine

Current Solutions in Shoulder and Elbow Surgery  
February 1-3 2018



---

---

---

---

---

---

---

---

## Disclosures

- DJO Surgical- Consultant
- Ignite Orthopedics- Consultant

---

---

---

---

---

---

---

---

## Goals

1. Highlight the expanding indications for RSA
2. Discuss pre-op considerations for specific diagnosis/indication
3. Technical pearls for specific diagnosis/indication

---

---

---

---

---

---

---

---

### Last 12 months

- Primary cuff tear arthropathy
  - Massive recurrent RTC tear + arthropathy
  - Massive non-reparable cuff tear with no OA
  - 4-part proximal humeral fracture in elderly
  - Failed hemiarthroplasty
  - Failed/Unstable TSA
  - Glenohumeral OA with B2 and B3 glenoid
  - Glenohumeral OA with glenoid dysplasia
  - Proximal humeral malunion
  - Failed ORIF proximal humerus
  - Post-capsulorrhaphy arthropathy with deficient subscap
  - Chronic dislocation in elderly
- 12 different indications

---

---

---

---

---

---

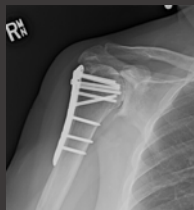
---

---

### Does diagnosis matter?

• Consent reads RTSA but large variability in:

- Pre-op concerns
- Technical concerns
- Patient expectations
- Patient outcomes



---

---

---

---

---

---

---

---

### Does diagnosis matter?

• Humeral sided diagnosis that concern me

- 1. Proximal humeral malunion (Type 4 fracture sequela)
- 2. Failed hemiarthroplasty

---

---

---

---

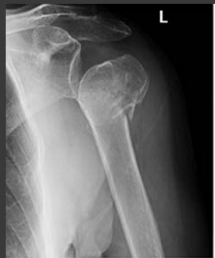---

---

---

---

### Proximal Humeral Malunion



---

---

---

---

---

---

---

### Proximal Humeral Malunion

• Pre-op concerns

1. Where is the greater tuberosity?
2. Be ready to cement stem

• Intra-op concerns

1. Careful with canal orientation (fluro if needed)
2. Be prepared to osteotomize and repair greater tuberosity

---

---

---

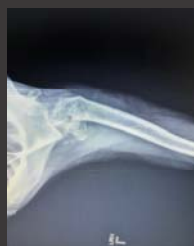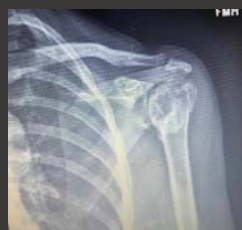---

---

---

---

### Proximal Humeral Malunion



---

---

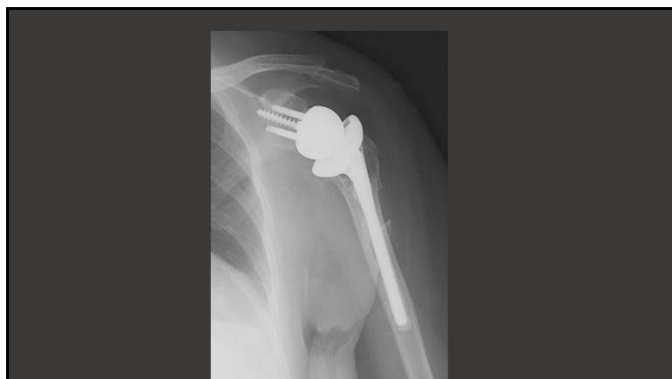---

---

---

---

---



---

---

---

---


---

---

---

---

### Proximal Humeral Malunions



- Boileau et al 2016
  - Improved Constant scores
  - Avg. FE around 120°
  - 98% satisfaction rating

- Patient expectations
  - Improved ROM (not as good as primary RSA)
  - Can have ER loss of motion

---

---

---

---


---

---

---

---

### Failed Hemiarthroplasty



---

---

---

---

---

---

---

---

### Failed Hemiarthroplasty

- Pre-op concerns:
  1. Is proximal humeral bone loss present?
  2. How is the stem fixation?
- Intra-op concerns:
  1. Carefully assess stability
  2. Be sure to remove posterior scar tissue
  3. Proximal humeral allograft or augmented humeral implant (SRS, HRP)

---

---

---

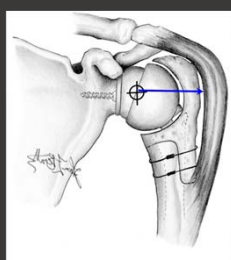
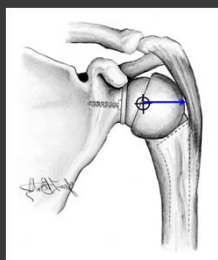
---

---

---

---

---



---

---

---

---

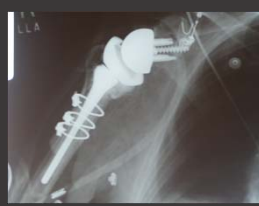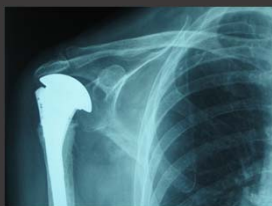---

---

---

---

### Failed Hemiarthroplasty



---

---

---

---

---

---

---

---

### Failed Hemiarthroplasty



• Levy et al- 2007

- Improved ASES
- Avg FE 70°, (30-150)
- 79% patients satisfied

• Patient expectations

- Pain relief
- ROM will be improved but limited (difficult to predict)

---

---

---

---

---

---

---

---

### Does the diagnosis matter?

• Glenoid sided diagnosis that concern me

- 1. Bad B3 glenoid or a C glenoid
- 2. Failed TSA-defects after glenoid removal

---

---

---

---

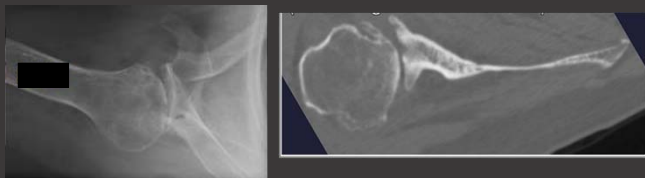
---

---

---

---

### B3 Glenoids



---

---

---

---

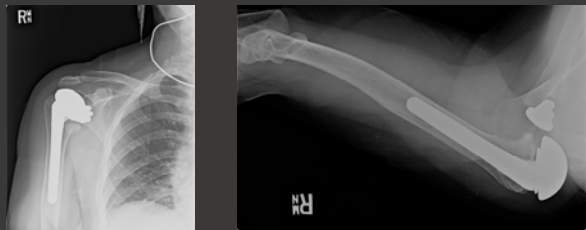---

---

---

---

### Failed TSA



---

---

---

---

---

---

---

### Glenoid bone loss

- Pre-op concerns
  - 1. Amount of glenoid bone stock for center screw
  - 2. Will I need alternate scapular line?
- Intra-op concerns
  - 1. Low threshold to use alternate scapular line
  - 2. Be prepared to bone graft

---

---

---

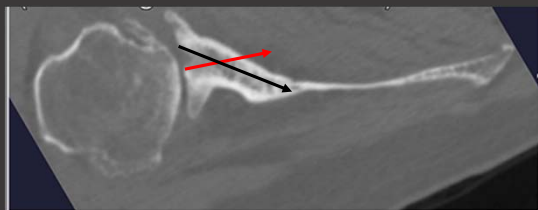
---

---

---

---

### Glenoid bone loss



---

---

---

---

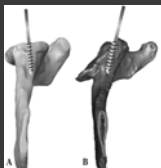
---

---

---



- Klein et al- 2010; 143 shoulders with 2 years follow-up
- Patient expectations
- No baseplate failures or instability
- Good ROM no different than standard RSA technique



---

---

---

---

---

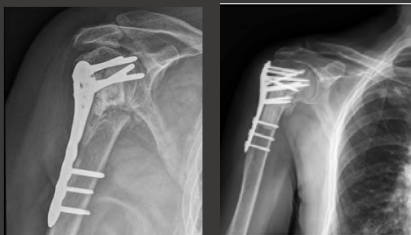---

---

---

### Does the diagnosis matter?

- Both humeral and glenoid concerns:
- 1. Failed ORIF



---

---

---

---

---

---

---

---

### Failed ORIF

- Pre-op concerns:
  - 1. Correct instruments for hardware removal
  - 2. Was a fibular strut used
  - 3. Be ready for glenoid defects
- Intra-op concerns:
  - 1. Leaving the stem tip at a stress riser
  - 2 Glenoid bone loss techniques as needed

---

---

---

---

---

---

---

---

## Failed ORIF

Locking plate fixation of fractures of the proximal humerus: analysis of complications, revision strategies and outcome

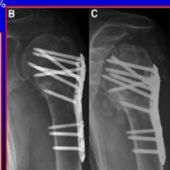
Bernhard Jost, MD\*, Christian Spross, MD, Holger Grehn, MD, Christian Göttsche, MD, FRCS(Ed) (Hons) *JSES, 2013*

Level IV Retrospective Analysis: 121 pts with Complications after ORIF

Secondary screw cutout was found in 57%

Glenoid Destruction in 33%

Table II	Complications (121 patients)	No. of patients*
Non-implant related		
	Non-union	47
	Primary screw cutout	14
	Malunion	76
	Neuroma	16
	AKN	82
	Infection	5
Implant related		
	Secondary screw cutout	69
	Glenoid destruction	40



\* Several complications per patient were possible.

---

---

---

---

---

---


---

---

---

---

## Failed ORIF



- JBJS- Hussey et al. 2015
- 19 patients- 26% major complication rate

- Patient expectations
- Higher complication rate
- Typically less motion

---

---

---

---

---

---

---

---

---

---

## Summary

- Indications continue to expand
- Certain pre-op diagnosis offer unique challenges
- Pre-op planning and modification of intra-op techniques
- Manage patient expectations with certain pre-op diagnosis

---

---

---

---

---

---

---

---

---

---

Thank you



---

---

---

---

---

---

---

---