

Tampa 2018 

Grammont design - rationale

F. Gohlke




Klinik für Schulterchirurgie – Rhön-Klinikum – Bad Neustadt / Saale

Disclosure

The author (F.G.) has related to this topic no conflict of interest

- consultant for Wright/Tornier
- involved the development of a revision system of Wright – without accepting royalties
- receives no royalties from any manufacturer related to this subject

 RHÖN-KLINIKUM
KLINIK FÜR SCHULTERCHIRURGIE

Reverse, high-conformity, non-linked brilliant idea of Paul Grammont (Nancy)...?

« La médialisation par l'inversion »



P. Grammont



2nd. design: short stem, lateral offset glenosphere, ceramics



Medinov Delta-III-shoulder

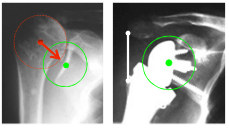


1985
short stem- „trompette“

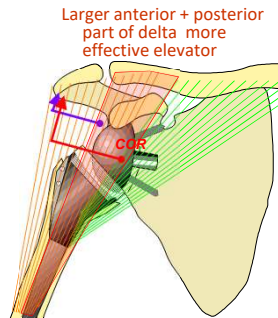
Grammont P, Trouillard P, Laffay JP, Deries X (1987): Etude et réalisation d'une nouvelle prothèse d'épaule. Rheumatologie 39 : 407-418

 RHÖN-KLINIKUM
KLINIK FÜR SCHULTERCHIRURGIE

« La médialisation par l'inversion »



Larger anterior + posterior part of delta more effective elevator



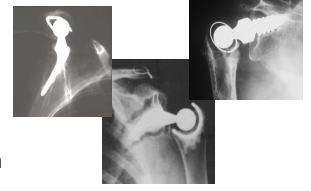
- Fixed fulcrum
- center of rotation medialized: minimizing torque on glenoid component
- Improving delta lever arm
- Pretensioning of the Delta muscle - distalizing the humerus

RHON-KLINIKUM

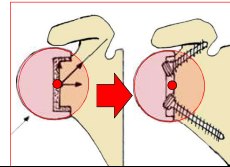
Reverse Shoulder arthroplasty
- major concern in Europe in the 80ies -

balancing 2 possible major complications


- Early baseplate loosening and glenoid destruction
- Instability / dislocation



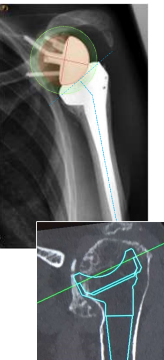
Grammont P, Trouillod P, Laffay JP, Deries X (1987): Etude et réalisation d'une nouvelle prothèse d'épaule. *Rheumatologie* 39 : 407-418



What is "Grammont-design"?





- **Glenosphere:** medialized center of rotation (shallow, 36 and 42 mm)
- Baseplate: flat, 29 / 25mm, HA coated, 2 divergent locking / 2 compression screws
- **155° neck shaft angle**, metapyseal + diaphyseal fixation
- „Inlay-Design“: Concavity of humeral component below the humeral head resection plane



RSA in CTA: 5-10years FU

Delta-3

- Minimum follow-up 5 years (5-9years), n=138: 96% survival without revision
- Patient satisfaction high: 95%, complication rate 3.2%
- Restriction of internal rotation (especially in Subscap deficiency) and weak external rotation



6 years post-OP (left shoulder)

Gohlke (2009): Orthop Traumatol Update

RHÖN-KLINIKUM
KATZENBERG

Cuff arthropathy and complete loss of external rotators
„Grammont-design“ RSA

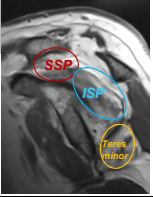

Insufficiency of external rotators of the cuff (SSP/ISP/Teres)

L'Episcopo-transfer: Latissimus dorsi and teres major with bone chip

4 years after correction of superior inclination +

**L'Episcopo transfer: painfree, CS: 94%
11.5 kg ABD strength, but restriction of internal rotation**





RSA Grammont design and sports? fracture sequelae

Function ?

- 72 yo., businessman
- Failed ORIF, fracture sequelae
- Stiffness and pseudoparesis
- RSA Grammont design in 2005





Preferred leisure activity

RHÖN-KLINIKUM
KATZENBERG

**Using RSA with Grammont design
what did we learn?**

- Avoiding superior tilt (correction to 0-10° inferior inclination with graft)
- Inferior overhang of glenosphere
- Correct version with humeral bone graft

**RSA Grammont design
„Grammont-Design“ RSA - fixed fulcrum design**

Long-term results

- 1953 mixed etiology > 5 years:
16% Stem loosening,
2,2 glenoid loosening,
2,3% instability
- 93 % survival after 10 years*
- 73% Notching*

*Boileau P, Chelli M, Favard L, et al.
French Multicenter-Study (Sauramps
Sauramps Medical; 2016:41-60)
Walch et al. (2017): JBJS-Am 99: 454

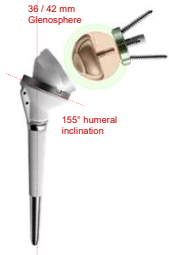
**French multicenter study RSA Complications
(long-term results/> 5y. n=1053, Nice 2016)**

	Primary RSA n=1660	Revision RSA n=293
Infection	2.6%	10.3%
Instability	2.3%	7%
Humeral Compl. Loosening, PPF e.g.	1.7%	7.5%
Neurological	1.5%	3.3%
Glenoid Loosening, disassembly	1.3%	1.4%
Scapula fracture Acromion, Spine	0,8%	1.4%
Total	11.5%	37%

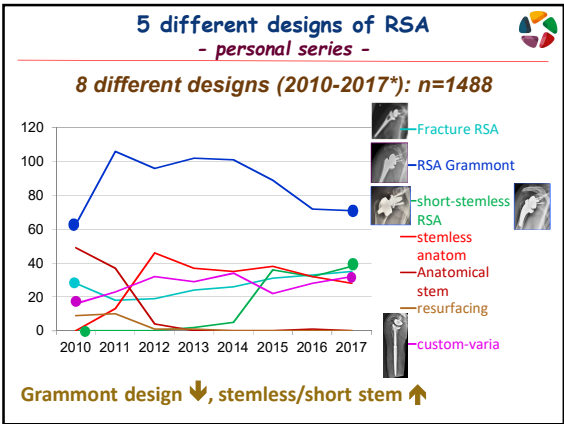
Survival rate in CTA: 93% at 10 years

RSA Grammont design

- **Drawbacks**
- 155° neck shaft angle
- Notching:
 - medialized COR
- No modularity

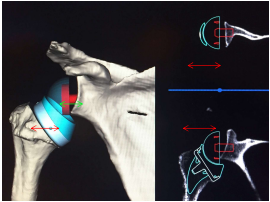


RHÖN-KLINIKUM
KATZENBERG



Both, humeral + glenoid lateralisation overstuffing the joint?

- Difficulty to reduce
- Remaining cuff overloaded
- Subscap repair
- Acromion/coracoid impingement
- Scapular spine fatigue fracture



RHÖN-KLINIKUM
KATZENBERG

Still a place for Grammont design

Avoids overstuffing of the GH joint

- Lateral offset increased by bone graft
- Excessive superior tilt (> 20°)
- Short and contracted rotator cuff
- Severe arthrofibrosis
- Fractures + fracture sequelae
- revisions

**Preoperative 3D CT based planning
virtual implantation: Grammont design?**

- selection of components and design
- Virtual ROM:
 - notching in Ext.-Rot. / Int.-Rot.
 - impingement

Inferior notching: larger and/or lateralized / eccentric glenosphere?

"The future belongs to those who see possibilities before they become obvious."

Oscar Wilde

STN-KLINIKUM
KUNST- UND KULTURSTIFTUNG
