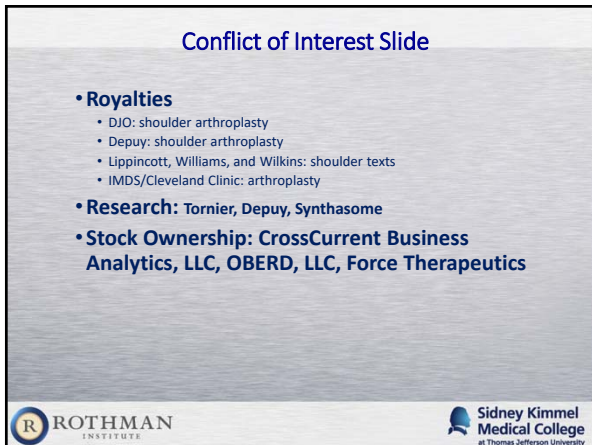








Background



- **Glenoid exposure is the most difficult part of TSR**
- **Must know where axillary nerve is**
- **Must be able to work at inferior glenoid**
- **Specialized instruments**
 - “Half moon” Reamers
 - Skinny, straight Drills




Specific Tips



- Tilt table
- Multiple retractors
- Remove humeral osteophytes
- Accurate humeral cut
- Humeral arm position
- Retractor placement
- Laminar spreader
- Maximum capsular release from humerus
- Anteroinferior capsular excision (or maximal release)
- Posteroinferior capsular release



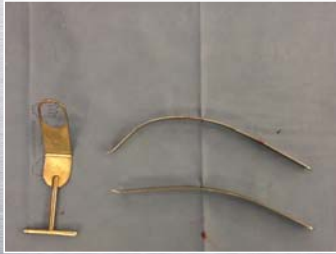


Tilt Table

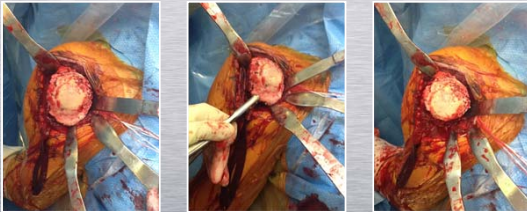




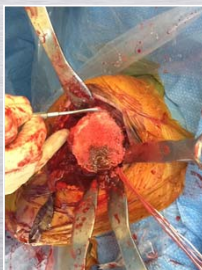
Multiple Retractors



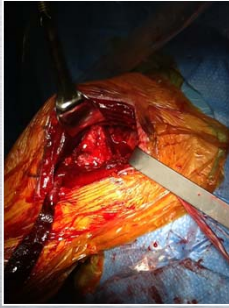Remove Humeral Osteophytes



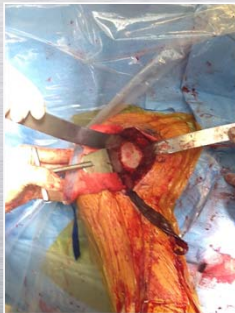
Humeral Cut



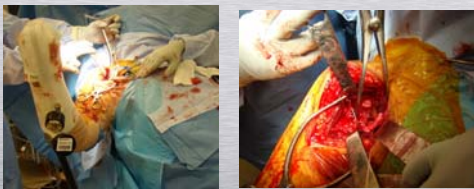Humeral Position



Retractor Placement



Laminar Spreader



Courtesy of Joseph Iannotti



