

Case Presentations  
Anatomic Total Shoulder

David Dines MD  
Hospital for Special Surgery

---

---

---

---


---

---

---

---

- 67 yo OB GYN
- Progressive painful shoulder
- Failed all conservative measures
- Restricted ROM
- Severe pain at night



---

---

---

---


---

---

---

---

Anatomic TSA



---

---

---

---

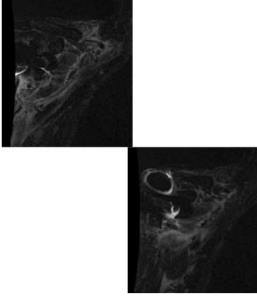
---

---

---

---

- Post-op Brachialplexopathy
- MRI plexus
- High dose steroids
- Slowly resolved



---

---

---

---

---

---

---

---

- At 3 weeks at PT felt sudden “pop” and pain on ER
- Painful
- Increased ER
- Sudden Loss of motion

---

---

---

---

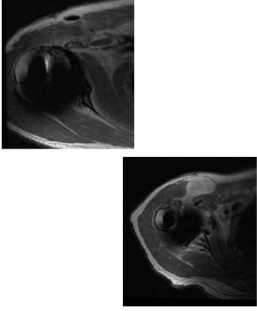
---

---

---

---

- At 3 weeks at PT felt sudden “pop” and pain on ER
- Painful
- Increased ER
- Sudden Loss of motion



---

---

---

---

---

---

---

---

- What happened?
  
- What now?

---

---

---

---

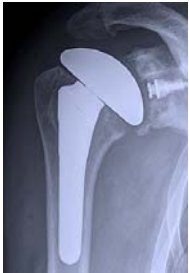---

---

---

---

- Primary Repair of **acute subscapularis tendon rupture** within 4 days
- Treated with double row repair/ human dermal allograft
- Responded well to therapy
- FE 165/ER 60/IR L1
- 5/5 strength all
- Full return to work and sports
- Golf handicap 9



---

---

---

---

---

---

---

---

**DISCUSSION**

---

---

---


---

---

---

---

---



---

---

---

---

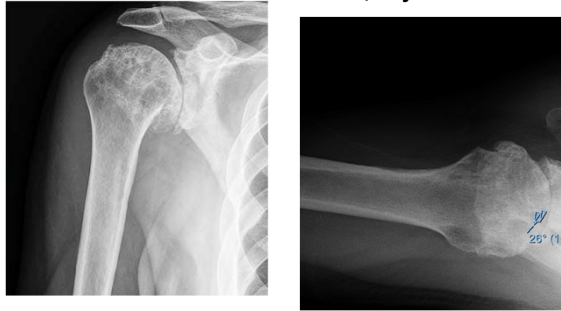
---

---

---

---

OA 65 yo male  
multiple debridements/Injections



---

---

---

---

---


---

---

---

TSR

- Did well but at 1 year post-op developed increasing pain and loss of ROM
- W/U
  - Infection v glenoid component loosening
  - Cuff or subscap failure



---

---

---

---

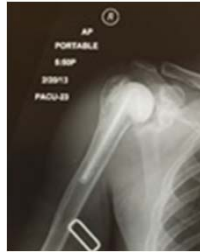---

---

---

---

- P acnes 5/7 cultures
- Glenoid loose → removed
- Spacer



---

---

---

---

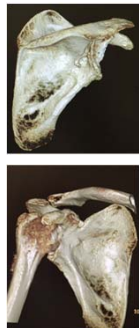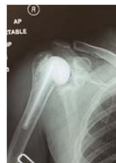---

---

---

---

- IV Abx then aspiration @ 8 weeks
- Substantial bone loss  
C4E3  
– 3D CT



---

---

---

---

---

---

---

---

**WHAT ARE OUR OPTIONS NOW**

---

---

---

---

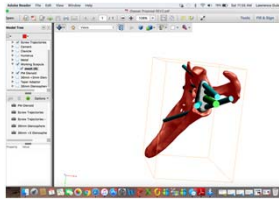
---

---

---

---

### PSI Vault Reconstruction System



- Patient-specific plan
- Patient-specific guide
- Patient-specific implant
  - Replaces glenoid vault loss

Patient specific plan, guide and implant

---

---

---

---

---

---

---

---

### PSI Vault Reconstruction System



- Patient-specific plan
- Patient-specific guide
- Patient-specific implant
  - Replaces glenoid vault loss

Patient guides

---

---

---

---

---

---

---

---

### PSI Vault Reconstruction System



- Patient-specific plan
- Patient-specific guide
- Patient-specific implant
  - Replaces glenoid vault loss

Patient specific implant

---

---

---

---

---

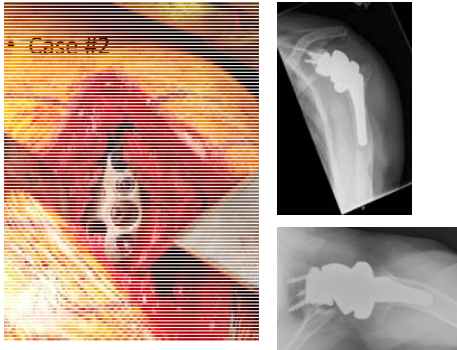
---

---

---

Doing well at 18 mos.???

Case #2



---

---

---

---

---

---

---

---

- 74 yo female
- Severe OA
- Failed all conservative Rx



---

---

---

---

---

---

---

---

Initial Results Excellent



---

---

---

---

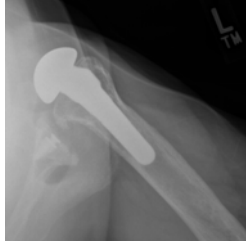---

---

---

---

- At 3mos tripped over her pet Yorkie.
- *The dog was not hurt*
- She suffered acute anterior dislocation
- Went to ER → Reduced
- Treated with sling X 4wks elsewhere
  - Weak IR
  - + Belly Press/Bear hugger
  - increased ER



---

---

---

---

---

---

---

---

What now

---

---

---

---

---

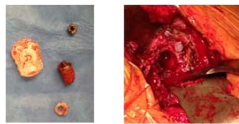
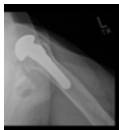---

---

---

Subscap Rupture/Anterior Instability after fall

- Removed well-fixed glenoid component
- Convertible Humeral stem left in place
- Revised to RSA



---

---

---

---

---

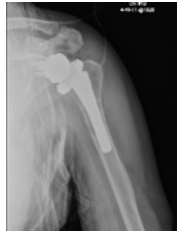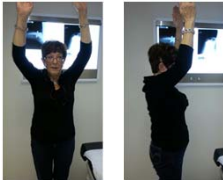---

---

---

### Conversion To Reverse

- Started PT immediately
- Regained excellent ROM and Function
- Still loves her dog



---

---

---

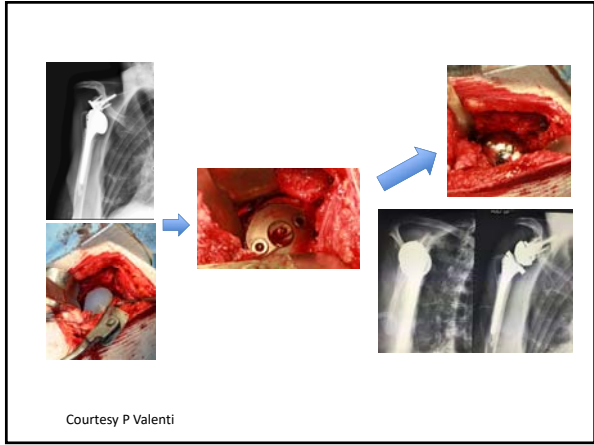
---

---

---

---

---



Courtesy P Valenti

---

---

---


---

---

---

---

---



---

---

---

---

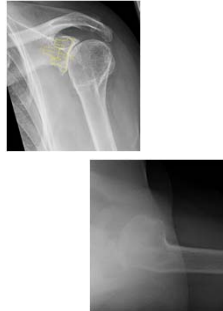---

---

---

---

- 57 yo female
- Proximal humeral fracture at 16 yo
- Persistent pain, restricted motion
- Failed all conservative measure
- FE 120, ER 40



---

---

---

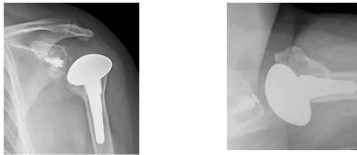
---

---

---

---

---



---

---

---

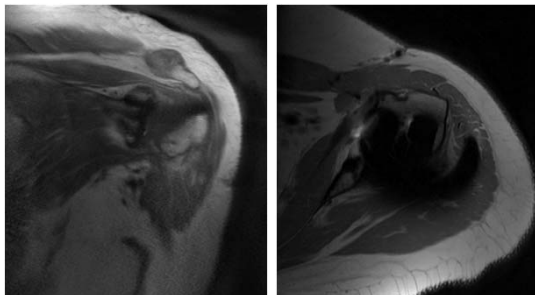
---

---

---

---

---



---

---

---


---

---

---

---

---



---

---

---

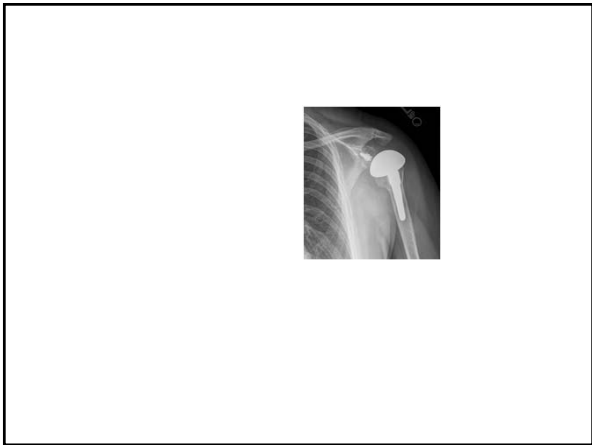---

---

---

---

---



---

---

---

---

---

---

---

---