

## Pearls of Arthroplasty for Fracture

T. Bradley Edwards, M.D.  
Fondren Orthopedic Group  
Texas Orthopedic Hospital  
Houston, Texas

---

---

---

---

---

---

---

---

### Disclosure for T. Bradley Edwards, MD

- Consulting/Royalty payments related to products discussed (DJO, Tornier)
- Consulting/Royalty payments for other products from the same company as the products discussed (Tornier)
- Research or other financial support from the same company as the products discussed (DJO, Tornier)

---

---

---

---

---

---

---

---

### Outline

- Right fracture
- Right patient
- Right implant
- Right technique

---

---

---

---

---


---

---

---

## Introduction

- Proximal humeral fractures
  - 3-part and 4-part
- Difficult indication
- Results unpredictable



---

---

---

---

---

---

---

---

## Case #1

- 58 year old male
- Fell skiing



---

---

---

---

---


---

---

---

## Case #2

- 52 year old female
- Fell from standing position



---

---

---

---

---

---

---

---

### Case #3

- 94 year old male S/P fall
- Lives independently with 93 year old wife



---

---

---

---

---


---

---

---

### Case #1

- History
  - Young, active
- Physical examination
  - NVI
- Radiographs
  - Angulation/displacement
  - Bone quality
  - Medial hinge



---

---

---

---

---



---

---

---

### Case #1

- Deltopectoral approach
- Indirect reduction of head fragment
- Direct reduction of tuberosities
  - Suture



---

---

---

---

---


---

---

---

### Case #1

- IM allograft strut
- Locking plate fixation
- Results




---

---

---

---

---

---

---

---

### Case #1

- Patient – young, active
- Fracture – medial hinge intact
- Implant – locking plate
- Technique – indirect reduction

---

---

---

---

---


---

---

---

### Case #2

- History
  - Young, inactive
  - Low energy
- Physical examination
  - NVI
- Radiographs
  - Angulation/displacement
  - Bone quality
  - Medial hinge




---

---

---

---

---

---

---

---

## Hemiarthroplasty

Series	Number of Patients	Active Elevation (°)	Painful Shoulder (%)
Neer	61	NA	9
Huten	34	90	26
Tanner	16	101	75
Frich	21	77	NA
Moeckel	22	119	23
Piétu	21	109	66
Hawkins	19	72	58
Compito	64	127	66
TOH	21	97	25

---

---

---

---

---

---

---


---

---

---

## Hemiarthroplasty

- Results are disappointing Why?




---

---

---

---

---

---

---



---

---

---

## Introduction

- Multicenter study 2001
  - 300 patients
  - 103° elevation
  - 19% painful
  - Prognostic factors
    - Tuberosity complications
    - Age

---

---

---

---

---

---

---

---

---

---

### Problems

- Ill adapted prosthesis (excess metal proximally)
- Prosthetic positioning (height, version)
- Poor tuberosity fixation

---

---

---

---

---

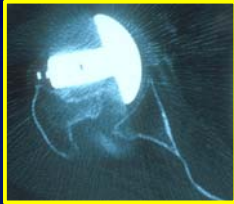
---

---

---

### Ill Adapted Prosthesis

- Excess metal in metaphyseal region obstructs proper positioning of greater tuberosity
- “Rocking” phenomenon
- Implant design changes



---

---

---

---

---

---

---

---

### Prosthetic Positioning



- Trial reduction difficult
- Solution → ancillary instrumentation/techniques

---

---

---

---


---

---

---

---

### Poor Tuberosity Fixation



- Poor bone quality
- Suture breakage (fin)
- No reproducible technique

---

---

---

---

---

---

---

---

---

---

### Poor Tuberosity Fixation

- Poor bone quality
  - Age related
  - Poor biology

?

---

---

---

---

---

---

---

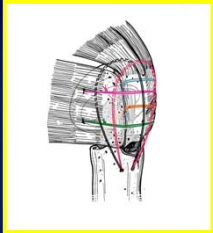
---

---

---

### Poor Tuberosity Fixation

- Reproducible fixation technique
  - 4 horizontal cerclage sutures
  - 2 vertical cerclage sutures
  - Nice loops
  - Racking hitch technique




---

---

---

---

---

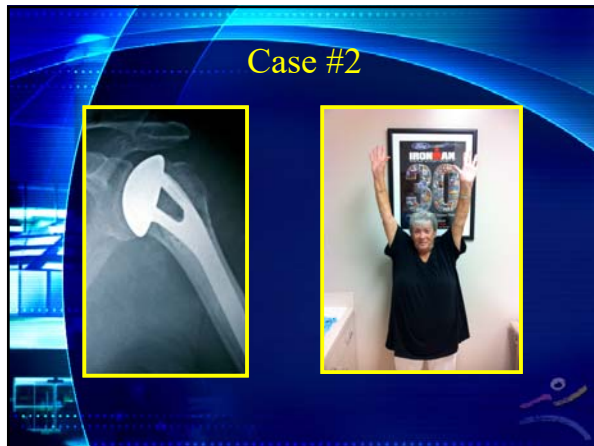---

---

---

---

---




---

---

---

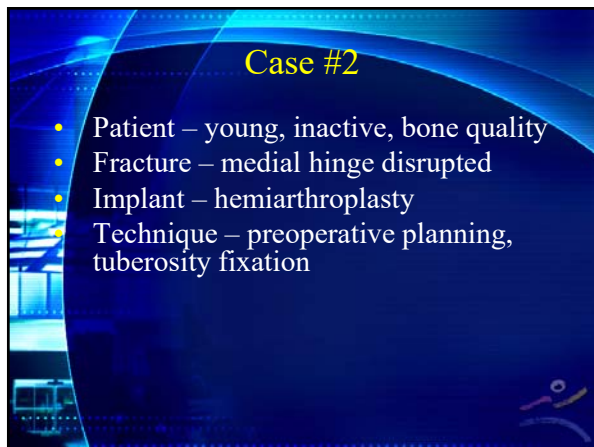
---

---

---

---

---




---

---

---

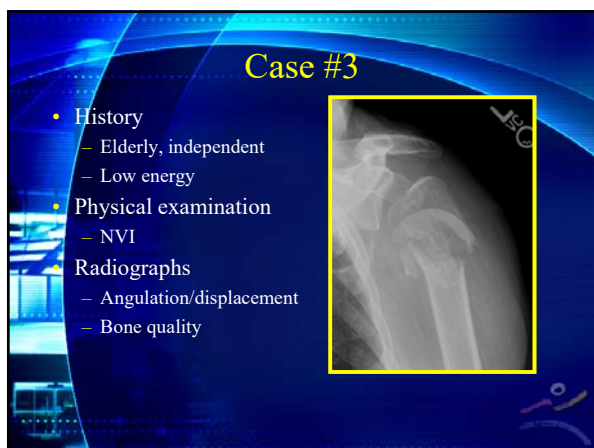---

---

---

---

---




---

---

---

---

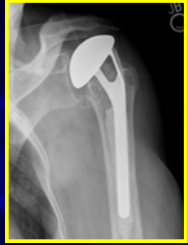---

---

---

---

## What if the Tuberosity Does Not Heal?



---

---

---

---

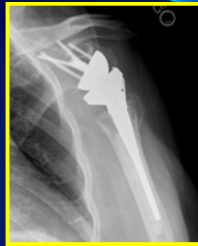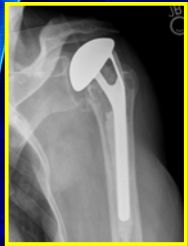---

---

---

---

## Tuberosity Failure



- Revision to reverse prosthesis

---

---

---

---

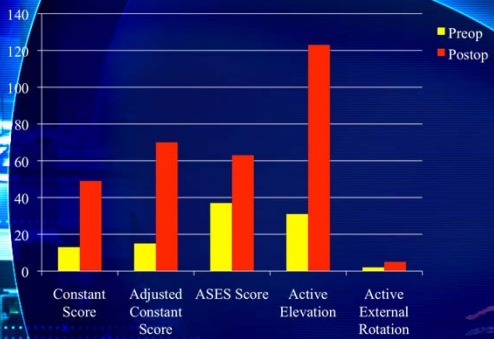
---

---

---

---

## Revision to Reverse Prosthesis



---

---

---

---

---


---

---

---

## Indications for Reverse

- Why not just eliminate the “primary arthroplasty” in patients at risk for tuberosity failure?
  - Displaced 3-part and 4-part fractures
  - Age > 70 years
  - Severe osteopenia




---

---

---

---


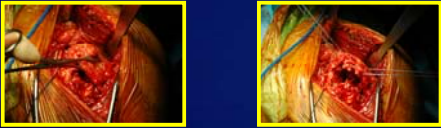
---

---

---

---

## Reverse Surgical Technique

- Tuberosities handled identical to unconstrained case

---

---

---

---

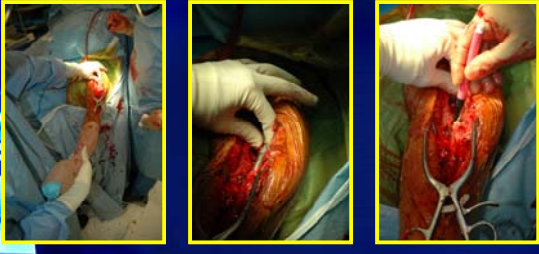
---

---

---

---

## Reverse Surgical Technique



- Trial implant “telescoped” to the glenosphere
- Maximal traction placed on arm
- Trial height marked

---

---

---

---

---

---

---

---

### Reverse Surgical Technique

- Final implanted cemented
- Trial reduction for tension
- Boileau technique for tuberosity fixation

---

---

---

---

---

---

---

---

### Case #3

4 years postoperative

---

---

---

---

---

---

---

---

### Case #3

- Patient – elderly, active, bone quality
- Fracture – medial hinge disrupted
- Implant – reverse prosthesis
- Technique – intraoperative trialing, tuberosity fixation

---

---

---

---

---

---

---

---

### Summary

- Proximal humeral fractures are challenging
- Optimal treatment varies depending on the patient and fracture type
- Displacement and angulation should be evaluated when considering operative intervention
- Status of medial hinge helpful in selecting ORIF vs arthroplasty

---

---

---

---

---

---

---

---

### Summary

- Advances in shoulder arthroplasty techniques, instrumentation, and implants have lowered tuberosity complication rates
- Poor bone quality (poor biology) remains a problem in certain cases and can inhibit tuberosity healing
- Reverse shoulder arthroplasty is an attractive alternative to hemiarthroplasty in select patients with proximal humeral fractures

---

---

---

---

---

---

---

---

### Thank You



---

---

---

---

---

---

---

---