

The Debate; Stemless v Stemmed Humeral Components Why I Use a Short-Stemmed Implant

David M Dines MD
Co-Director, Shoulder Fellowship
Hospital for Special Surgery
Weill Cornell College of Medicine

Disclosures ZimmerBiomet Inc., Thieme, ASES AAOS



Humeral Stem Complications Rare

- Contemporary designs
 - **Aseptic loosening very rare**
 - Malposition
 - Periprosthetic Fx
 - Infection

Sperling J, Hawkins RJ, Walch G, and Zuckerman JD; "Complications in Total Shoulder Arthroplasty" ICL JBJS 2013

Scarlat M; Complications with reverse total shoulder arthroplasty and recent evolutions Int Orthop. May 2013



Stemless to Short-stem Humeral Component Technology *Is less more?*




Definitely getting smaller !!!



Short Stem v. Stemless Humeral Components



- Europe 2004/2005
 - TESS (Biomet)
 - Eclipse Shoulder Prosthesis (Arthrex)
 - Simpliciti (Tornier)
- USA (recently- FDA-IDE)
 - Simpliciti ©
 - Eclipse ©
 - Zimmer Sidus ©
 - No RSA
 - Not convertible

- **Clearly my personal experience limited by availability**






Short Stem v. Stemless Humeral Components

- All present USA Short-stems
 - + platform/convertibility
 - Stems may be more forgiving humeral osteotomy as IM canal guide to placement




Proximal humeral anatomy variable

- Humeral head size
- Version
- Offset and inclination

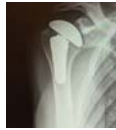
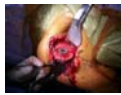
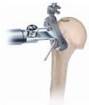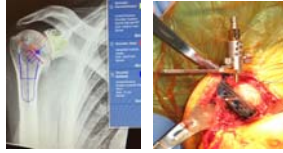Implants must correct for each



Humeral canal facilitates proper Head Component position

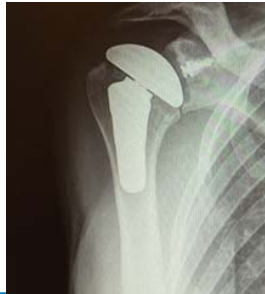- Template to size
- Ream to chatter
- **Sizing IM canal to prevent varus/valgus placement**
- IM humeral cutting guide
- Allows for offset



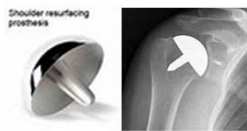Varus placement of Stemless → overstuffing GH or tuberosity overhang



- Now most 3rd generation Shoulder Arthroplasty Implants have evolved to;
- Much shorter lengths
 - better re-create pre-morbid anatomy,
 - improve fixation
 - preserve bone
 - facilitate revision when necessary- convertible
 - limit technical complications



Stemless humeral components-not surface replacements



- Difficult glenoid exposure
- Preserved humeral bone stock







Easier glenoid exposure



Stemless humeral components


- Europe since
 - TESS (2004)
 - Eclipse (2005)
 - Simpliciti, USA
- Humeral osteotomy
 - Easier access to glenoid
 - Preserves proximal bone stock
 - Decrease risk of periprosthetic Fx
- Allows for anatomic version and inclination
- **Fixation issues?**






 WHERE THE WORLD COMES TO GET BACK IN THE GAME

Stemless humeral components

- Contraindications
 - Proximal bone support;
 - RA
 - Fx
 - Osteoporosis and cysts
 - Females > 70?
- Can not be used in revision of stemmed implant, Fx Non-union


 WHERE THE WORLD COMES TO GET BACK IN THE GAME

Small-stems can work as a humeral platforms for any type implant and shaft deformity

Humeral
Proximal Stem
Epiphysis
Distal
Proximal Stem
Distal

Flexibility to Handle Most Primary Options, and many revisions HA→TSA, TSA→RSA

Humeral deformity

Short Stem v. Stemless Humeral Components

- **Much longer term experience in Europe**
 - Many studies stemless = to stem clinically
 - Most are Mid to Short-term F/U **especially X-Ray**
 - - Spranz et al BMC Musculoskel. Disorders 2017
 - Clinical and Radiographic Outcomes of the Simpliciti Canal-Sparing Shoulder Arthroplasty System:A Prospective Two-Year Multicenter Study
Churchill et al JBJS 2016



Is the humeral stem useful in anatomic total shoulder arthroplasty? **Collin P et al (Walch) Int Orthop 2017**

- 47 pats at @ 2 yr F/U
- Clinical Results = Stemmed implants
- No revisions but;
 - 17 cases radiolucent areas superior and lateral to implant
 - ***"We are unsure as to the nature of the lucent zones... to better understand this radiological phenomenon"***



Is the stemless humeral head replacement clinically and radiographically a secure equivalent to standard stem humeral head replacement in the long-term follow-up? A prospective randomized trial.

Ushok et al (Habermeier) JSES 2017

- 20 pts in Stem v Stemless groups
- No clinical differences
- More radiolucency in Stem group
- No change in position of implants

- ***Both implants showed consistently good functional and radiologic results without a significant difference and achieved an anatomic reconstruction of the humeral head geometry in the coronal plane***



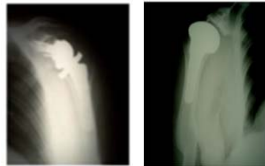Stemless results

- Habermeyer et al JSES 2015
 - 73 mo ROM CS comparable to stem 3rd 4th generation
 - However! **39.1% upward migration of implant, partial osteolysis under cranial part of implant** associated with osteolysis in glenoid component loosening was seen to equal that in stemmed
- Radiolucency in Stemless Shoulder Arthroplasty in Associated With an Imaging Phenomenon Hudeck et al (Gohlke) 2017 JOR
 - Radiolucency may be related to amt of radiation
 - But halo effect more pronounced in bones with decreased density



Mini-stem Humeral Component; Results

- Biomet Comprehensive@System
- TSA and RSA
- Comparable good-excellent results
- No radiologic evidence of loosening @ ave. 5 yrs
- < 3% malalignment
- Minimal lucent lines
- No proximal osteolysis



Throckmorton, T, Zarkadas, P Sperling, J, Cofield R, CORR 2010
Jost, P, Dines, JS, Griffith, M, Angel, M., Altchek, DA, and Dines, DM; HSS J 2011
Giuseffi, SA Streubal P, Sperling, J Sanchez-Sotelo; JBJS 2014



Small

Short-term clinical outcome of an anatomic short-stem humeral component in total shoulder arthroplasty.
 Romeo et al JSES 2018


- Arthrex- Eclipse SA©
 - 64pts ave age 64 @ 4 yrs
 - Clinical improvements all indices without any loosening (CS, SST, Visual) Ave FE 149 degrees
 - TSA with an anatomic press-fit short-stem humeral component is associated with significant improvements in clinical outcomes, without evidence of component loosening at short-term follow-up.



Smaller

Microstems

- Personal experience
 - 349 microstems – 298 TSA / 51 RSA
 - 12- 68 mos
 - No loose components
 - No subsidence/ change in position
 - Minimal lucent lines
 - Proximal osteolysis < 3%
 - None revised for loosening



Submitted to JSES Smallest

HOSPITAL FOR SPECIAL SURGERY WHERE THE WORLD COMES TO GET BACK IN THE GAME


My opinion

- More is less but I choose smaller stems now
 - Contemporary Stems have worked very well
 - Short humeral stems have specific advantages
 - Stemless (USA)- not convertible
 - All FDA approved Short stem components convertible
 - Stemless humeral cut must be perfect
 - Varus position stemless may lead to overstuffing joint and tuberosity overhang
 - Stemmed humeral component corrects for imperfect osteotomy because IM canal can act as guide for proper implant placement


HOSPITAL FOR SPECIAL SURGERY WHERE THE WORLD COMES TO GET BACK IN THE GAME

“Short” and “Sweet”

- I like micro-stem technology
- I do believe that stemless will become more popular with time and conversion to RSA




HOSPITAL FOR SPECIAL SURGERY WHERE THE WORLD COMES TO GET BACK IN THE GAME



Mini Stem Arthroplasty Indications


- Primary Arthritis with sufficient bone stock
 - OA; AVN; RA
- Mid shaft malunion or stemmed TER
- Contraindicated in case of proximal bone loss or deformity
 - Fracture; tumor; metabolic bone diseases



HOSPITAL FOR SPECIAL SURGERY WHERE THE WORLD COMES TO GET BACK IN THE GAME

Some Specific Cases

May be more amenable to one length or the other



HOSPITAL FOR SPECIAL SURGERY WHERE THE WORLD COMES TO GET BACK IN THE GAME
