

Current Solutions in Orthopaedic Trauma

Case Presentation: Comminuted Fracture of the Proximal Ulna

Melvin P. Rosenwasser, MD
Robert E. Carroll Professor of Surgery of the Hand
Chief, Orthopaedic Hand and Trauma Service
Director, Trauma Training Center

NewYork-Presbyterian
COLUMBIA UNIVERSITY
DEPARTMENT OF ORTHOPEDIC SURGERY
College of Physicians & Surgeons

Disclosures

Consultant – Stryker, Acumed, Allosource, NewClip

NewYork-Presbyterian
COLUMBIA UNIVERSITY
DEPARTMENT OF ORTHOPEDIC SURGERY
College of Physicians & Surgeons

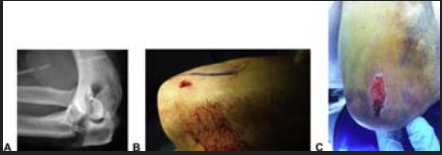
Comminuted Fractures of the Proximal Ulna

- Surgical Strategy
- Implant Choice

NewYork-Presbyterian
COLUMBIA UNIVERSITY
DEPARTMENT OF ORTHOPEDIC SURGERY
College of Physicians & Surgeons

SURGICAL TECHNIQUE
Surgical Techniques of Olecranon Fractures
James A. Wilton, MD, MEd, PhD, FRCRCS(Ed), MD

Incorporate open wound with incision or ignore?



A,B: Grade 1 open lesion from a dorsal cortex spike that required a modified approach to avoid the damaged skin
C: Pressure wound from a splint that

Proximal Ulna fractures

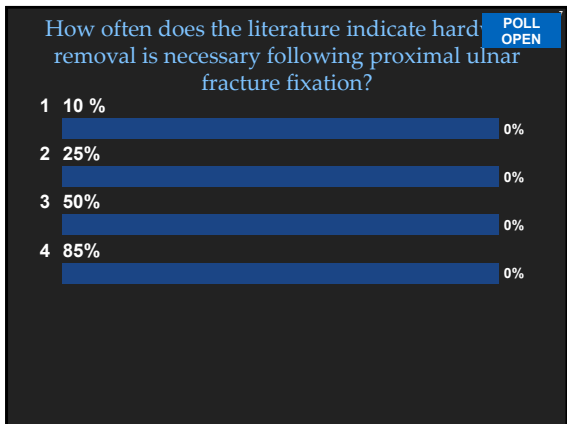
- Come in various combinations
- Typical Olecranon fracture +/- comminution at articulation
- Associated with a fracture dislocation
- Principles- Use the least amount of hardware that will stabilize the fx to minimize the encroachment on the olecranon fossae and triceps mechanism

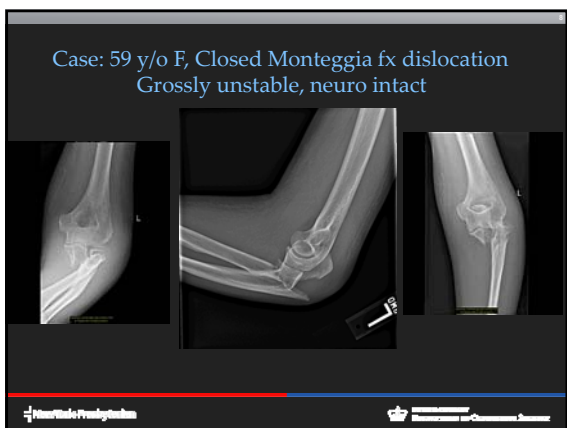
© 2017 Elsevier Inc. All rights reserved. | Department of Orthopaedic Surgery

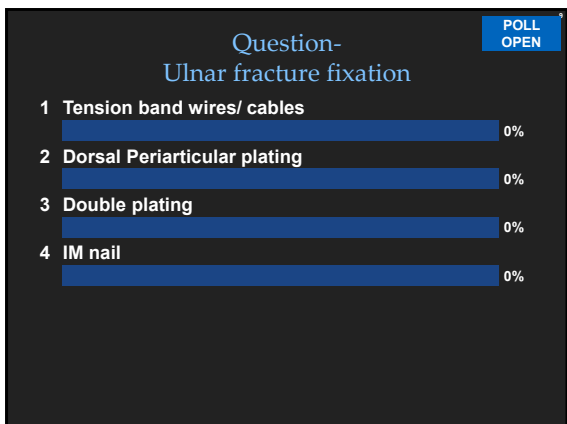
Implant?

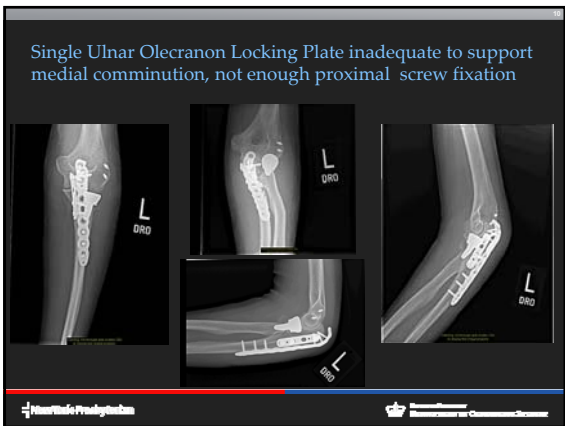
- Tension band wiring or what I prefer tension band cabling for any olecranon fracture, (defined as being proximal to the coronoid process)
- Single dorsal periarticular plate, with locking capability, for any fracture distal to coronoid including shaft
- Double plating with standard locking plates, posterior and medial

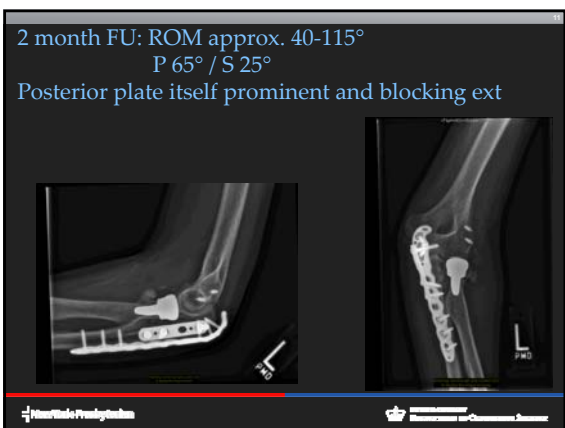
© 2017 Elsevier Inc. All rights reserved. | Department of Orthopaedic Surgery









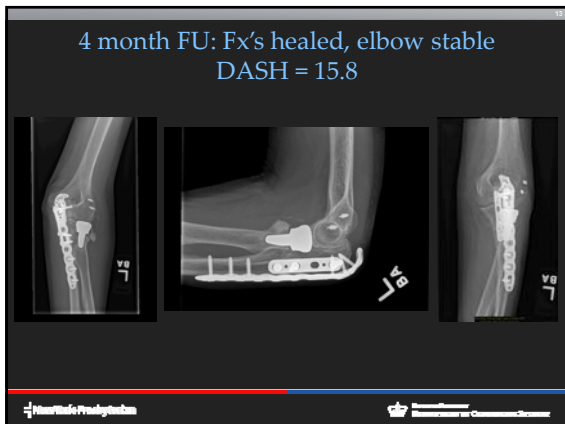


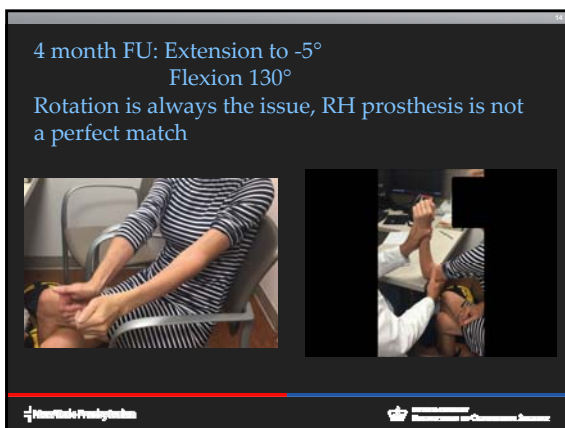
Question- POLL OPEN

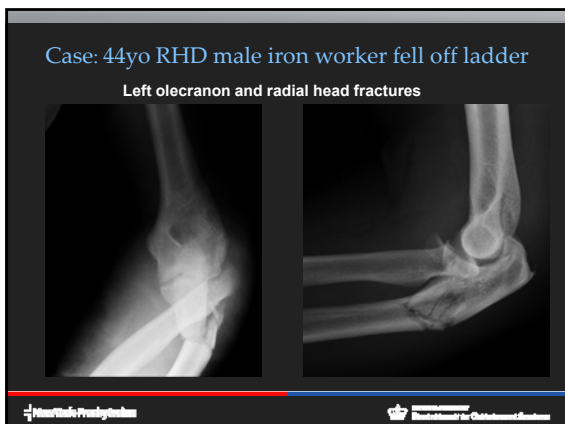Approach to place posterior Prox Ulnar Plate

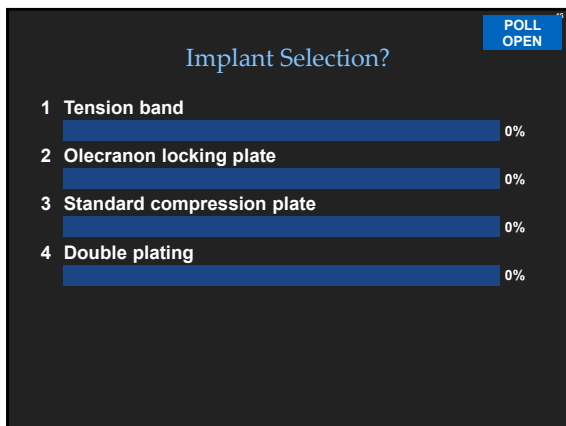
- 1 Posteromedial with in situ ulnar nerve release 0%
- 2 Posterolateral 0%
- 3 Straight midline 0%
- 4 Any of the above with a triceps split to allow for better plate bone contact 0%

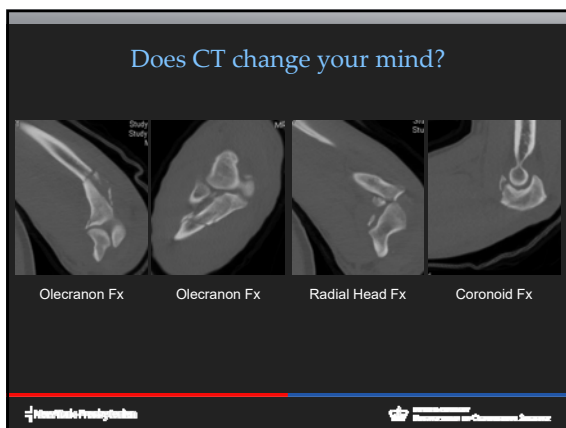
12

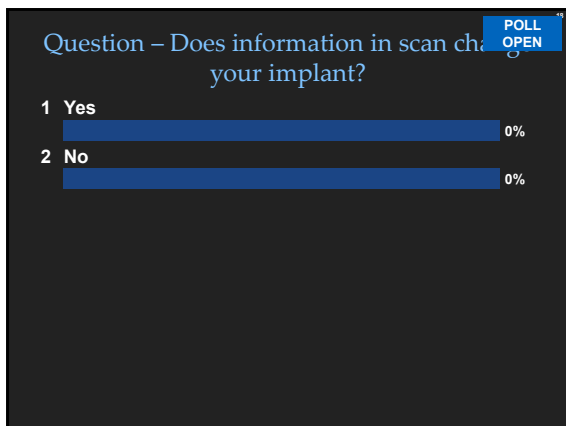


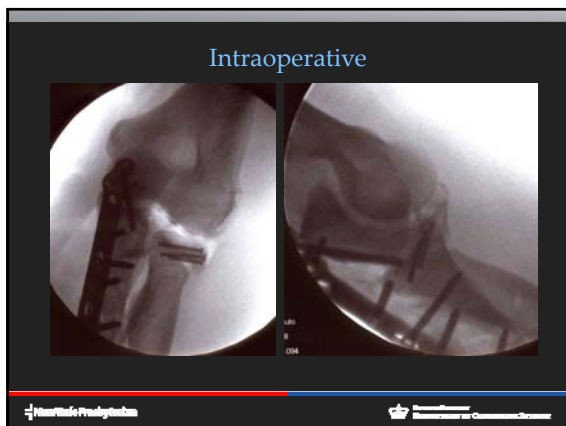

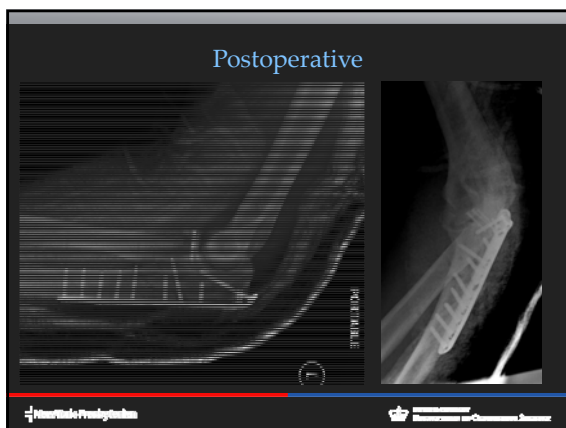


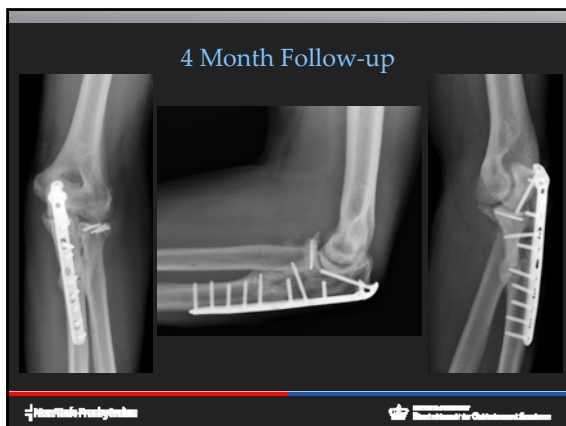












11 Month Clinical Follow-up

No Pain

- Elbow ROM: -5° to 130°
- Supination: 60°
- Pronation: 80°


Hennepin Orthopedic Institute Department of Orthopedic Surgery

Case: 70 y/o RHD F

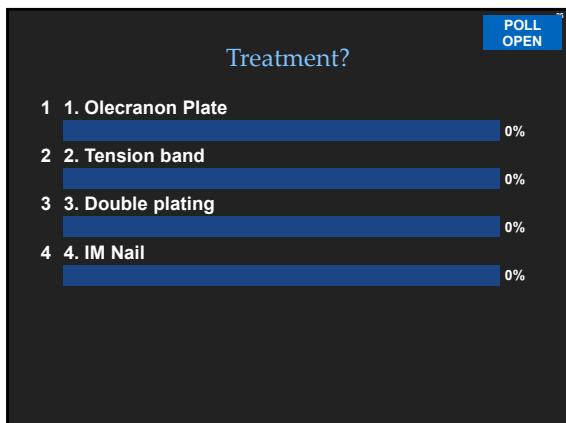
- Retired admin assistant sustained ground-level fall onto non-dominant elbow
- Active in community, avid pianist, desired full restoration of motion

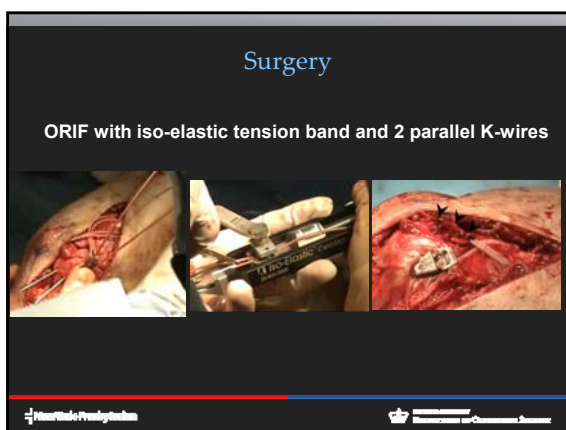
Hennepin Orthopedic Institute Department of Orthopedic Surgery

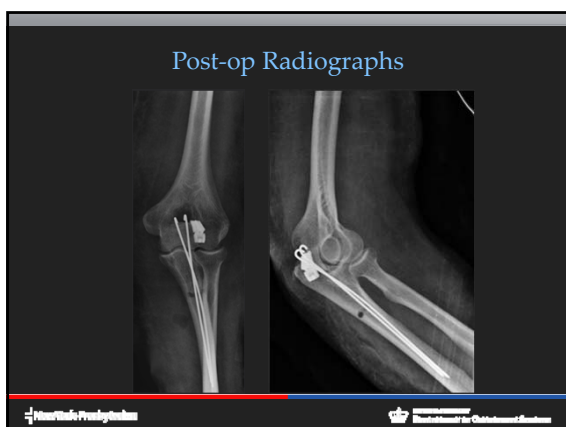Displaced Olecranon comminuted
Rx?

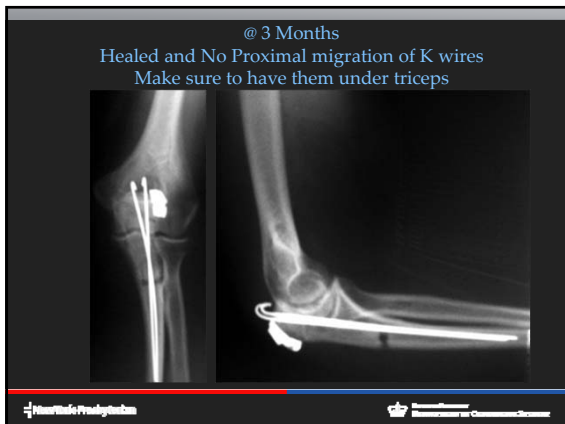

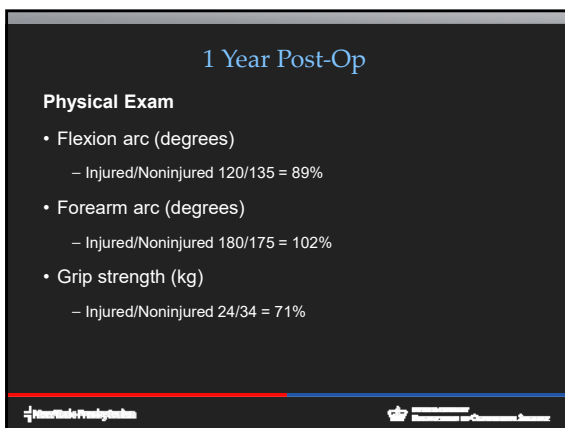
Hennepin Orthopedic Institute Department of Orthopedic Surgery

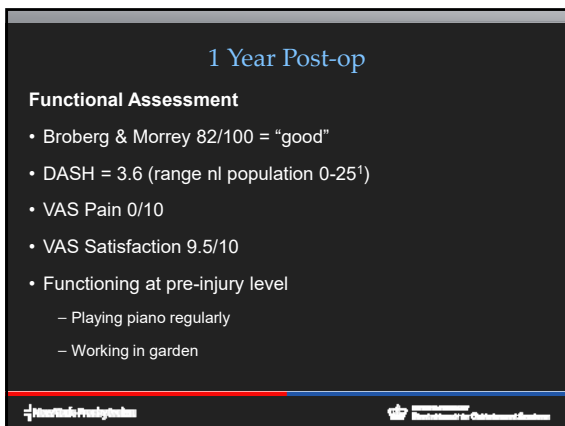


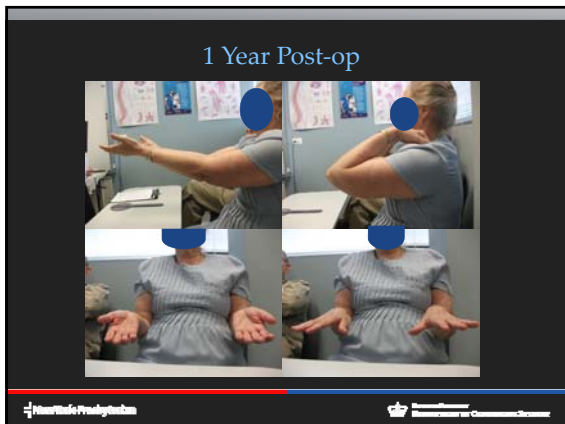


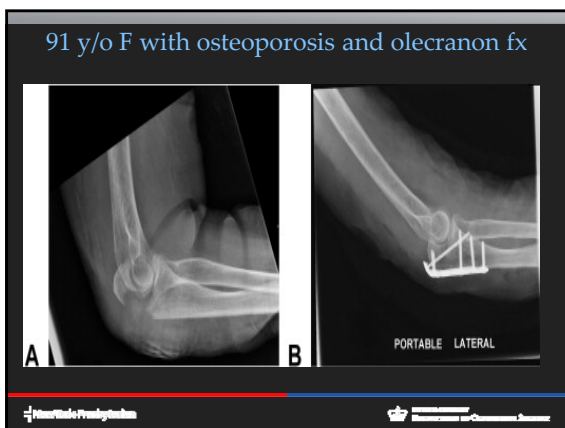


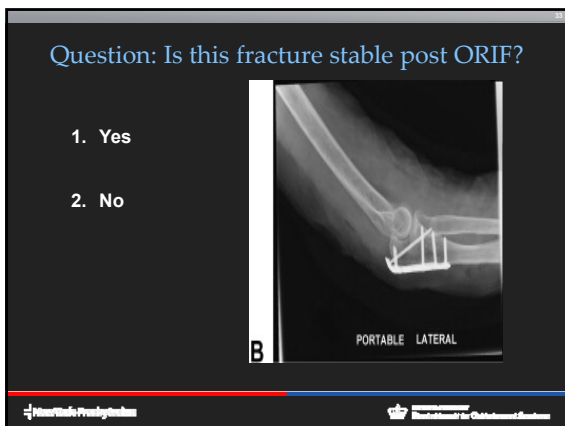


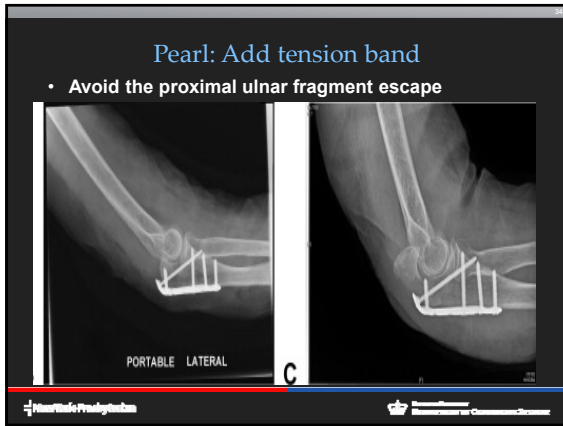


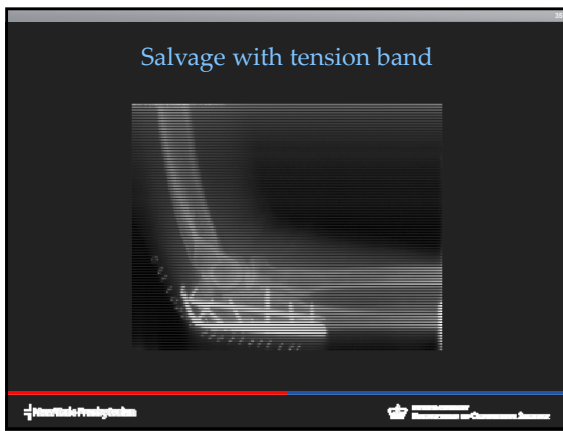


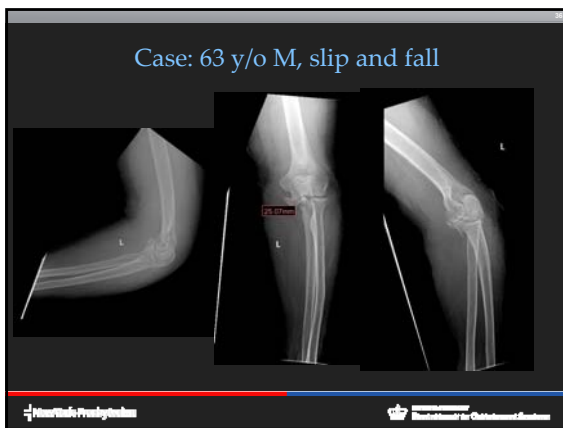











Question: Implants?

POLL OPEN

1	1. Tension band	0%
2	2. Olecranon plate	0%
3	3. Double plate	0%

Immediate post-op
Coronoid fx not addressed

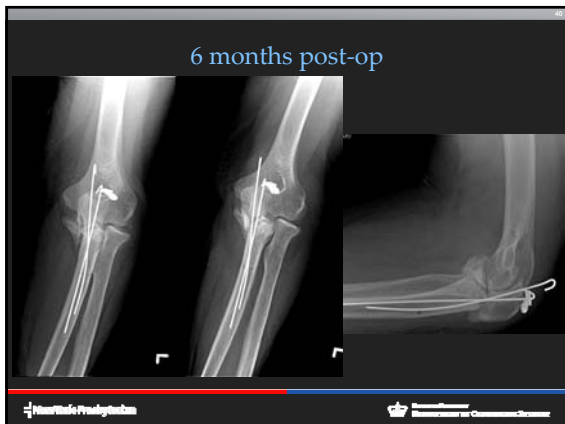

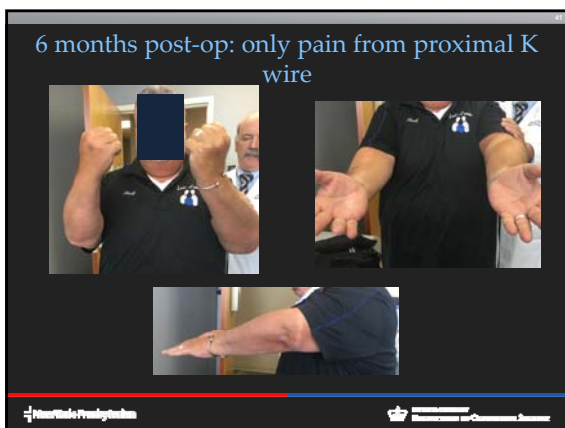© 2017 Elsevier Inc. All rights reserved.

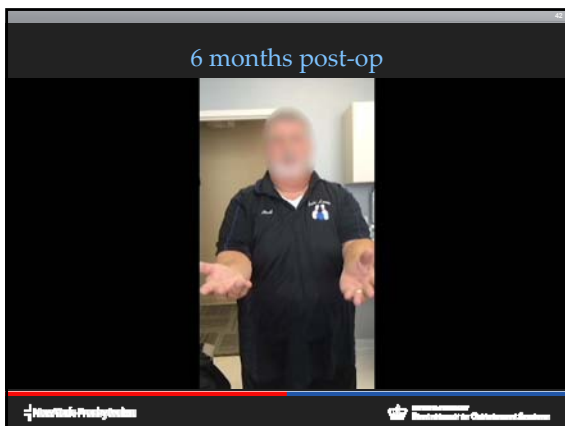
Question: Is this fixation adequate?

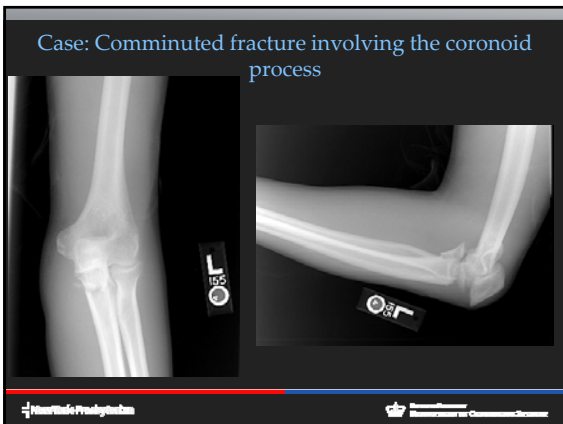
POLL OPEN

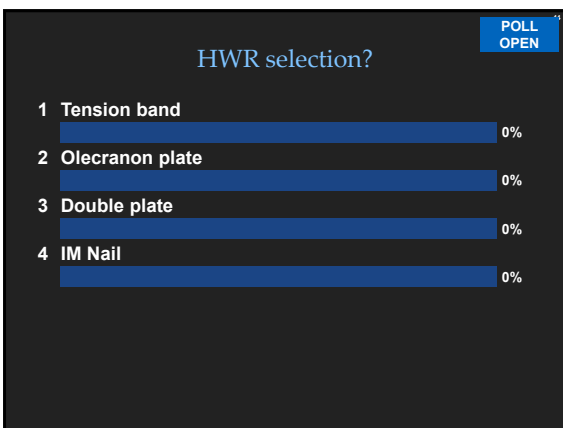
1	Yes	0%
2	No	0%

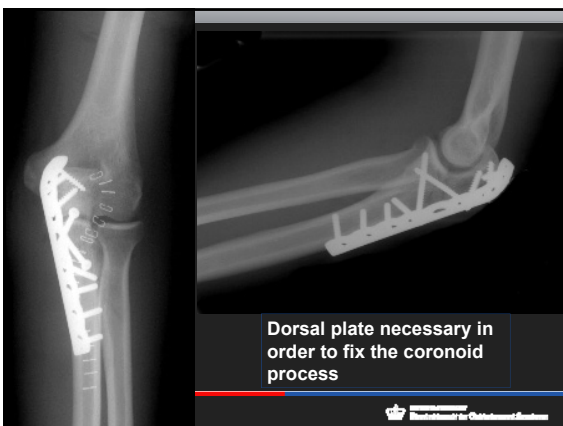


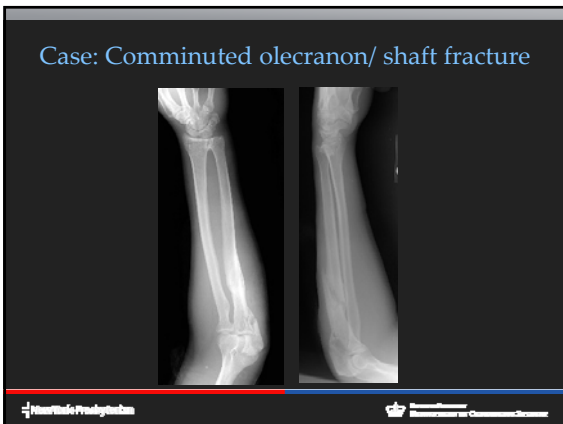

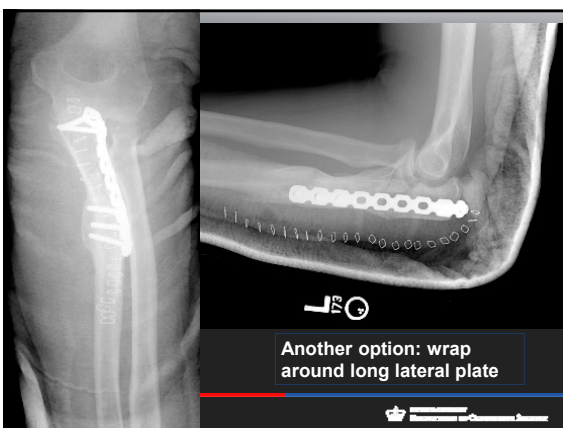



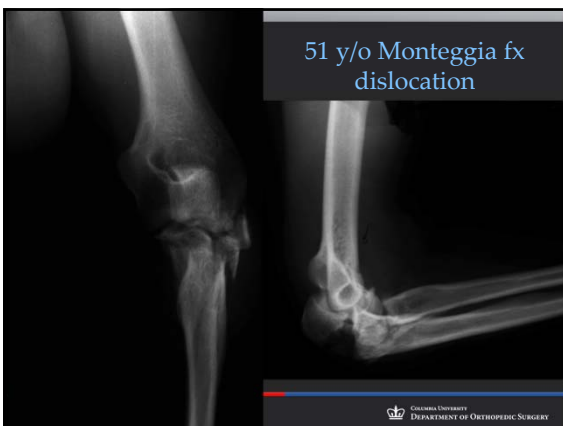


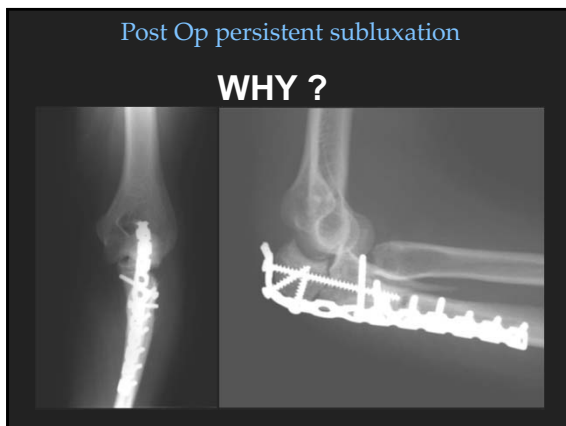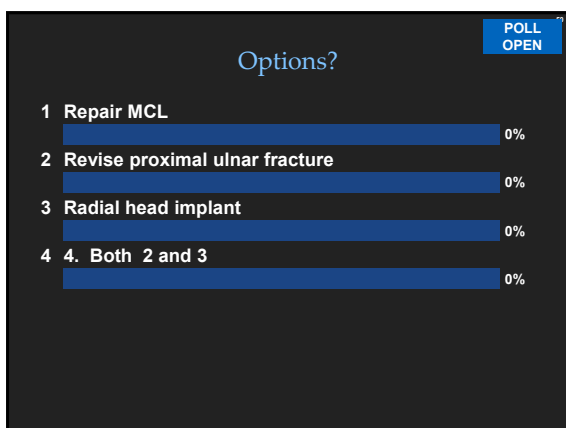


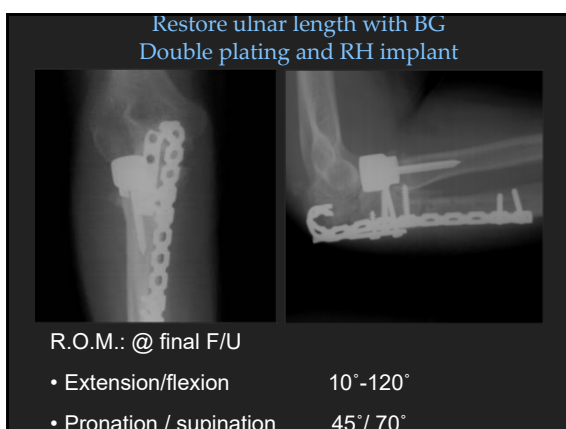









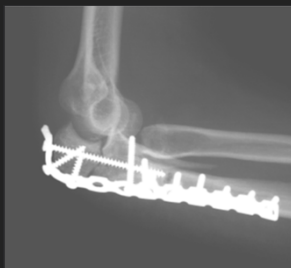


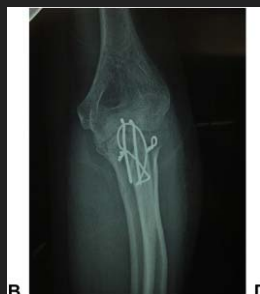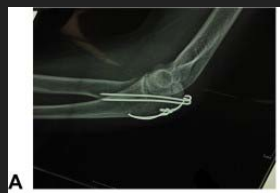Don't throw away proximal bone

- Comminuted proximal ulnar fragments discarded and ulnar curvature mismatched with distal humerus
- No lateral column support with concomitant MCL injury



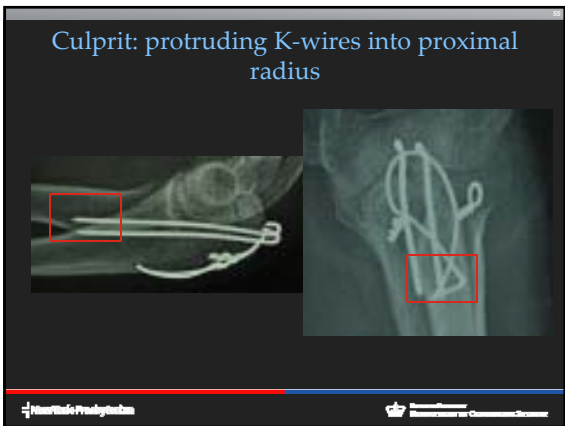
55 y/o F closed olecranon fx: Rx Tension band
No forearm supination- ? RU synostosis

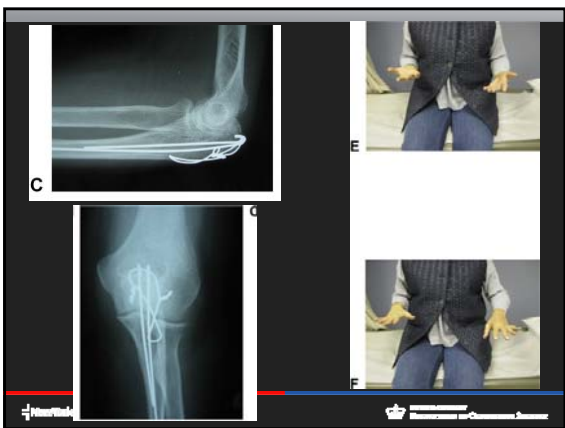

Question: No forearm rotation, Options?

POLL OPEN

- | | | |
|---|-------------------------------|----|
| 1 | Revise tension band | 0% |
| 2 | Excise radio-ulnar synostosis | 0% |
| 3 | Manipulation under anesthesia | 0% |
| 4 | Continue PT | 0% |





Conclusions

1. Critical point is to identify the fracture components
2. Proximal to coronoid with minimal comminution use tension band
3. Distal to coronoid then plating preferred
4. May need more than 1 plate
5. Make sure the plate or wires are placed subtriceps to minimize posterior impingement
6. Don't throw away any intermediate fragments of olecranon or humeral ulnar joint will not be congruent

HandWristFractures.com

