

# Ankle Fractures: Pearls of Treatment

John Ketz, MD  
CSOT 2017

---

---

---

---

---

---

---

---

## Disclosures

- I have no financial disclosures



11/28/2017 2

---

---

---

---

---



---

---

---

## Introduction

- Ankle fractures are extremely common
- Treated by a wide variety of surgeons
- The “intern’s case”



11/28/2017 3

---

---

---

---

---

---

---

---

### Introduction



11/28/2017 4

UNIVERSITY OF ROCHESTER MEDICAL CENTER

---

---

---

---

---

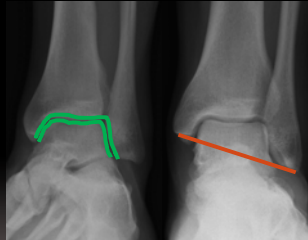
---

---

---

### Imaging – What's Normal

- Symmetric mortise
- Fibular length



11/28/2017 5

UNIVERSITY OF ROCHESTER MEDICAL CENTER

---

---

---

---

---


---

---

---

### Imaging

- Stress radiographs?



11/28/2017 6

Tornetta JBJS 2004

UNIVERSITY OF ROCHESTER MEDICAL CENTER

---

---

---

---

---

---


---

---

### Imaging

Weight Bearing radiographs

Is the fracture unstable under physiologic loads?



11/28 7

---

---

---

---

---


---

---

---

### Advanced Imaging

- CT
  - Good for complex injury patterns



11/28 8

---

---

---

---

---


---

---

---

### Instability

- Loss of normal anatomical relationships at rest or under physiologic loading



11/28/2017 9

---

---

---

---

---

---

---

---

### Decision Making

Stable      Unstable

Conservative Tx      Operative Tx

11/28/2017      10

---

---

---

---

---

---

---

---

### Timing

Injury

What Happens?      Soft Tissue Improves

Partial Healing

Definitive Fixation

11/28/2017      11

---

---

---

---

---

---

---

---

### Timing

- Beware of the dislocations!

11/28/2017      12

---

---

---

---

---

---

---

---

### Incisions

- Lateral
- Medial
- Posteromedial
- Posterolateral
- Percutaneous

11/28/2017 13

---

---

---

---

---

---

---

---

### Lateral Malleolus

- Traditional Lateral Approach
  - Relatively safe



11/28/2017 14

---

---

---

---

---


---

---

---

### Lateral Malleolus

- Percutaneous plating
  - Limited incisions
  - Good for soft tissues



11/28/2017 15

---

---

---

---

---

---

---

---

### Length is Important

11/28/2017 16

---

---

---

---

---

---

---

---

### Lateral Malleolus

- Can use Intramedullary Fixation
  - Limitations

11/28/2017 17

---

---

---

---

---

---

---

---

### Medial Malleolus

- Screw Fixation
  - Standard 2 screws
    - Solid
    - Cannulated
    - Fully threaded

11/28/2017 18

---

---

---

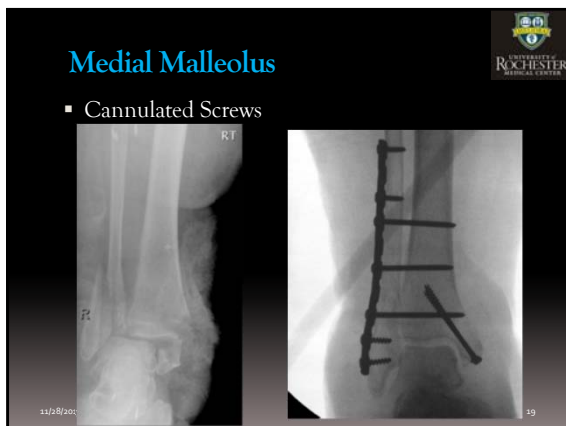---

---

---

---

---



---

---

---

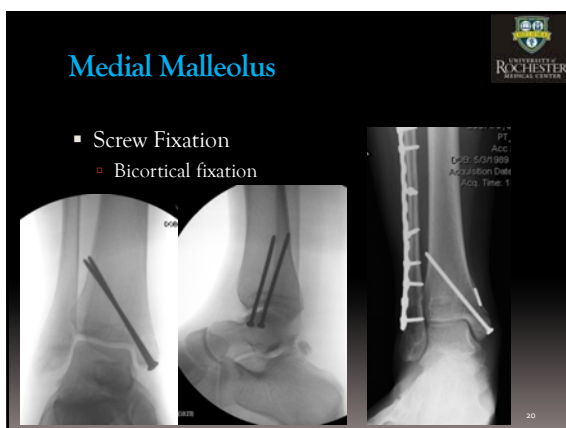
---

---

---

---

---



---

---

---

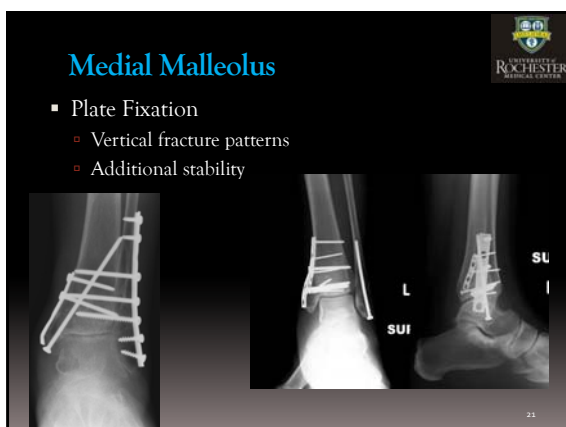
---

---

---

---

---



---

---

---

---

---


---

---

---

### Medial Malleolus

- Medial Incision



11/28/2017 22

UNIVERSITY OF ROCHESTER MEDICAL CENTER

---

---

---

---

---

---

---

---

### Medial Malleolus

- Medial Clear Space



11/28/2017 23

UNIVERSITY OF ROCHESTER MEDICAL CENTER

---

---

---

---

---

---

---

---

### Medial Malleolus

- Alternatives
  - K-wire



11/28/2017 24

UNIVERSITY OF ROCHESTER MEDICAL CENTER

---

---

---

---

---

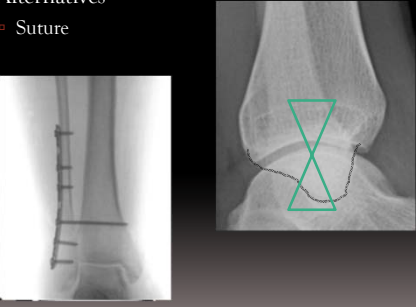
---

---

---

### Medial Malleolus

- Alternatives
  - Suture



11/28/2017 25

---

---

---

---

---

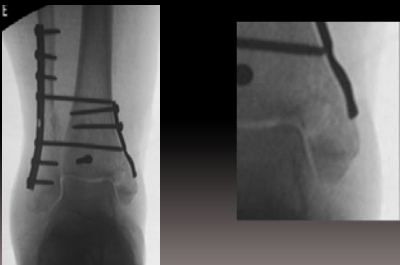
---

---

---

### Medial Malleolus

- Suture Fixation



11/28/2017 26

---

---

---

---

---

---

---

---

### Posterior Malleolar Fractures



11/28/2017 27

---

---

---

---

---

---

---

---

### Posterior Malleolar Fixation

- Timing

11/28/2017 28

---

---

---

---

---

---

---

---

### Ankle Fractures

- Percutaneous

**P to A BIOMECHANICALLY BETTER**

11/28/2017 29

---

---

---

---

---

---

---

---

### P to A Screw

11/28/2017 30

---

---

---

---

---


---

---

---

**P to A Screw**

NO. SANDRA  
MCL. F.



**Measure at  
Posterior  
Cortex**

11/28/2017 31

---

---

---

---

---

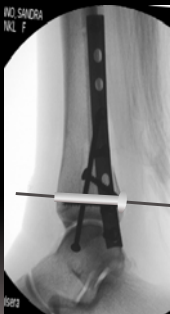
---

---

---

**P to A Screw**

NO. SANDRA  
MCL. F.



**Drive K-wire  
Posteriorly**

**Place screw P  
to A**

11/28/2017 32

---

---

---

---

---

---

---

---

**Following fixation....**

- Don't forget to stress



11/28/2017 33

---

---

---

---

---


---

---

---

### Following fixation....

- Don't forget to stress



11/28/2017 34

---

---

---

---


---

---

---

---

### Deltoid Insufficiency



11/28/2017 35

---

---

---

---

---

---

---

---

### Role of External Fixation



11/28/2017 36

---

---

---

---

---


---

---

---

### Role of Arthroscopy?

- High incidence of talar injury
  - 63% *Ferkel Arthroscopy 2002*
- Most are Medial



*Bonassia JAAOS 2011*

11/28/2017 37

---

---

---

---

---

---

---

---

### Special Considerations

- Diabetics/Neuropathy
  - Need more & bigger fixation
  - Prolonged NWB



11/28/2017 38

---

---

---

---

---


---

---

---

### Diabetics/Neuropathy

- Diabetics/Neuropathy
  - Alternative Treatments
  - Increased risk of complications



11/28/2017 39

---

---

---

---


---

---

---

---

### Diabetics/Neuropathy



11/28/2017 40

---

---

---

---

---

---

---

---

### Aftercare

- Splint x 2 weeks
- Boot at 2wks to allow ROM
- Weightbearing a 6 wks in Boot
  - May consider brace for simpler patterns
- Brace and therapy at 10 weeks
  - May consider therapy sooner for stiffness

11/28/2017 41

---

---

---

---

---

---

---

---

### Complications

- Wound healing problems
- Failure of fixation
- Malunion
- Infection
- Nonunion
- RSD/Superficial Peroneal n.



11/28/2017

---

---

---

---

---

---

---

---

**Outcomes**

- Most people do well after ORIF  
*Porter FAI 2008*
- Fracture dislocations worse  
*Warner FAI 2015*
- Geriatric patients have higher complication rate  
*Anderson FAI 2008*
- Diabetics have much higher complication rate  
*Wikich JBJS 2008*

11/28/2017 43

---

---

---

---

---

---

---

---

**Summary**

- Multiple factors play into determining ORIF
- Select best technique/incision for fixation on an individual basis
- Goal is to provide stability and articular reduction
- Be respectful and humble

11/28/2017 44

---

---

---

---

---

---

---

---