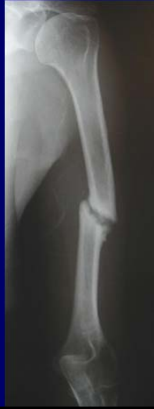

Non-Union : Alternatives to Bone Grafting in 2017

Michael D. McKee, MD, FRCS(C)

Professor and Chair,
Department of Orthopaedic Surgery
University of Arizona, College of Medicine,
Phoenix, Arizona

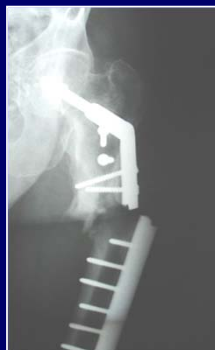

Disclosure

- OTA, COA, ASES, Zimmer, Wright Medical
- research funds and institutional support
- Zimmer, Bioventus
- consultant
- Stryker, ITS
- consultant, royalties

Orthobiologics: Options and Outcomes


- Confusing field for the practising orthopaedic surgeon
- Multitude of materials available
- Very few prospective or randomized studies
- Not a routine part of training programmes
- What (or who) to believe?



Autogenous bone graft


- Osteogenic
- Osteoconductive
- Osteoinductive
- Structural

Structure + biology = autogenous graft



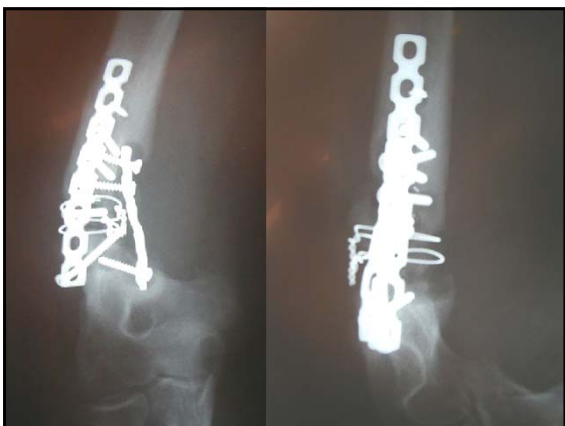ICBG

- Infection
- Hematoma
- Nerve injury
- Fracture
- Pain
- Morbidity
 - short term
 - long term



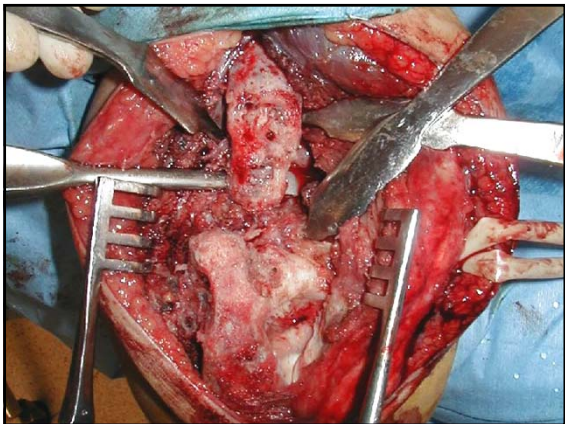
Distal Humeral Nonunion

- 28 yr old male
- Works on loading dock
- Prior OR 14 months ago
- Weak, painful, unstable elbow
- Posterior incision, no evidence of infection



Operative tactics



- Removal of implanted hardware
- Debridement of nonunion to bleeding bone
- Correction of deformity
- Stable internal fixation
- Addition of biologic to nonunion site

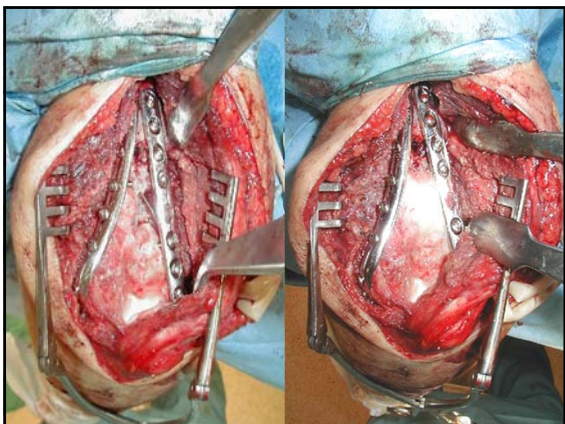


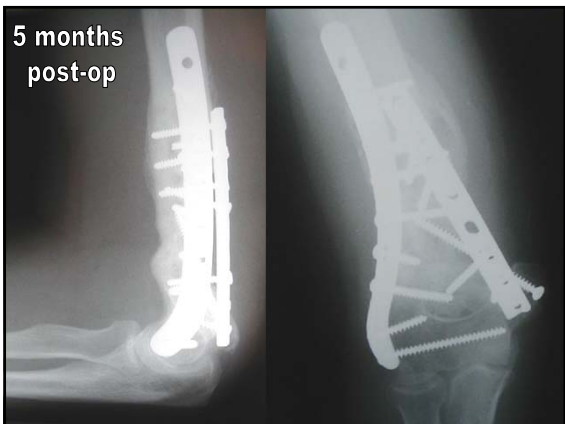
rhBMP-7 Implant Preparation



- 1 Open package using sterile technique.
- 2 Remove top. Add 2-3 cc of sterile saline
- 3 Allow to reconstitute. Place into desired area.








Prospective Nonunion Study – Single Surgeon

- 94 patients
- Age: 55 years (range: 28 to 79 years)
- All atrophic, aseptic nonunion
- 47 smokers, 64 medical comorbidities
- Mean: 2.1 prior operative interventions (range: 0 to 7)
- 32 patients had failed autogenous iliac crest bone grafting
- No autograft or other bone substitute used



Results

- 94 patients
- 15 lost to follow-up
- 79 patients followed to definitive outcome
- 3 early mechanical failures
- 6 nonunions at one year
- 70 /79 healed after index procedure (89%)

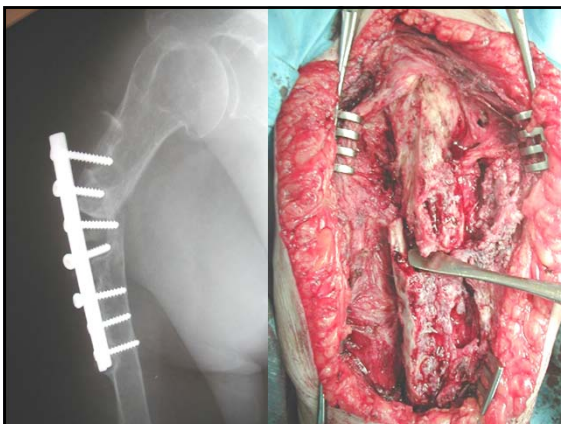
- Mean follow-up was 26 months (range: 12 to 62 months)

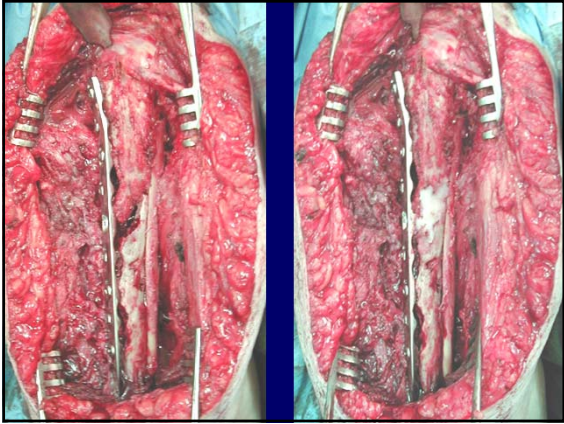
Evidence

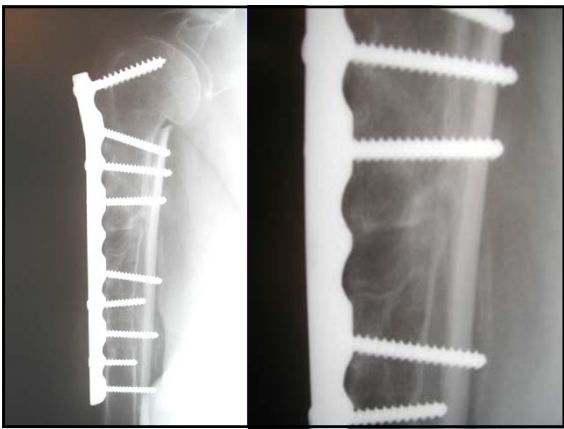
- There is good evidence to support the use of a BMP compound to a long bone nonunion to promote healing

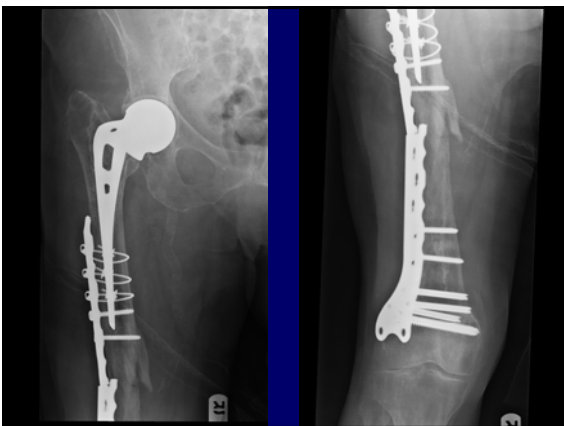Humeral Shaft Nonunion

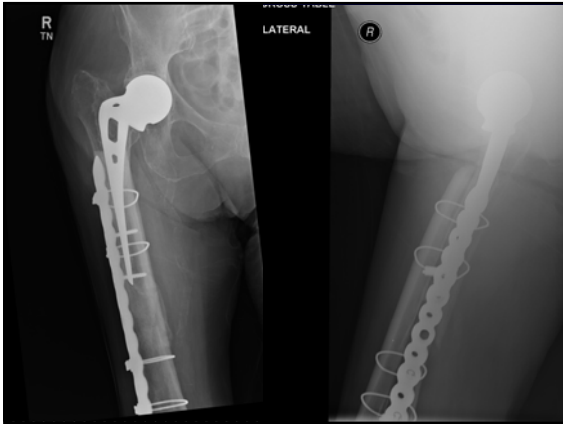
- 75 yr old female
- First surgery: ORIF
- Failed @ 7 months post-op
- Second surgery ORIF and “bone substitute” eleven months ago
- Sudden pain, deformity
- Medically stable, nonsmoker
- Transferred for definitive care





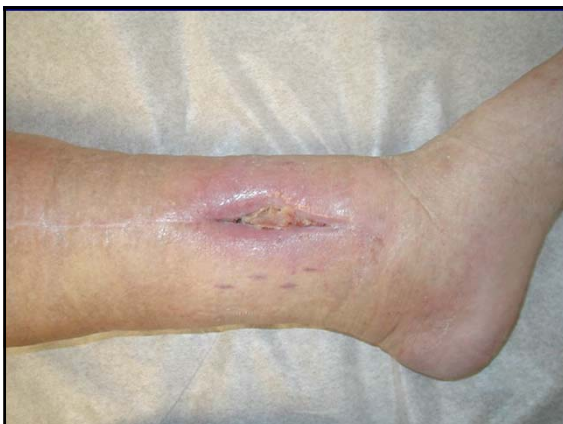





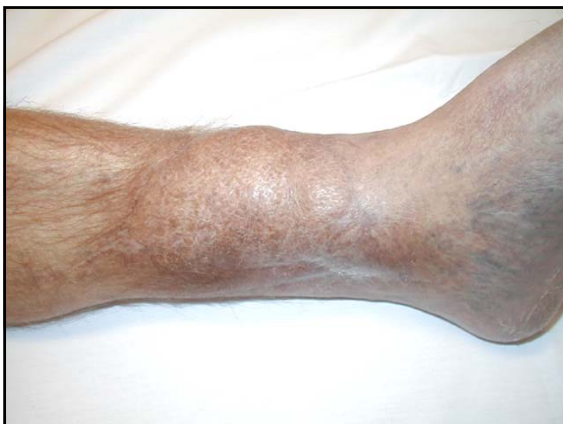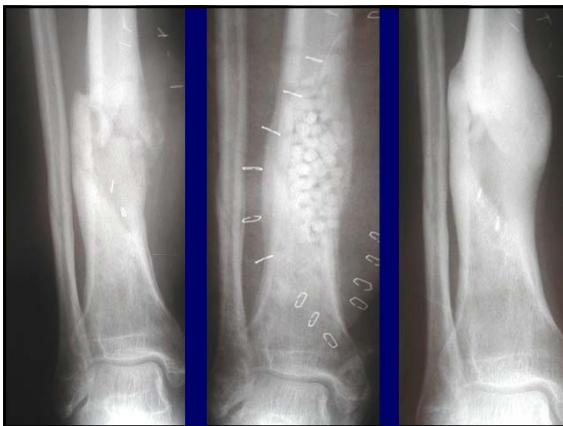Evidence

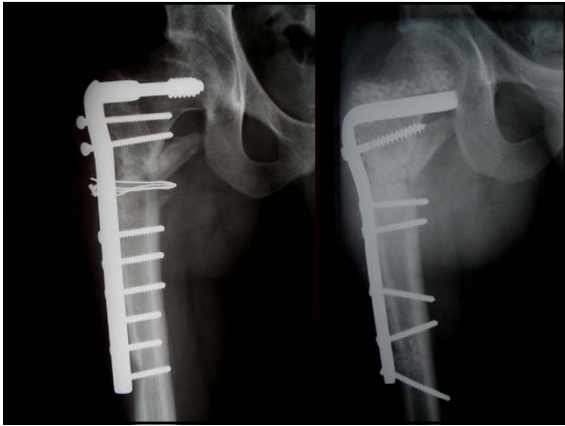- There is good evidence to support the use of an allograft strut to enhance mechanical support and add bone stock in recalcitrant long bone nonunions, especially the humerus and peri-prosthetic femur.

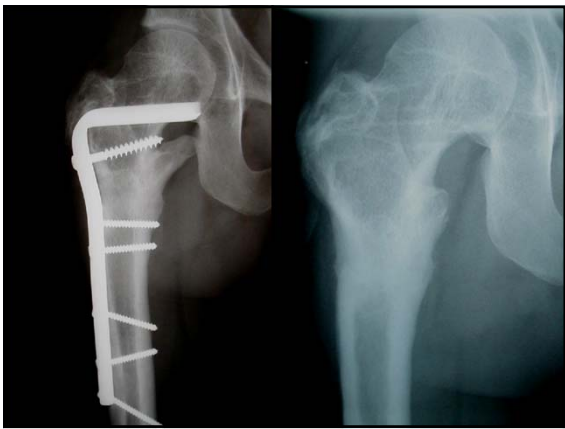


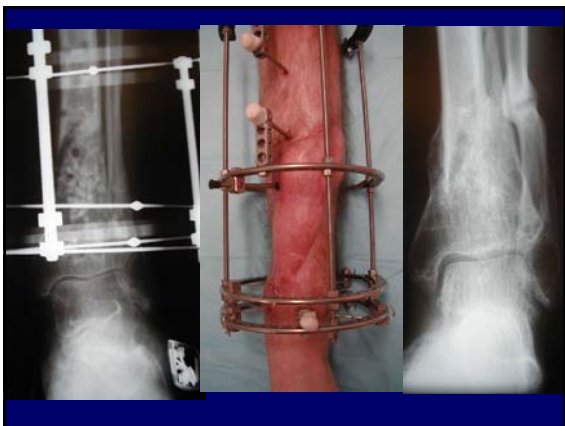
Calcium sulphate-hemihydrate

- Medical grade calcium sulphate-hemihydrate
- Basic crystalline structure similar to bone
- Resorbs at constant rate
- Osteoconductive, not osteoinductive or osteogenic
- Impregnated with tobramycin (Osteoset-T)



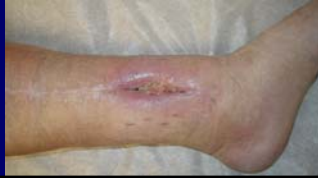





A Randomized Clinical Trial Comparing an Antibiotic Bone Substitute to Antibiotic Bone Cement in Chronic Post-Traumatic Infection

McKee, Schemitsch et al

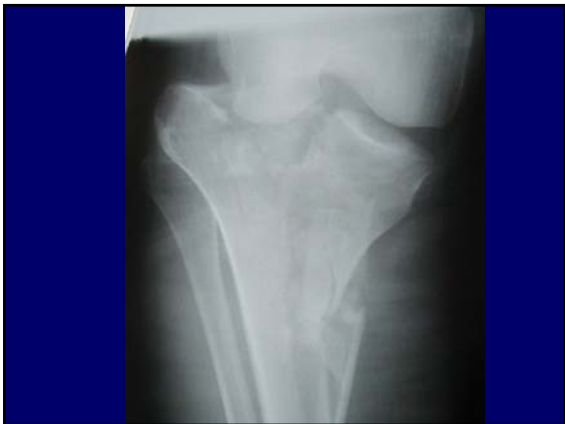

Outcomes

- PMMA Group
 - 1 lost to follow-up
 - 12 / 14 clinically healed
 - ESR 39 → 19
- BBS Group
 - 1 lost to follow-up
 - 12 / 14 clinically healed
 - ESR 32 → 16
- Union achieved in 6/8 patients
- 9 patients required 15 further procedures
- Union achieved in 7/8 patients
- 5 patients required 7 further procedures

Evidence

- There is good evidence to support the use of an antibiotic loaded calcium sulphate compound to infected bony defects and, in certain cases, infected nonunions




Subchondral defects

What am I looking for?

- Void management
- Enhances screw fixation
- Withstands early screw pullout






The Use of Calcium Phosphate Bone Cement in Fracture Treatment
A Meta-Analysis of Randomized Trials

By Sohail S. Rajaram, MChB, MSc, FRCS, Michael Zlowodzki, MD, Amy LeVica, MD, Paul Tornetta III, MD, Thomas A. Einhorn, MD, Richard Buckley, MD, FRCS, Ross Leighton, MD, FRCS, Thomas A. Russell, MD, Sune Larsson, MD, PhD, and Mohit Bhandari, MD, MSc, FRCS

Investigation performed at the Orthopaedic Research Division, Department of Surgery, McMaster University, Hamilton, Ontario, Canada

Summary of Findings Calcium Phosphate

- **Less pain at 1 year**
 - Compared to controls alone (with no bone graft or bone graft substitutes)
 - Upper extremity fractures (distal radius)
- **Reduced risk of losing fracture reduction**
 - Compared to autogenous BG
 - Patients with tibial plateau fractures



Evidence

- There is good evidence to support the use of a Calcium Phosphate cement in a metaphyseal void after reduction of a depressed intra-articular fracture (plateau, calcaneus)

Summary: Biologics in Canada 2017

- BMP or osteo-inductive compound for nonunion
- Allograft strut for mechanical support in nonunion
- Antibiotic CaSO4 in infected defects
- CaPO4 cement in metaphyseal bone voids
