
 BRIGHAM AND WOMEN'S HOSPITAL 

---

**Distal Radial Fracture Fixation:**

**Dorsal Plating for Some**

Philip E. Blazar, M.D.

---

---

---



---

---

---

---

---

 BRIGHAM AND WOMEN'S HOSPITAL 

---

**Distal Radial Fracture Fixation:**

**Dorsal plating for **Some****

Philip E. Blazar, M.D.

---

---

---

---

---


---

---

---



**"Disclosure"**

- "VLPer"
- 2015: AO C3 fractures 106/150 (71%) isolated VLP
  - 24 months <10 Dorsal (45 AO B/C)

AAHS  
DOI: 10.1097/AAH.0000000000000014 

**The use of a single volar locking plate for AO C3-type distal radius fractures**

Brandon L. Eary<sup>1</sup>, Brian Foster<sup>1</sup>, Philip E. Blazar<sup>2</sup>

 BRIGHAM AND WOMEN'S HOSPITAL 

---

---

---

---

---


---


---

---


### Most EA DR# with surgical indication

- CRPP (multiple configurations)
- Ex fix (bridging, non bridging, multiplanar ligamentotaxis)
- VLP
- DLP
- 2 small plates (Fragment specific)
- Spanning plate
- IM nail
- Injectable bone cement
- .....





BRIGHAM AND WOMEN'S HOSPITAL



---

---

---

---

---

---

---

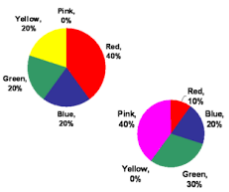
---


---

---


### Dorsal Plate?

- Data?





BRIGHAM AND WOMEN'S HOSPITAL



---

---

---

---

---

---

---

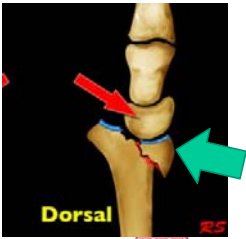
---


---

---


### Dorsal Plate?

- Dorsal buttress
- Dorsal ulnar fragment: RC, RU joints: Reduction or fixation
- Die punch/ impacted fragment with dorsal rim
- Fragment Specific
- Highly comminuted / Poly trauma





BRIGHAM AND WOMEN'S HOSPITAL



---

---

---

---

---

---

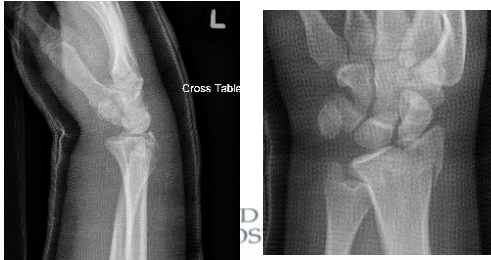
---

---

---

---

**Dorsal Buttress**  
: 18 Y ATV, ipsilateral acetabular fracture. 1 week post "reduction"



---

---

---

---

---

---

---

---

Dorsal Barton's: 18 Y ATV, ipsilateral acetabular fracture. Dorsal and Radial Buttress



BRIGHAM AND WOMEN'S HOSPITAL

---

---

---

---


---

---

---

---

**Highly Comminuted**  
25 yo RHDH – fall 40 ft out of tree.  
High Energy, Small fragments. Open Tibia



---

---

---

---

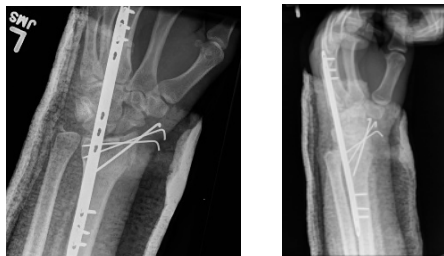
---

---

---

---

OR on hospital day 0



---

---

---

---

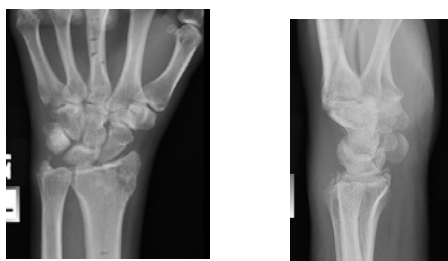---

---

---

---

ROH at 8 wks



---

---

---

---

---

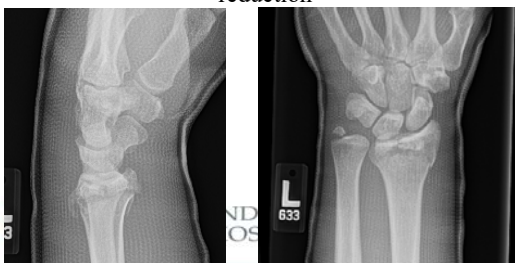---

---

---

**VLP and dorsal fragment hard to reduce from volar**

28 Y male, fell 13 feet, Lost alignment after reduction



---

---

---

---

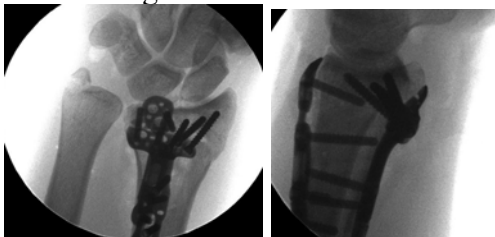---

---

---

---

VLP and dorsal fragment hard to reduce from volar: 28 Y male, fell 13 feet, Lost alignment after reduction



BRIGHAM AND WOMEN'S HOSPITAL



---

---

---

---

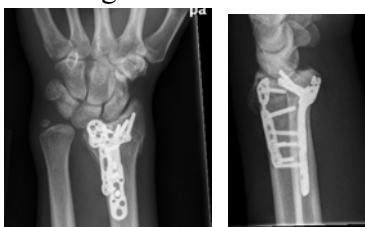---

---

---

---

VLP and dorsal fragment hard to reduce from volar: 28 Y male, fell 13 feet, Lost alignment after reduction



BRIGHAM AND WOMEN'S HOSPITAL



---

---

---

---

---

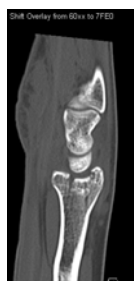---

---

---

### Central Impaction

- Central impaction
- Particularly with a shearing type or dorsal rim injury
- Direct visualization of articular surface
- Bone graft or substitute



BRIGHAM AND WOMEN'S HOSPITAL



---

---

---

---

---

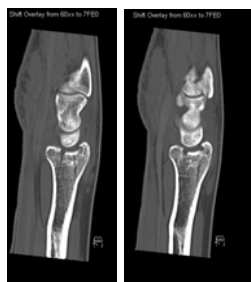---

---

---

### Central Impaction

- 20 RHD Male
- Legs taken out playing basketball



---

---

---

---

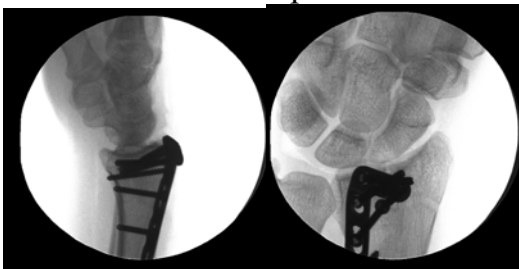
---

---

---

---

### Central Impaction



---

---

---

---

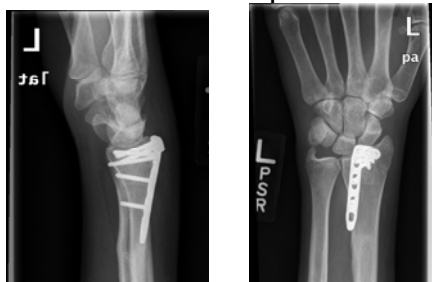
---

---

---

---

### Central Impaction



---

---

---

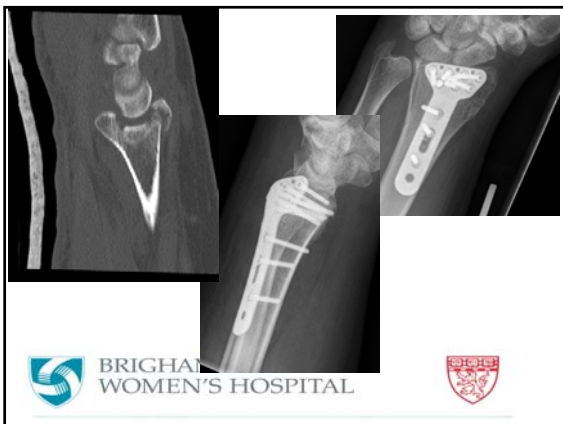---

---

---

---

---



---

---

---

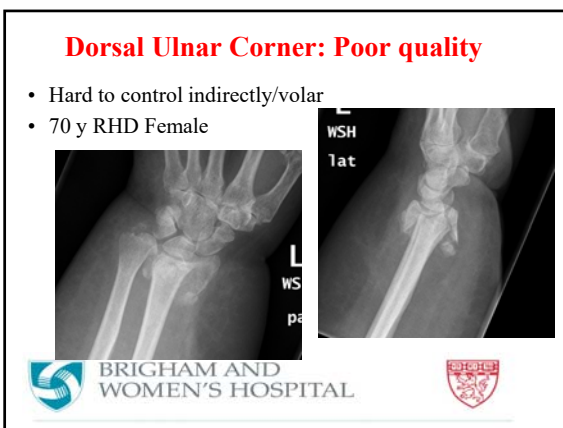
---

---

---

---

---



---

---

---

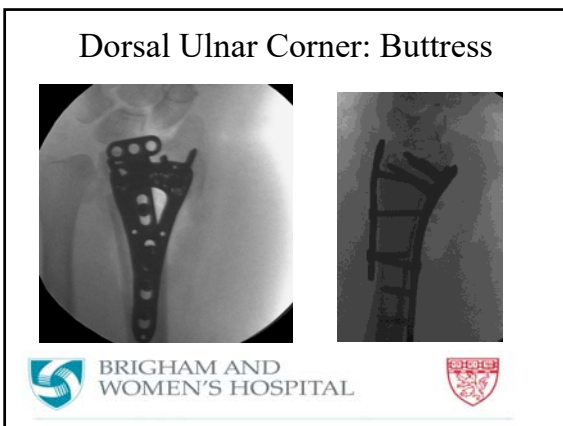
---

---

---

---

---



---

---

---

---

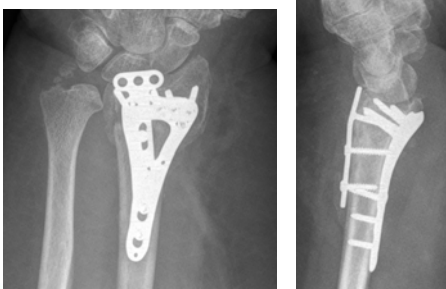
---

---

---

---

### Dorsal Ulnar Corner



BRIGHAM AND WOMEN'S HOSPITAL



---

---

---

---

---

---

---

---

### Dorsal Plating

- Anecdotal observation
- ROH more often
- More OT
- Tendon Problems?



BRIGHAM AND WOMEN'S HOSPITAL



---

---

---

---

---

---

---

---



BRIGHAM AND WOMEN'S HOSPITAL



HARVARD MEDICAL SCHOOL  
TEACHING AFFILIATE

---

---

---

---

---

---



---

---




### Radial Styloid/Fragment Specific

- Radial styloid fractures
- Size
- Buttress



BRIGHAM AND WOMEN'S HOSPITAL



---

---

---

---

---



---

---


---

### Radial Styloid

- Radial styloid fractures
- Size
- Buttress



BRIGHAM AND WOMEN'S HOSPITAL



---

---

---

---

---


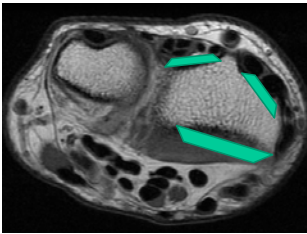
---

---


---

### Pro VLP

- Anatomy (Tendons)



BRIGHAM AND WOMEN'S HOSPITAL



---

---

---

---

---

---

---

---