

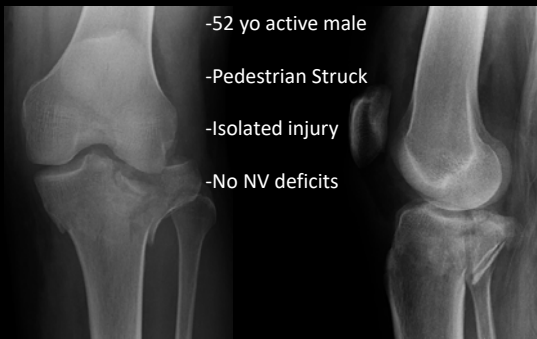Tibia Plateau Fractures: Case Presentations

Frank A. Liporace, MD

VP & Chairman– Dept. Of Orthopaedics
Chief Orthopedic Trauma & Adult Reconstruction
Director Orthopaedic Institute
Jersey City Medical Ctr
RWJ Barnabas Health

Disclosure

- Educational Consultant
 - AO, Stryker, Biomet
- Royalties
 - Biomet
- Design Team
 - Biomet
 - Synthes



What would your next step in management be? POLL OPEN

- 1) ORIF within 6 hours
0%
- 2) CT scan, ORIF within 2 days
0%
- 3) External Fixation, CT scan, ORIF ~ 1 wk or more
0%
- 4) External Fixation, ORIF when time available
0%
- 5) Closed Management
0%

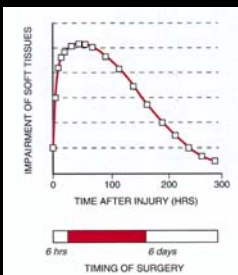- What would your next step in management be?
 - 1) ORIF within 6 hours
 - 2) CT scan, ORIF within 2 days
 - **3) External Fixation, CT scan, ORIF ~ 1 wk or more**
 - 4) External Fixation, ORIF when time available
 - 5) Closed Management

Goals:
-Restore Length
-Relax Soft Tissue

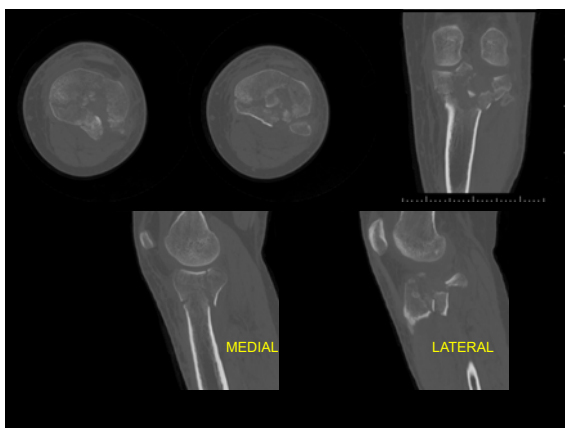Address:
-Axial Instability
-Coronal Instability
-Sagittal Instability

Second Hit

- Patience
- Timing critical
- Avoid 1-6 days
- Await soft tissue envelope (10-21 days)



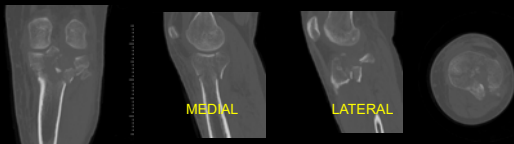
Note: Highest wound complications <7 days after injury (tibia plateau fractures) Wagner HE and Jakob RP: Unfallchirurg 1986



What would your definitive management be?

POLL OPEN

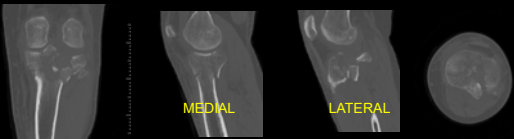
- 1.) Lateral Plating
0%
- 2.) Posteromed Plate then Lateral plate
0%
- 3.) Percutaneous Medial Screws then Lateral plate
0%
- 4.) Percutaneous Reduction and Ringed Fixator
0%



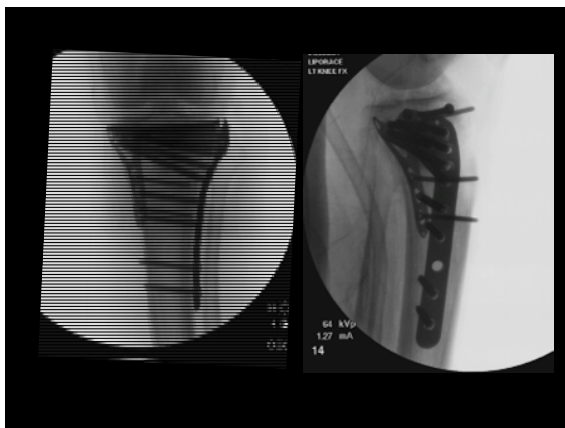
POLL OPEN

What would your grafting preference be?

- 1) None
0%
- 2) Allograft Cancellous Chips
0%
- 3) Autograft
0%
- 4) Calcium Phosphate based graft
0%



MEDIAL LATERAL



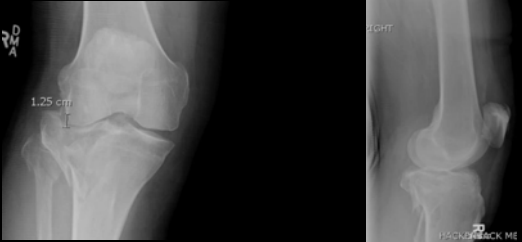
WT

- 78 yo M ped struck
- PMH: HTN, Mitral Valve replacement
- CC: R knee pain

WT POLL OPEN

What to do (order)?

1. -1) ORIF
0%
2. -2) CT scan, ex-fix, ORIF
0%
3. -3) Ex-fix, CT scan, ORIF
0%



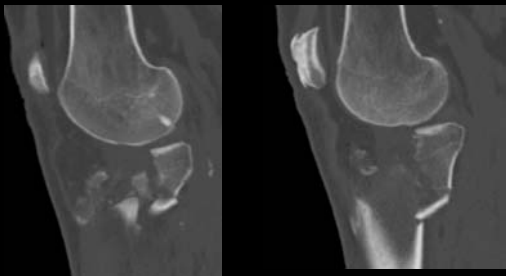
WT



70

unidentified patient file

WT



POLL OPEN


WT- Night 1- Next step?



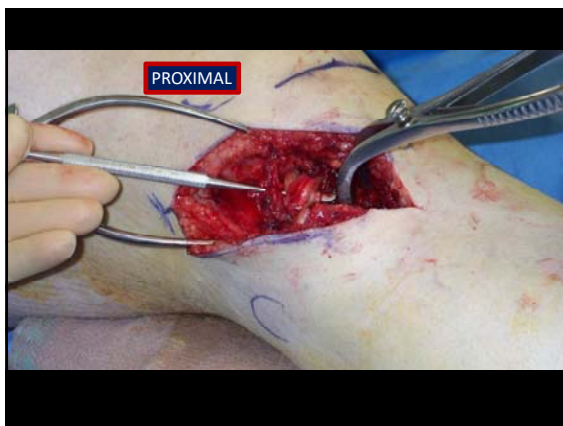1. -1) ORIF – lateral + grafting
0%
2. -2) Definitive spanning ex fix
0%
3. -3) TKR
0%

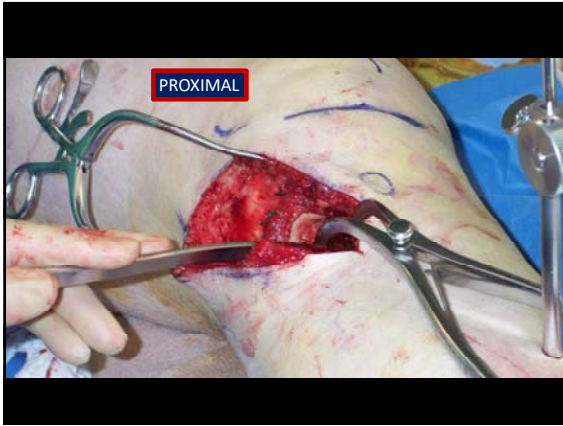POLL OPEN

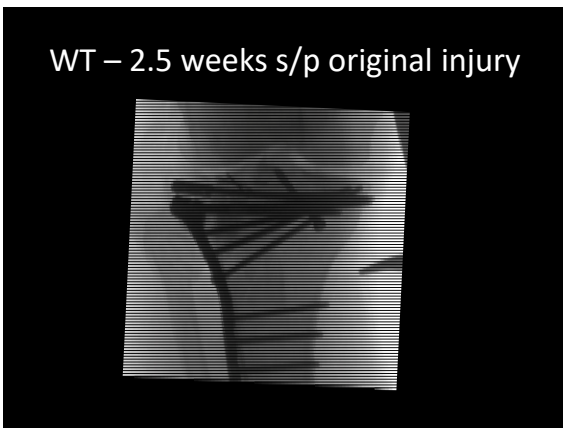
WT- Night 1- Lateral Meniscus Tear?

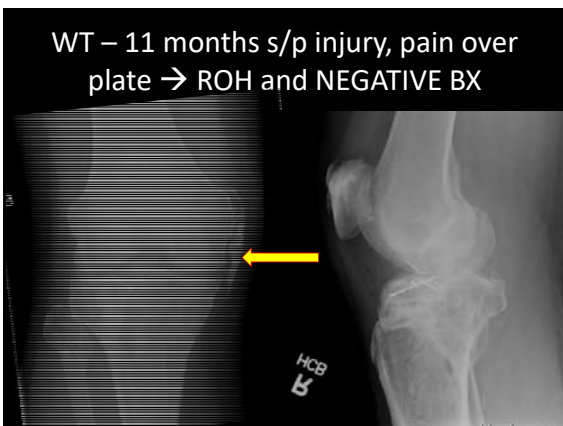

1. 1) High Probability
0%
2. 2) Low Probability
0%







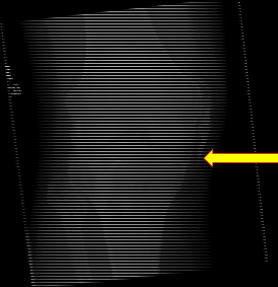


WT – No change in Xrays 6 more months non-op Tx, "Too much Pain", ROM 30-85

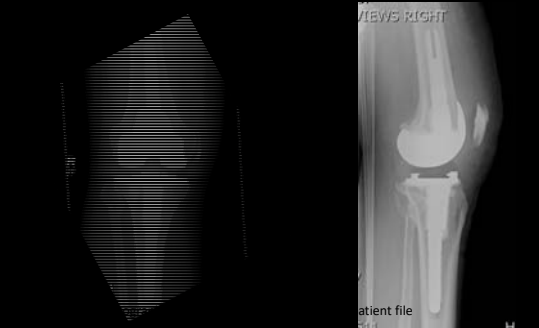
POLL OPEN

Next step?

1. -1) H.O. resection
0%
2. -2) TKR
0%
3. -3) TKR + H.O. resection
0%



WT – 1 yr s/p TKR: ROM 5-110, No pain



LT

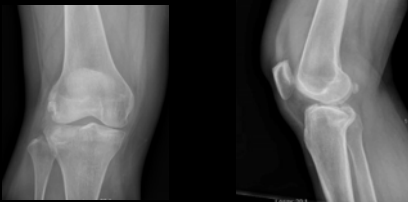
- 62 year old Healthy Female
- Fall down stairs, no prior knee pain



Next steps?

POLL OPEN

- 1) Non-op treatment with early ROM
0%
- 2) CT scan
100%
- 3) Straight to ORIF
0%



LT- Now What?

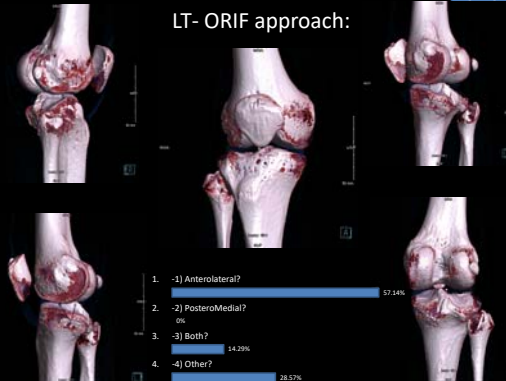
POLL OPEN



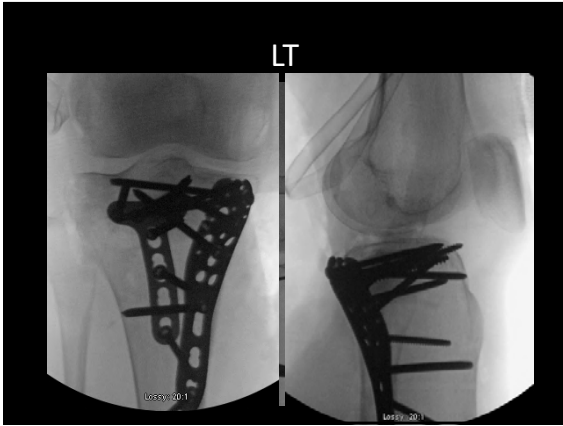
1. -1) Ex-Fix?
0%
2. -2) Straight to ORIF?
100%

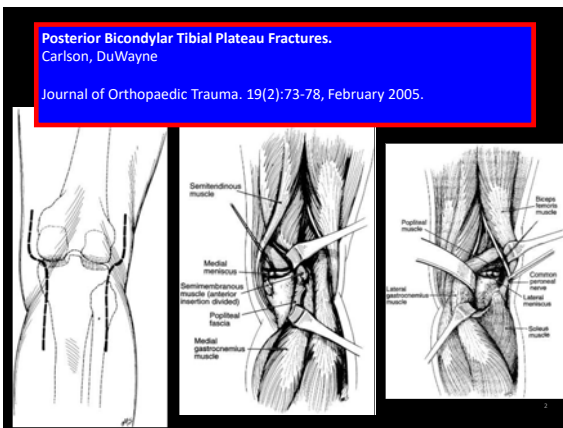
LT- ORIF approach:

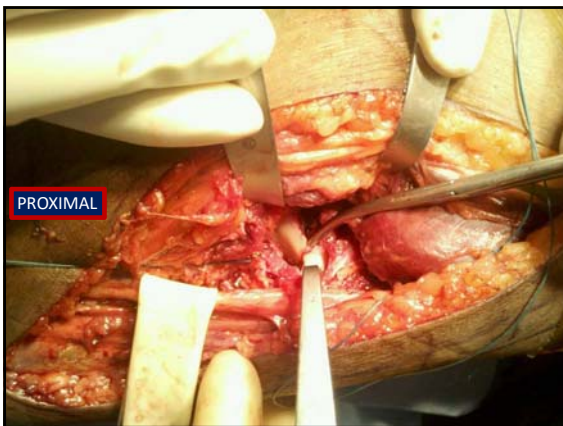
POLL OPEN

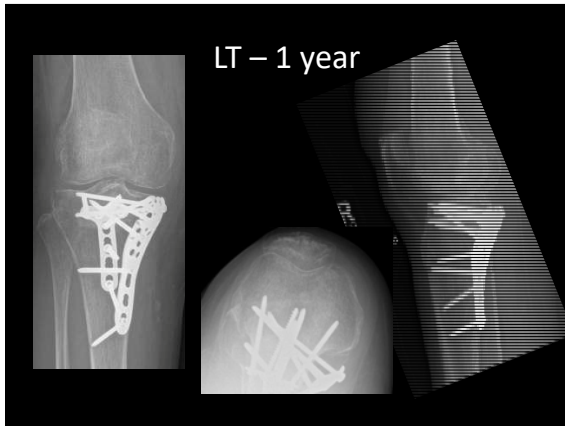


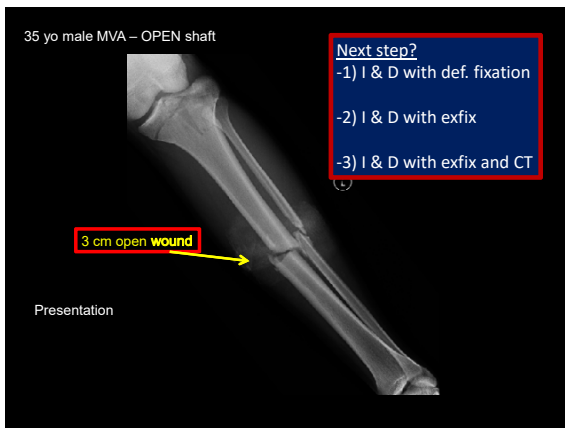
1. -1) Anterolateral?
57.14%
2. -2) PosteroMedial?
0%
3. -3) Both?
14.29%
4. -4) Other?
28.57%

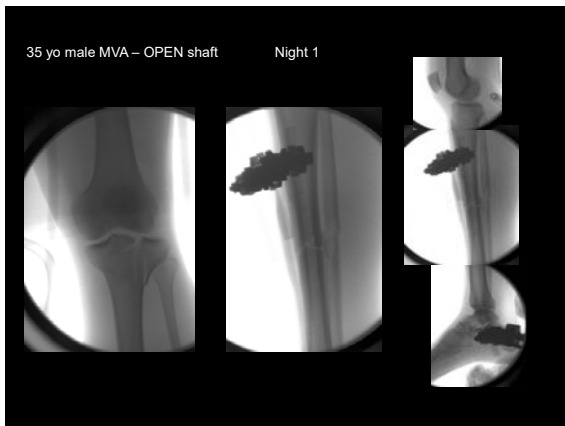


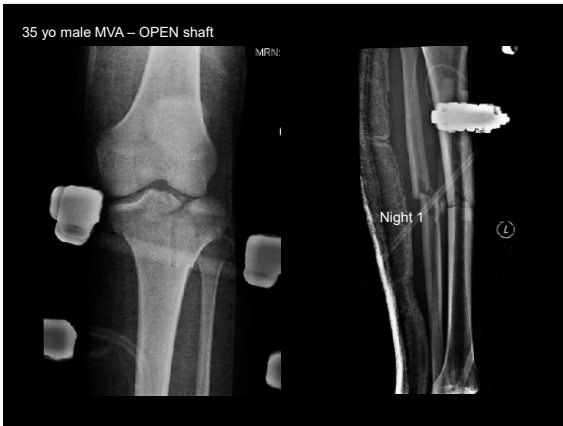

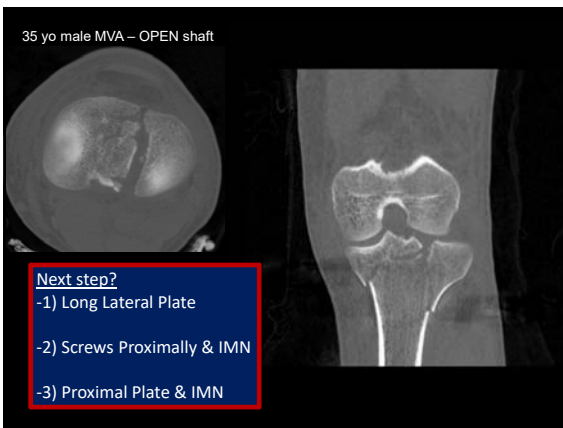


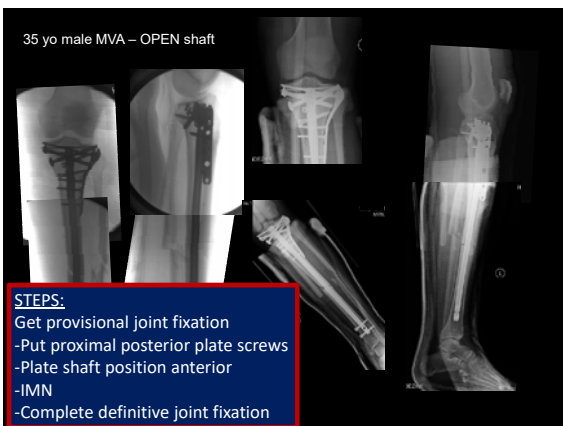








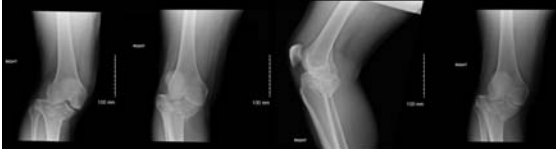




FQ

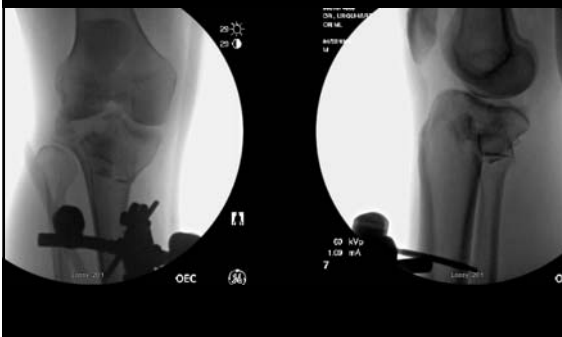- 46 yr M
- Fall 20 feet
- PMH: HTN
- PSH: appendectomy
- Allergies: NKDA
- Exam:
 - DP/PT +
 - SLIT
 - Swollen, painful knee
 - No reported hip or ankle pain
 - ABI 0.9

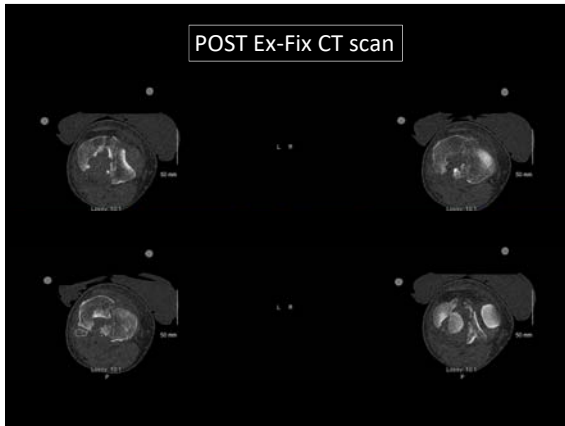
NIGHT 1

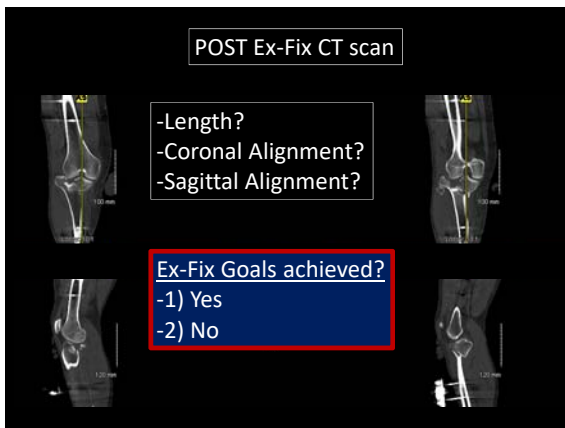


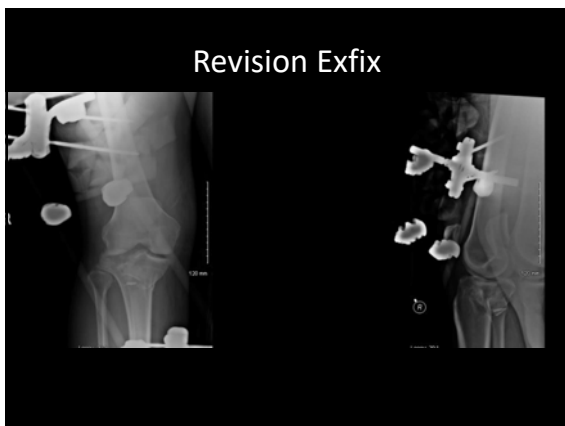Concerns:
-Compartment Syndrome
-Vascular Injury

Night 1



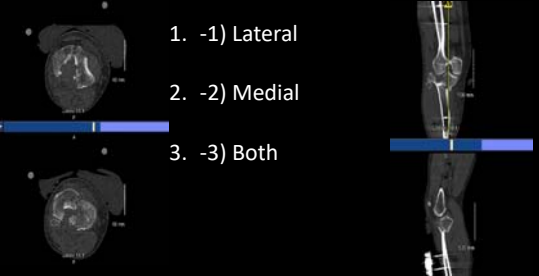






Remember CT scan? Definitive Fixation? POLL OPEN

1. -1) Lateral
2. -2) Medial
3. -3) Both



12 months – RTW full; ROM 0-120
Slight ttp at tip of plate



PR – June 30, 2007

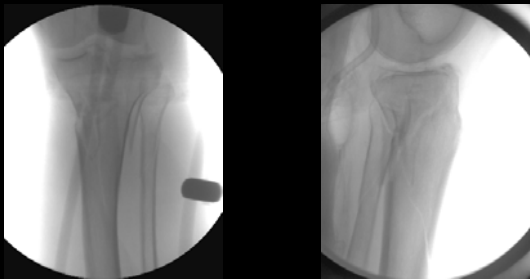


Radiographs from FAL personal unidentified patient file

PR – June 30, 2007

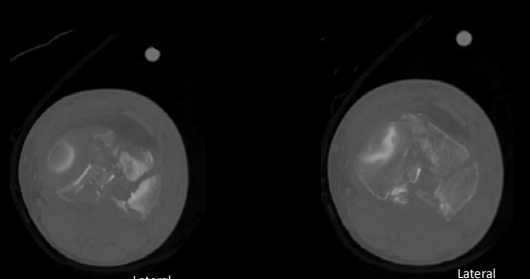
- 57 y.o. Motorcycle accident
- IDDM x 10 years
- 1ppd smoker
- Very swollen, no compartment syndrome

PR – July 1, 2007



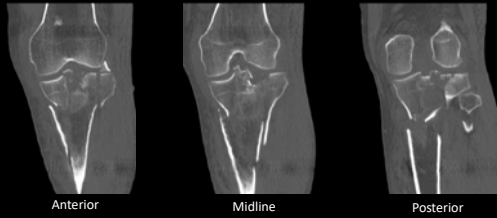Radiographs from FAL personal unidentified patient file

PR – July 1, 2007



Radiographs from FAL personal unidentified patient file

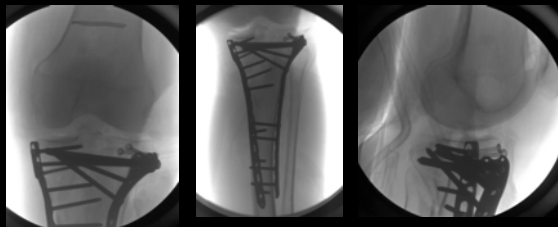
PR – July 1, 2007



Anterior Midline Posterior

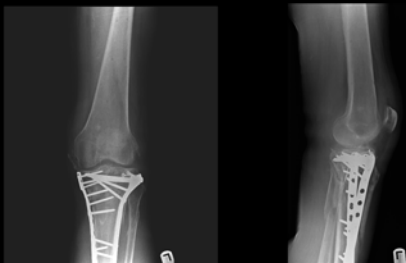Radiographs from FAL personal unidentified patient file

PR – July 24, 2007



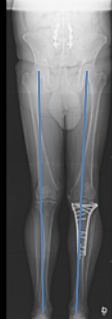
Radiographs from FAL personal unidentified patient file

PR – September 26, 2007



Radiographs from FAL personal unidentified patient file

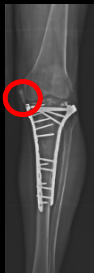PR – August 27, 2008



"More anatomic" on injured side

Radiographs from FAL personal unidentified patient file

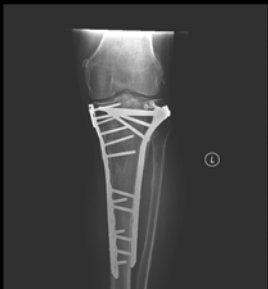PR – August 27, 2008



OUCH!!!

Radiographs from FAL personal unidentified patient file

PR – September 23, 2008

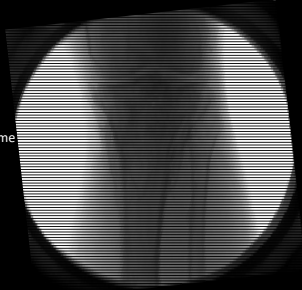


H.O. resection
Knee stable intra-op

Radiographs from FAL personal unidentified patient file

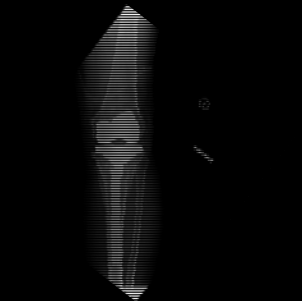
PR – March 15, 2010

- ROH: ? Painful
- Also Bx at that time
- Bx NEGATIVE



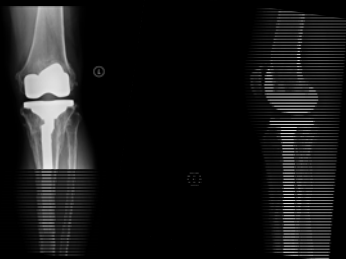Radiographs from FAL personal unidentified patient file

PR- June 15, 2010



Radiographs from FAL personal unidentified patient file

PR- July 2012



Radiographs from FAL personal unidentified patient file