

**Distal Radius Fracture  
Role for Percutaneous Fixation &  
Pearls for Plating**

**Current Solutions  
in  
Orthopedic Trauma**

Tampa 2017  
Jorge L. Orbay MD.



---

---

---

---

---

---

---

---

**Disclosure**

Skeletal Dynamics

---

---

---

---

---

---

---

---

- 21 y/o female college student
- Horse enthusiast
- Close injury, NVI, non-dominant



---

---

---

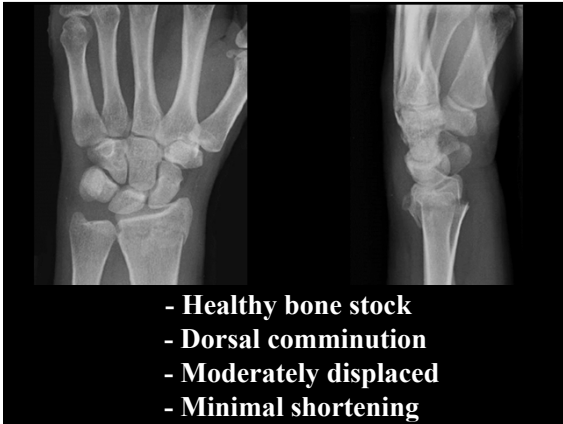---

---

---

---

---



---

---

---

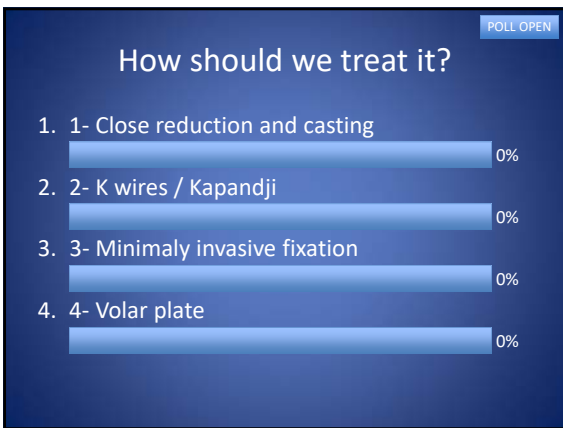
---

---

---

---

---



---

---

---

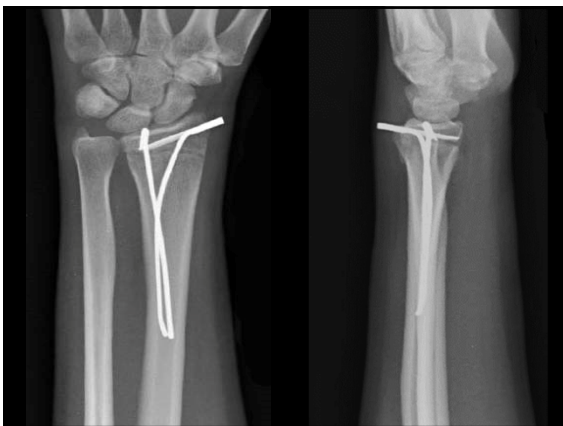
---

---

---

---

---



---

---

---

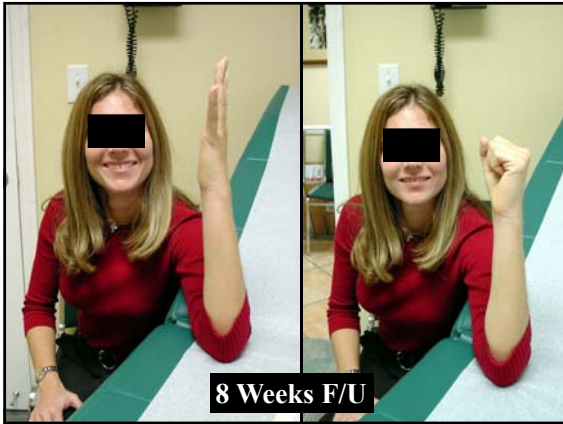---

---

---

---

---



---

---

---

---

---

---

---

---

- 81 y/o fell in bathtub
- Lives with daughter / independent
- Ambulates with walker
- COPD / O<sub>2</sub> dependent
- Close injury, NVI, non-dominant



---

---

---

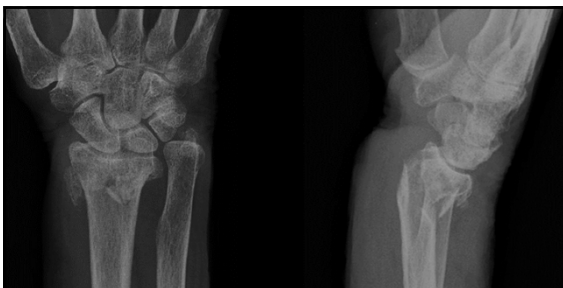---

---

---

---

---



- Fragility fracture
- Dorsal comminution
- Severe displacement
- Significant shortening

---

---

---

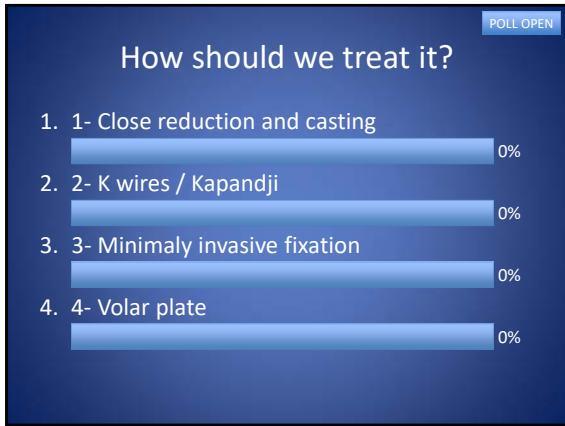
---

---

---

---

---



---

---

---

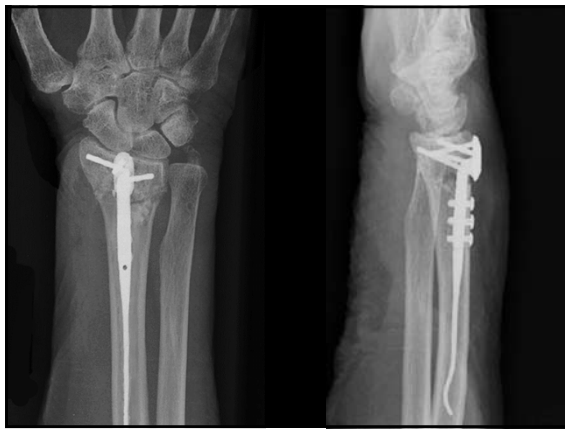---

---

---

---

---



---

---

---

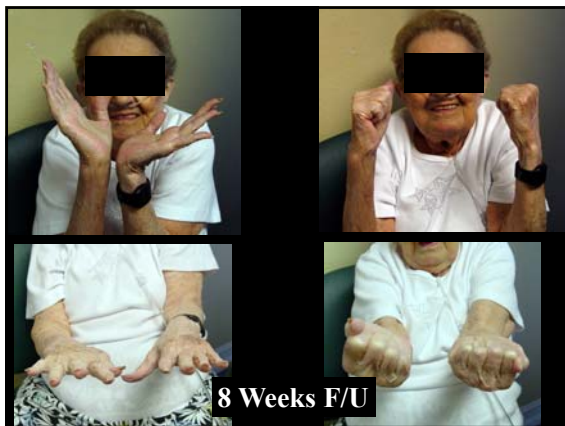---

---

---

---

---



---

---

---

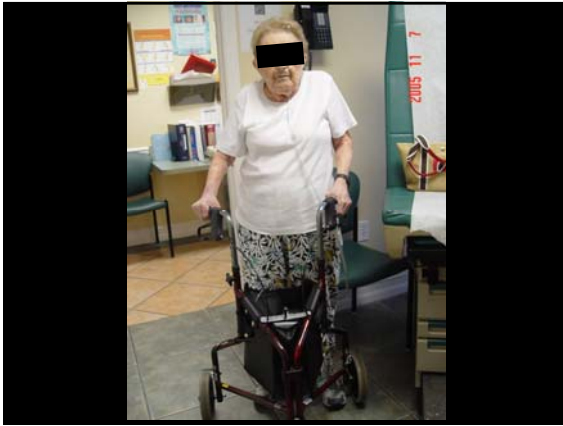---

---

---

---

---



---

---

---

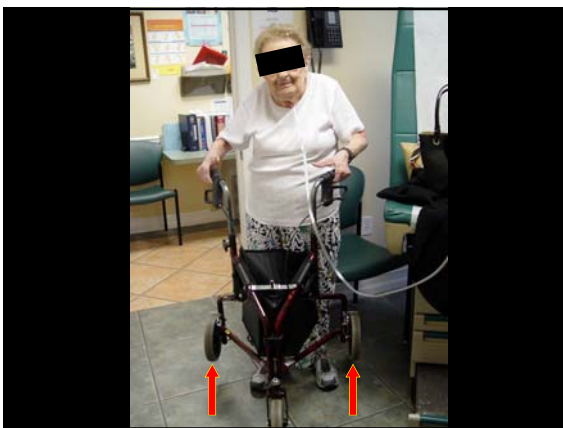
---

---

---

---

---



---

---

---

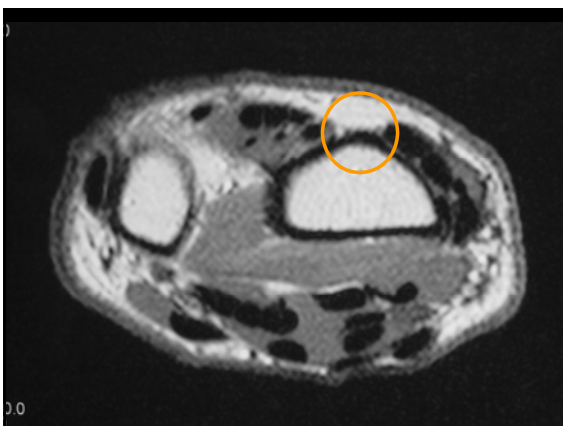
---

---

---

---

---



---

---

---

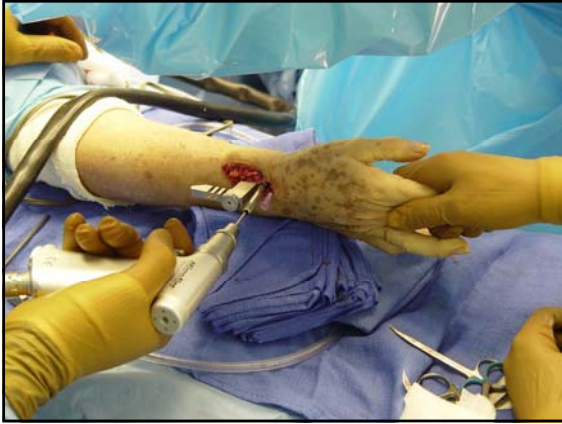---

---

---

---

---



---

---

---

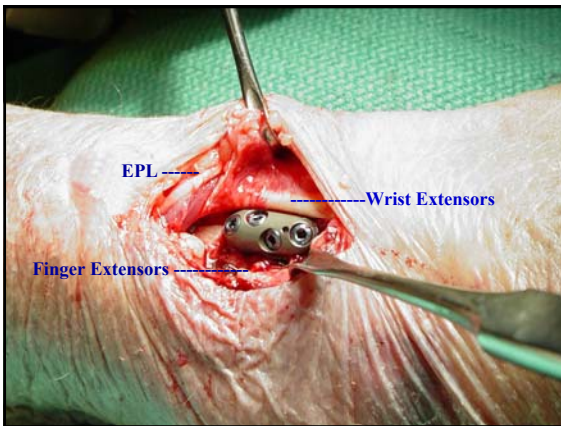
---

---

---

---

---



---

---

---

---

---

---

---

---

- 71 y/o practicing orthopedist, dominant hand, fell walking dog
- Ex-president of AAOS
- 4 wks post ORIF through 2 approaches and the use of multiple k-wires.

---

---

---

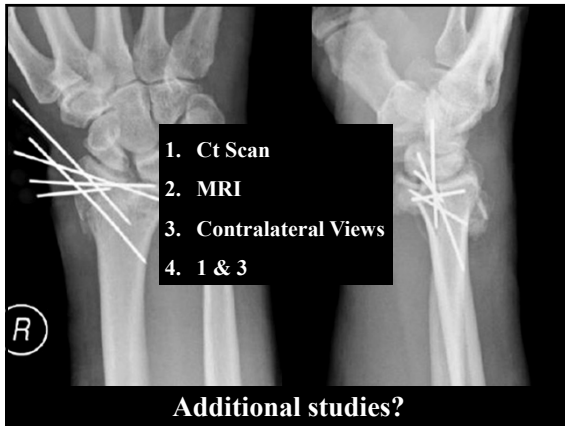---

---

---

---

---



---

---

---

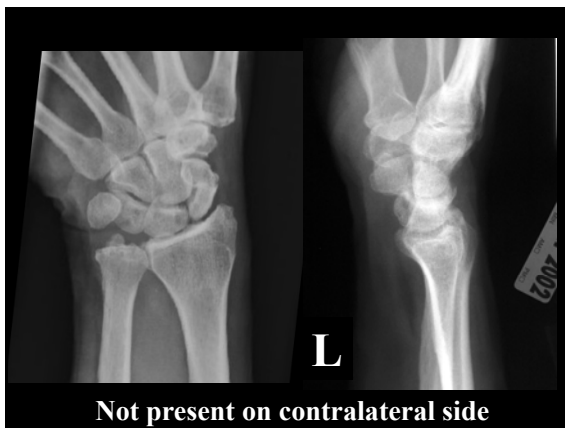---

---

---

---

---



---

---

---

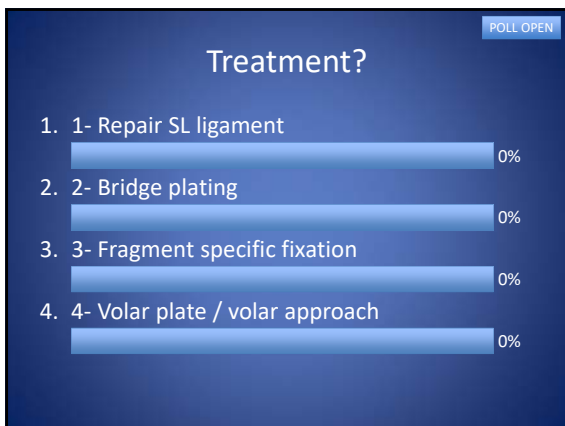
---

---

---

---

---



---

---

---

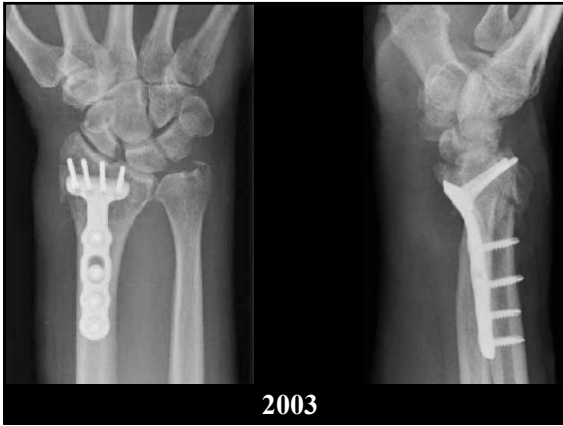
---

---

---

---

---



---

---

---

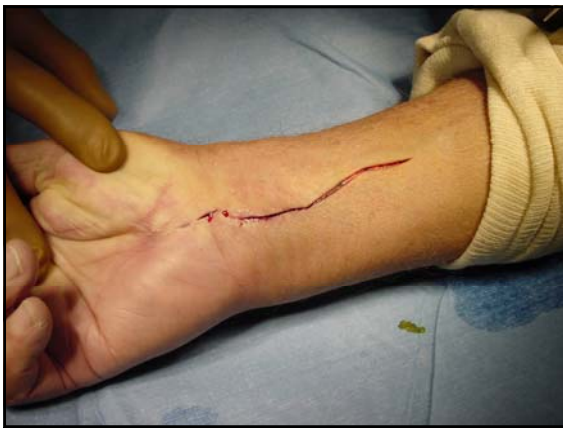---

---

---

---

---



---

---

---

---

---

---

---

---

**Extended FCR Approach**

- Distal exposure
- Soft tissue release

Two horizontal dashed lines are drawn across the photograph to indicate the extent of the soft tissue release.

---

---

---

---

---

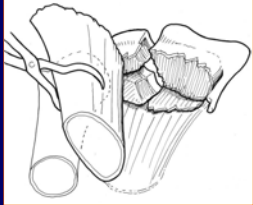
---

---

---

**Extended FCR Approach**

- Distal exposure
- Soft tissue release
- Pronate the proximal fragment



---

---

---

---

---


---

---

---

**Extended FCR Approach**

- Distal exposure
- Soft tissue release
- Pronate the proximal fragment
- Intrafocal Exposure



---

---

---


---

---

---

---

---



**The Dorsal Hematoma**

---

---

---

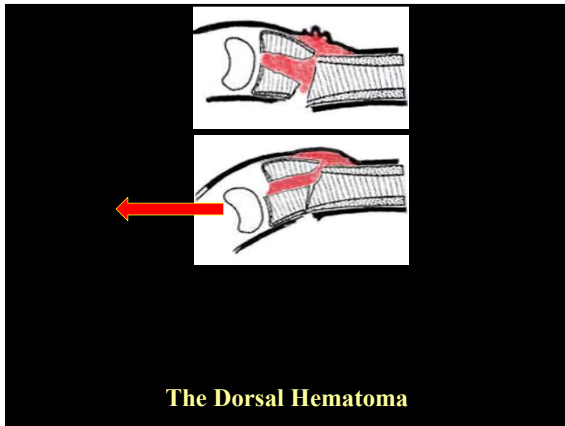
---

---

---

---

---



---

---

---

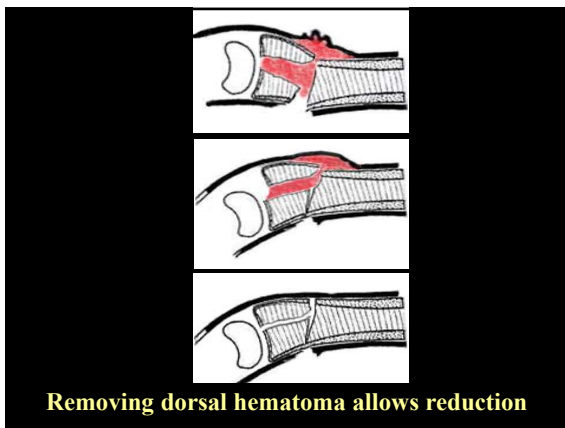
---

---

---

---

---



---

---

---

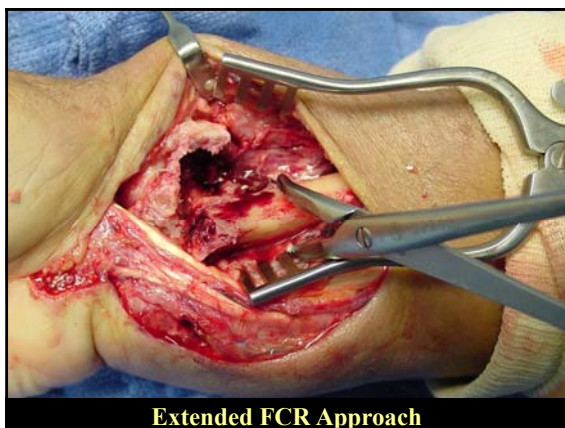---

---

---

---

---



---

---

---

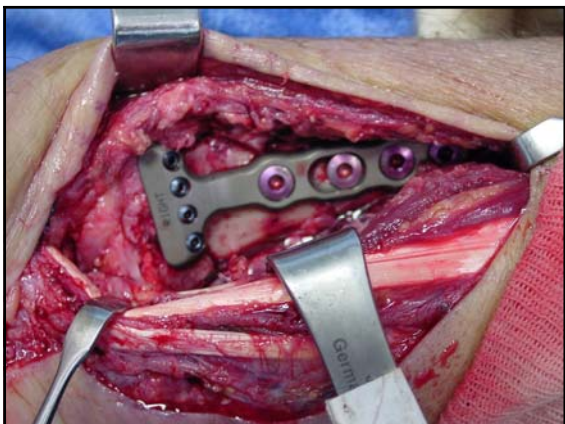
---

---

---

---

---



---

---

---

---

---

---

---

---

- Returned to reconstructive hip surgery 3 1/2 months after surgery.
- C/O mild ulnar side pain when using the slap-hammer.

---

---

---


---

---

---

---

---

- 20 y/o male, fell from 2<sup>nd</sup> story college balcony during failed Romeo-ing
- 
- A photograph showing a young man and woman in a romantic pose. The woman is leaning over the man, and they appear to be kissing or about to kiss. They are outdoors, possibly on a balcony or near a railing.

---

---

---

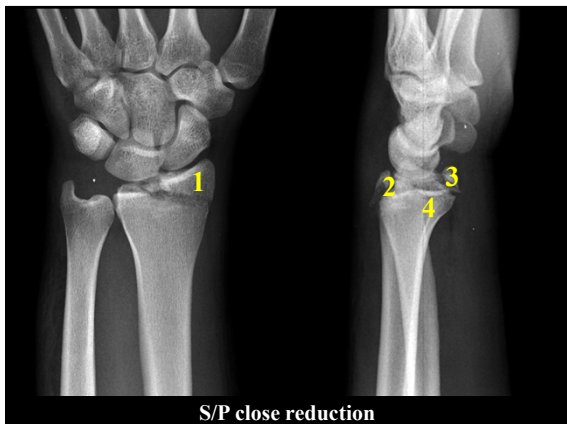---

---

---

---

---



---

---

---

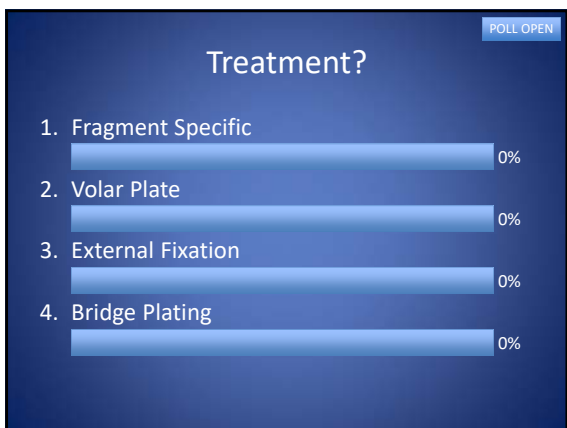
---

---

---

---

---



---

---

---

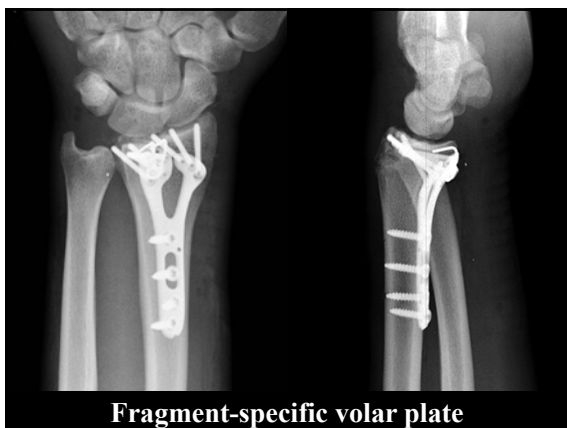
---

---

---

---

---



---

---

---

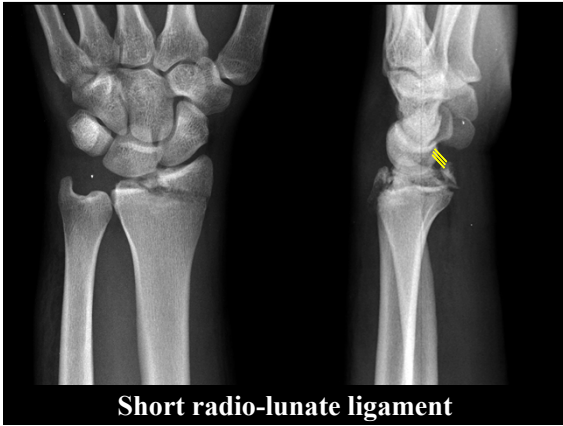---

---

---

---

---



---

---

---

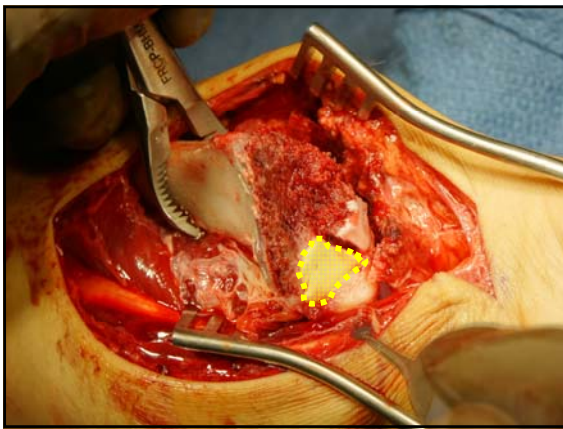
---

---

---

---

---



---

---

---

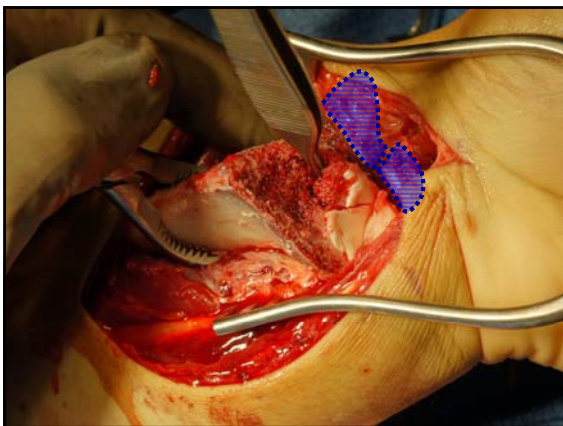
---

---

---

---

---



---

---

---

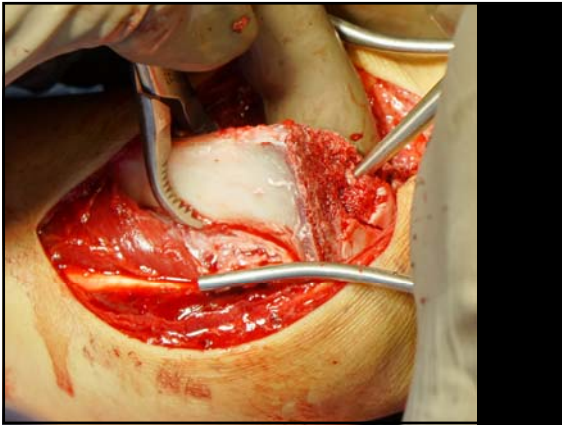
---

---

---

---

---



---

---

---

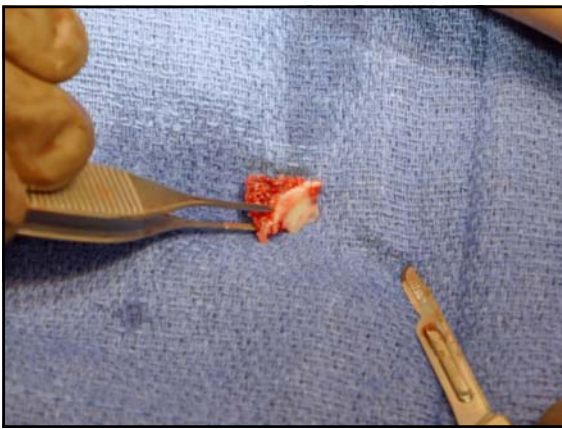
---

---

---

---

---



---

---

---

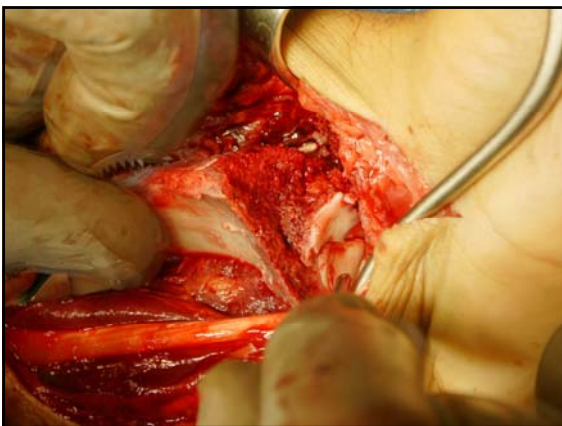---

---

---

---

---



---

---

---

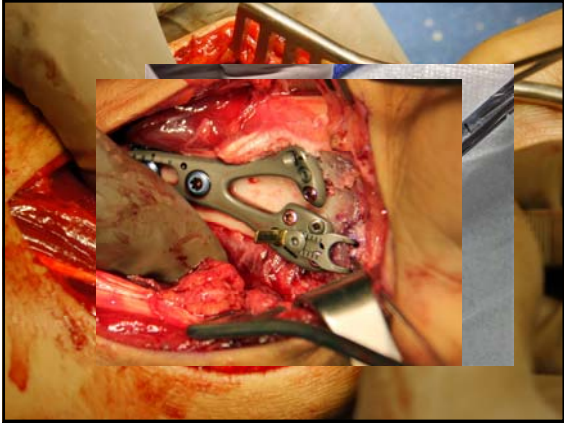
---

---

---

---

---



---

---

---

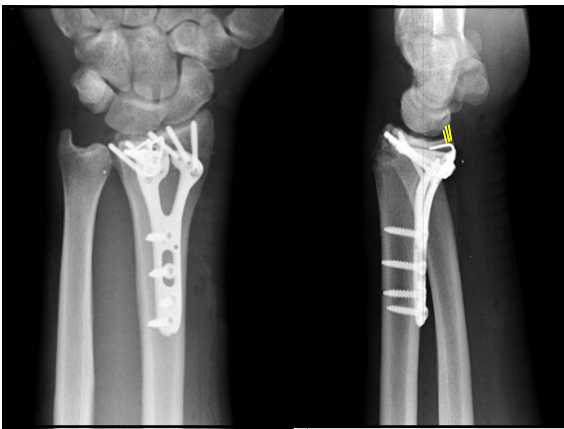
---

---

---

---

---



---

---

---

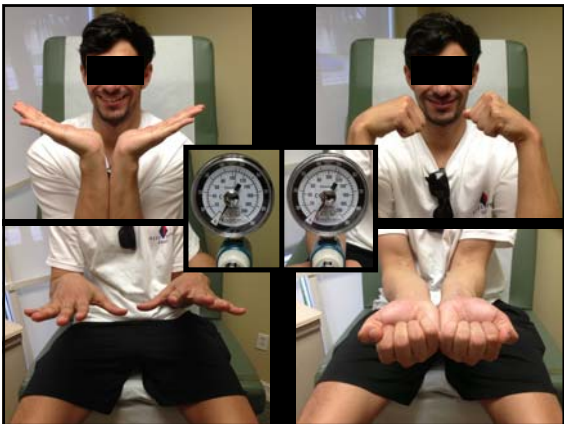
---

---

---

---

---



---

---

---

---

---

---

---

---

**29 year old  
Right hand dominant  
Avid Cyclist**



---

---

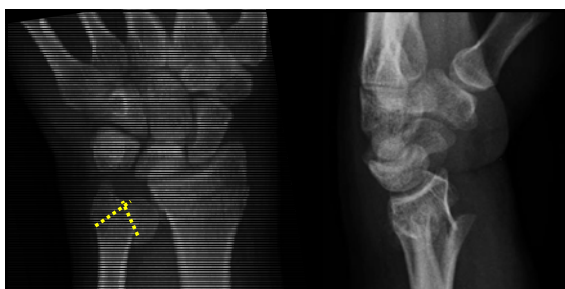---

---

---

---

---



**- Intraarticular distal ulna fracture  
- Severe radial displacement**

---

---

---

---

---

---

---

**How should we treat it?**

POLL OPEN

- 1- Reduce radius and ignore ulna 0%
- 2- Reduce radius and fix ulna 0%
- 3- Reduce radius and excise ulna 0%
- 4- Reduce radius and replace ulna 0%

---

---

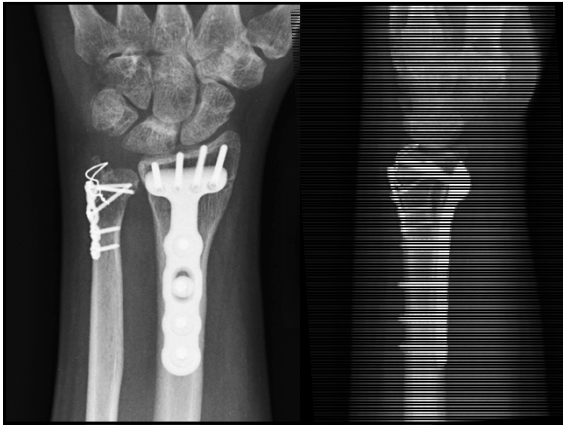
---

---

---

---

---



---

---

---


---

---

---

---

---



---

---

---

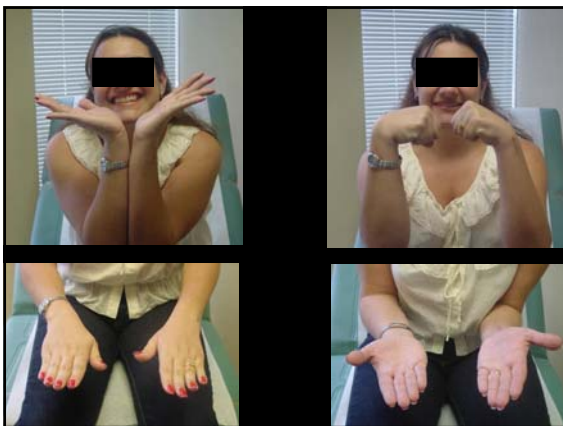---

---

---

---

---



---

---

---

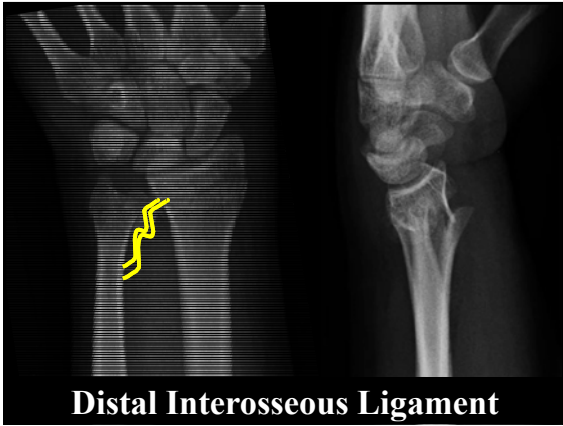
---

---

---

---

---



---

---

---

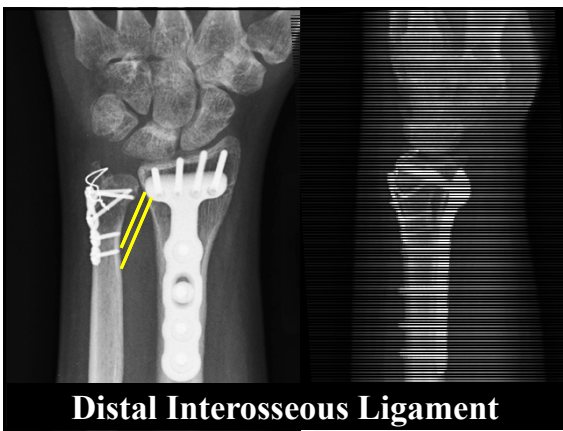
---

---

---

---

---



---

---

---

---

---

---

---

---

**Classification**

	<b>TFCC</b>	<b>DIOL</b>
<b>Type I</b>	+	+
<b>Type II</b>		
<b>Type III</b>		

---

---

---

---

---

---

---

---

**Classification**

	<b>TFCC</b>	<b>DIOL</b>
<b>Type I</b>	+	+
<b>Type II</b>	-	+
<b>Type III</b>		

---

---

---

---

---

---

---

---

**Classification**

	<b>TFCC</b>	<b>DIOL</b>
<b>Type I</b>	+	+
<b>Type II</b>	-	+
<b>Type III</b>	-	-

---

---

---

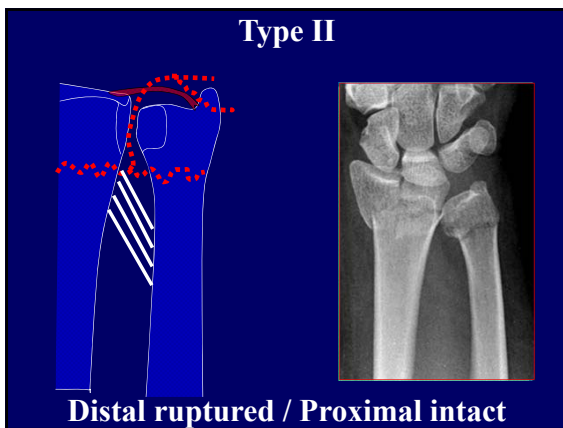
---

---

---

---

---




---

---

---

---

---

---

---

---

51 year old ♀  
Right hand dominant  
Fell down stairs



---

---

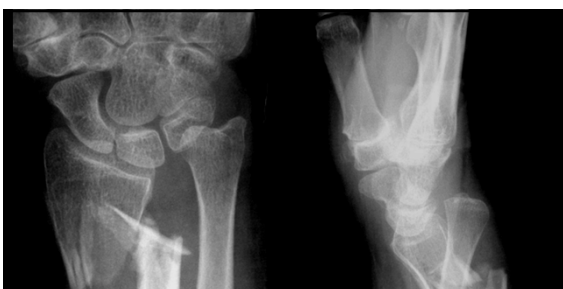---

---

---

---

---



- Displaced distal 1/3 radius fracture  
- DRUJ dislocation

---

---

---

---

---

---

---

How should we treat it?

POLL OPEN

- 1- Fix radius and ignore DRUJ 0%
- 2- Fix radius and repair TFCC 0%
- 3- Fix radius and pin DRUJ 0%
- 4- Fix radius and splint reduced 0%

---

---

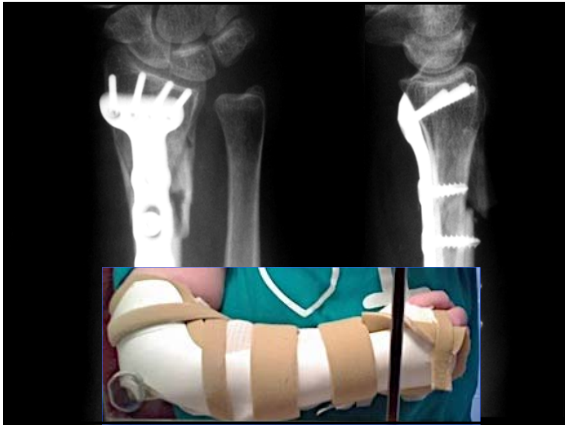---

---

---

---

---



---

---

---

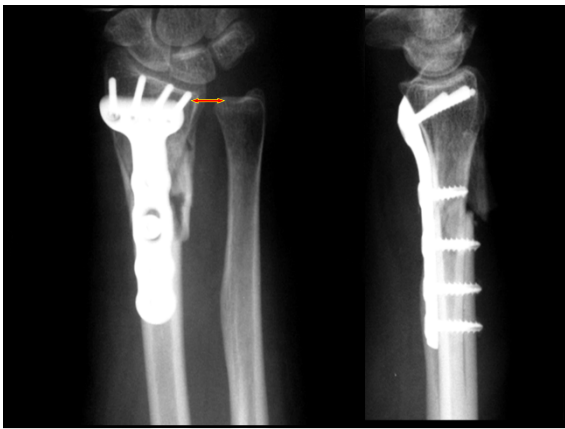
---

---

---

---

---



---

---

---

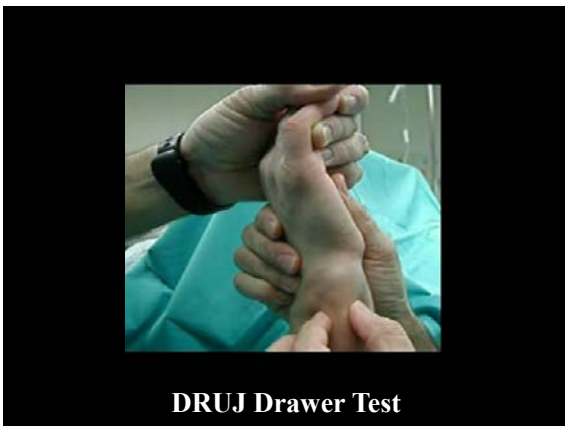---

---

---

---

---



**DRUJ Drawer Test**

---

---

---

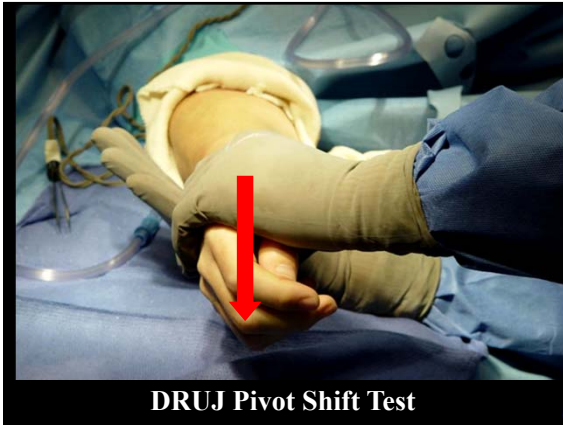---

---

---

---

---



---

---

---

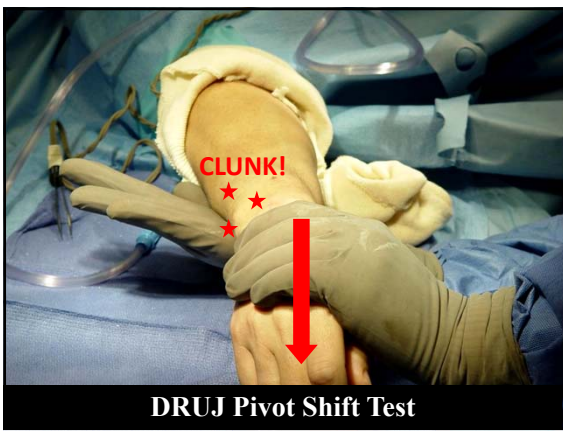
---

---

---

---

---



---

---

---

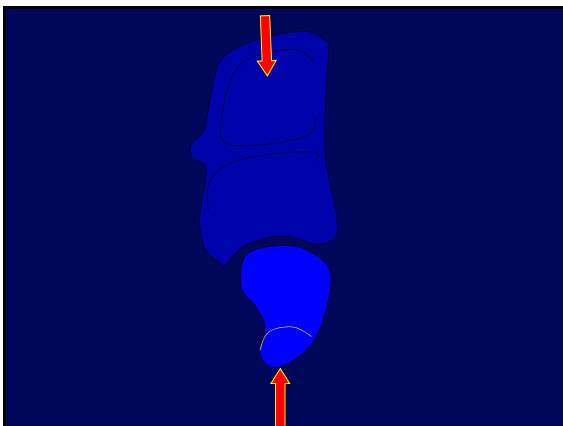
---

---

---

---

---



---

---

---

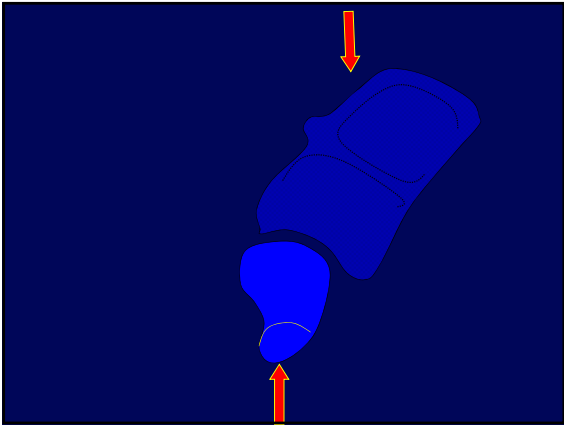
---

---

---

---

---



---

---

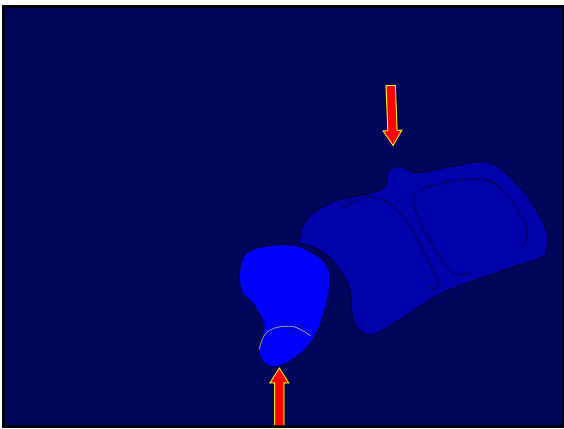
---

---

---

---

---



---

---

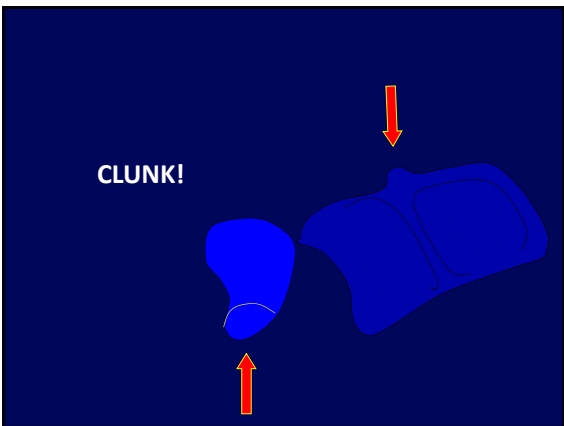
---

---

---

---

---



---

---

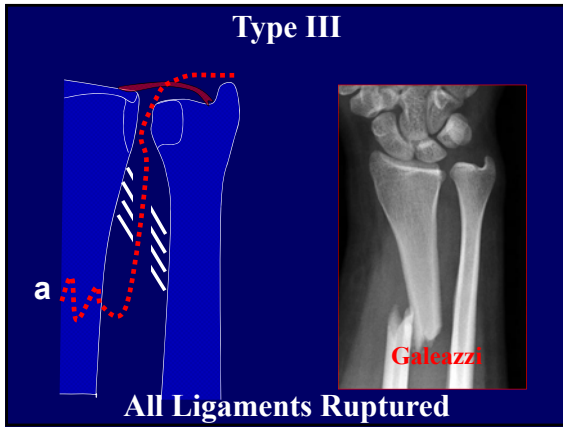
---

---

---

---

---



---

---

---

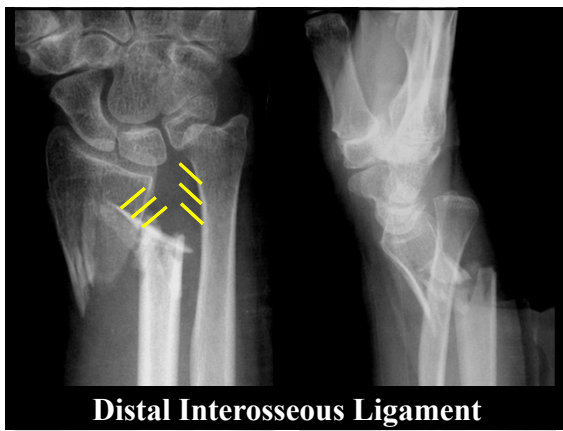
---

---

---

---

---



---

---

---

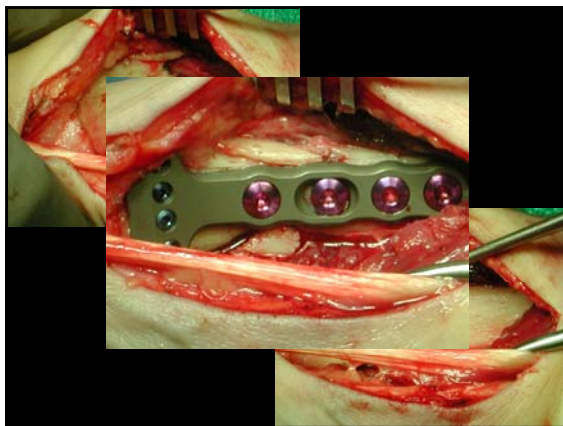
---

---

---

---

---



---

---

---

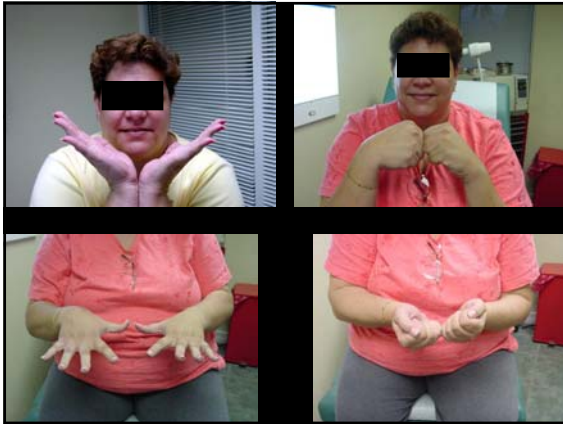---

---

---

---

---



---

---

---


---

---

---

---

---



---

---

---

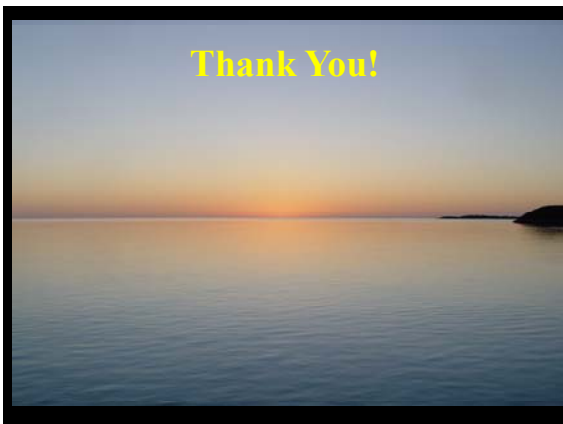
---

---

---

---

---



---

---

---

---

---

---

---

---