

Syndesmosis Case




28 Year Old Woman

- Motor vehicle accident
- Multiple fractures
- Closed ankle injury
- Weekend



ARS Question-Initial management?

POLL OPEN



1	Reduce, cast in ED	48.19%
2	Reduce, cast in the OR	3.7%
3	OR: external fixator	18.52%
4	Immediate ORIF	29.63%


ARS Question- Plan?

POLL OPEN

- 1 ORIF fibula and syndesmosis with screws
0%
- 2 ORIF fibula and syndesmosis with flexible fixation
0%
- 3 ORIF syndesmosis only
0%



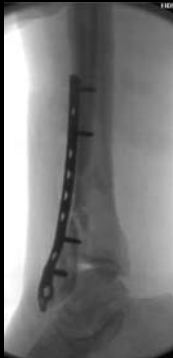OR



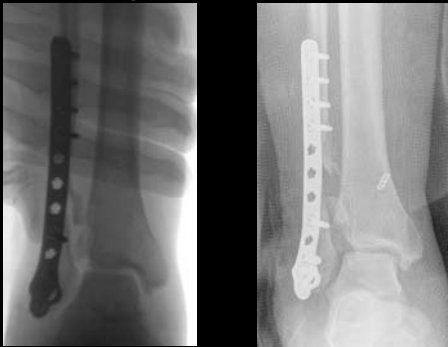
The Lateral... 2 Planes!




Meanwhile back in the OR...



Syndesmosis




That Pesky Other Plane



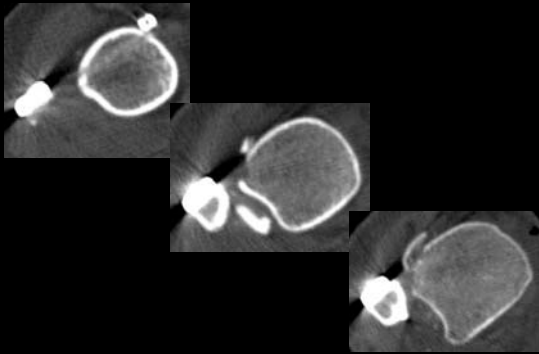
ARS Question-Now What?

POLL OPEN

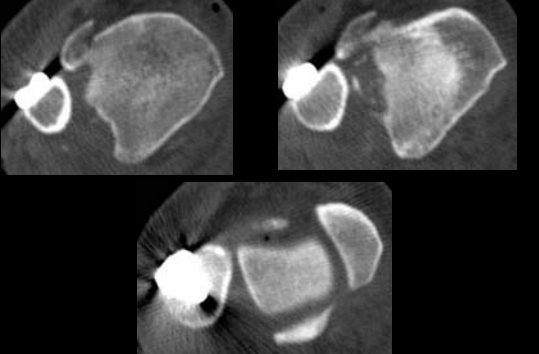


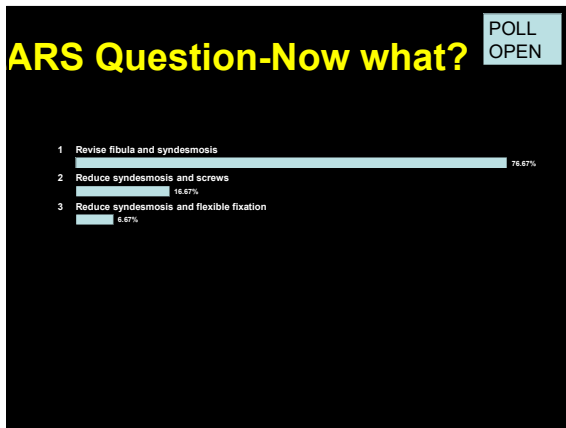
1	Cast x 6 weeks	2.7%
2	Cast x 12 weeks	0%
3	CT	74.67%
4	MRI	0%
5	Just revise	22.22%

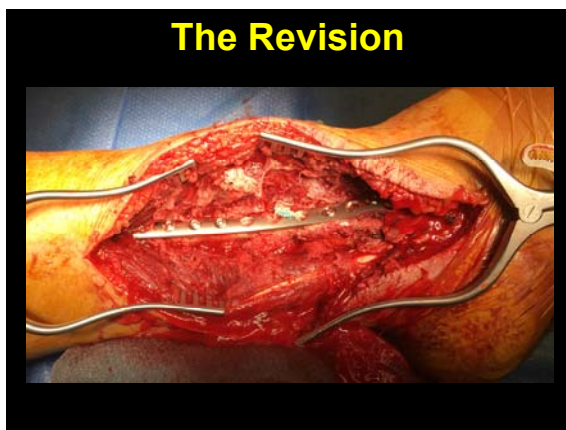CT

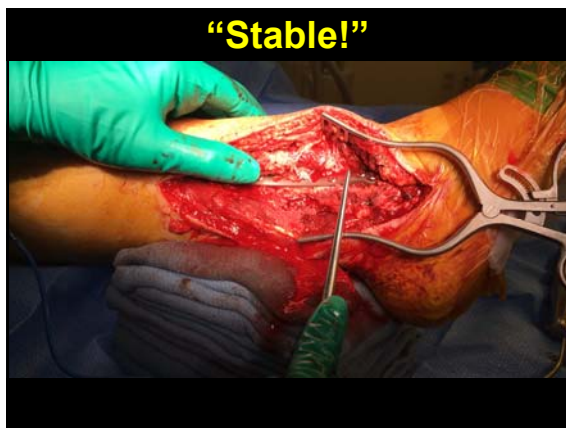

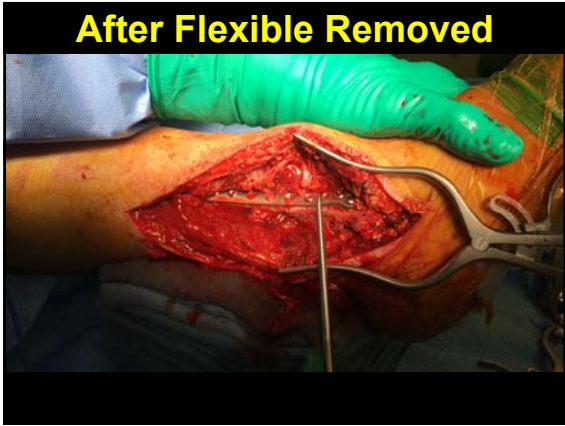CT

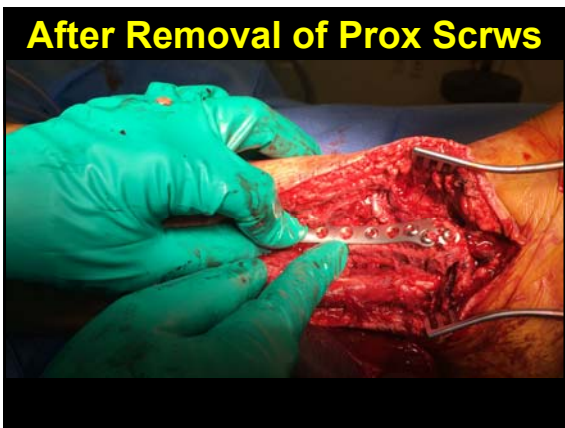

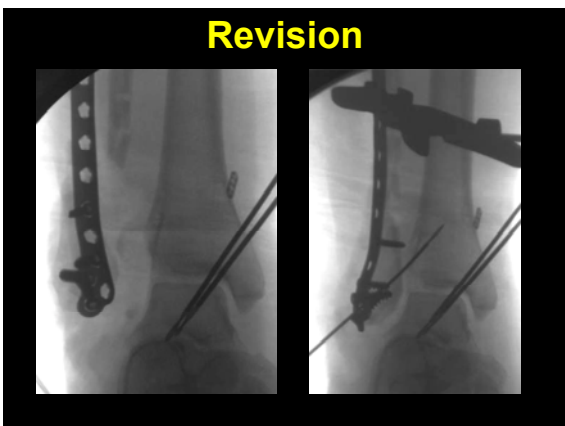


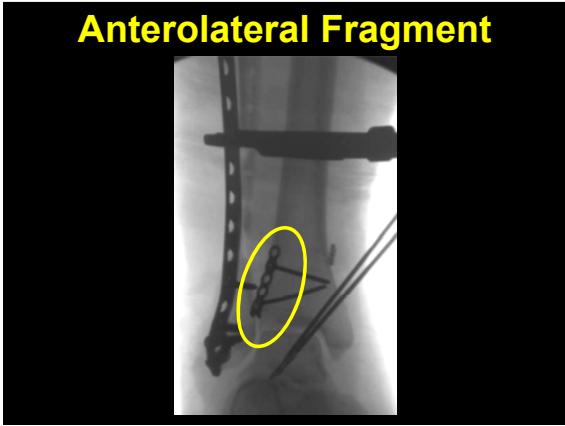


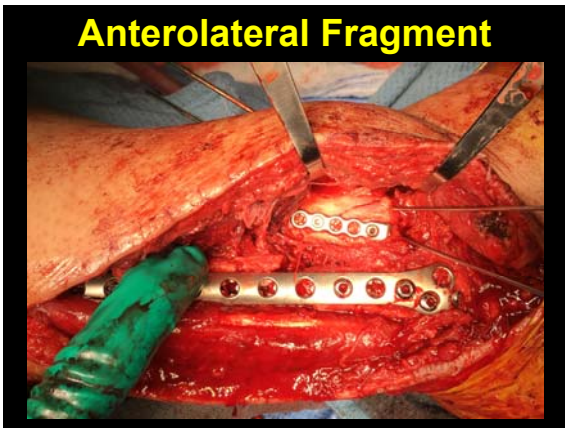



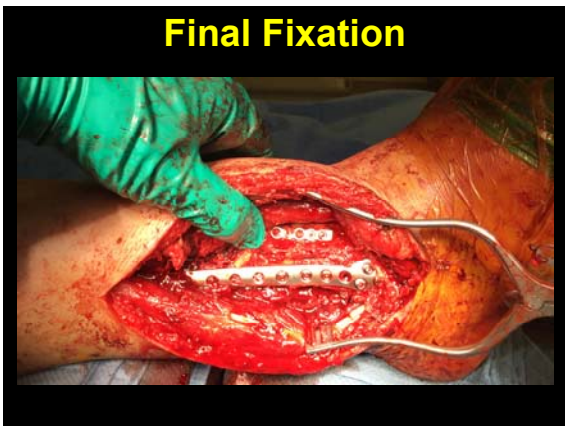


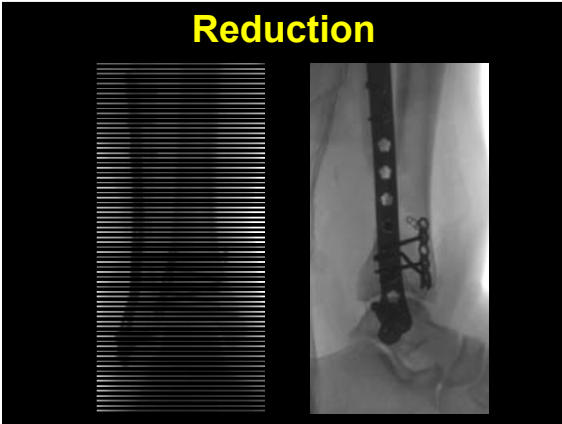








Reduction



CT

