

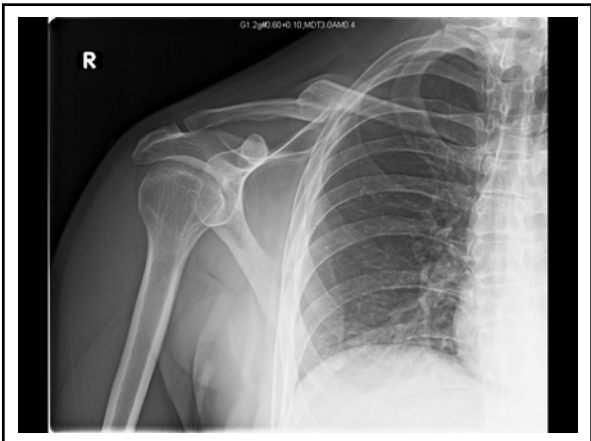
Disclosures

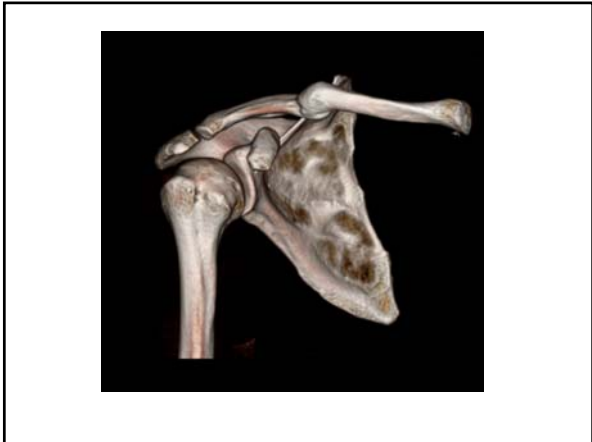- Globus
- ITS
- Smith and Nephew

Todd Neville

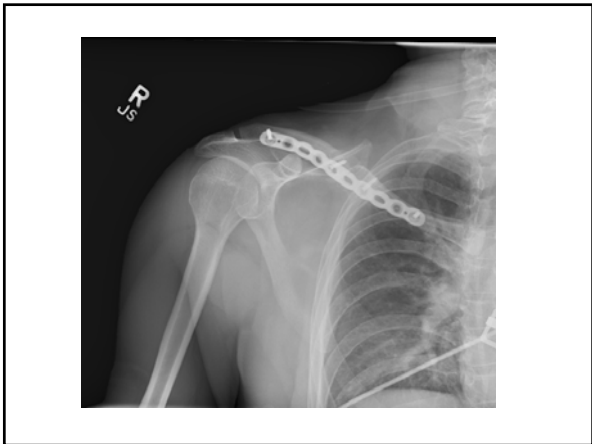
On July 7th 1997 Todd fell off his bike landing hard on his right shoulder. He suffered a mid shaft clavicle fracture. He presented to the ED and the decision was made to treat the fracture nonoperatively.

His fracture healed overlapped and shortened. The result was he developed chronic neck and shoulder pain. He also suffered from severe head aches.



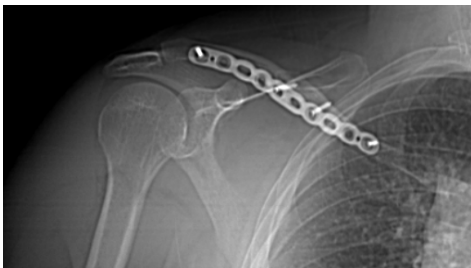

After years of physical therapy, shoulder injections, MRI and CT scans he sought operative intervention



Todd continued to make gains in strength and improvement in his shoulder pain after the surgery. He noted a more normal appearing shoulder.

A CT scan done in November 2013 confirmed healing of the osteotomy, and a more anatomic appearing clavicle. This restored the normal biomechanics of Todd's shoulder joint.



At his last office visit Todd was extremely pleased with the surgery. He was happy that after years of pain and disability due to his clavicle malunion he has finally found relief.
