

# OLIF REVISION CASES

Devin Datta, MD  
The BACK Center  
Melbourne Florida

---

---

---

---

---

---

---

---

- ▶ Nonunion
- ▶ Sagittal plane deformity
- ▶ Coronal plane deformity
- ▶ Safer direct anterior release
- ▶ Corpectomy
- ▶ Removal of interbody device
- ▶ Transitional/variable anatomy

# OLIF FLEXIBILITY

---

---

---

---

---

---

---

---

- ▶ Minimal invasive retroperitoneal approach
- ▶ Ante psoas
- ▶ Avoids previous midline scar
- ▶ Easy access to L4-S1
- ▶ Safe for transitional anatomy

# OLIF TECHNIQUE

---

---

---

---

---

---

---

---

- ▶ 68 y/o obese male
- ▶ Back greater than leg pain
- ▶ Previous L4-S1 fusion
- ▶ Failed injections and therapy
- ▶ Discogram concordant L1-4
- ▶ SI joint injection no improvement

## CASE LN

---

---

---

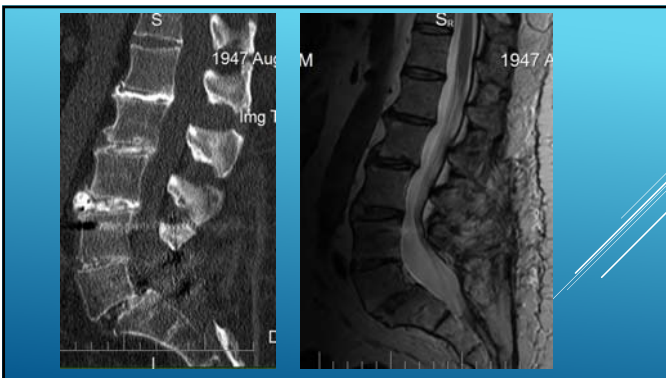---

---

---

---

---



---

---

---

---

---

---

---

---

- ▶ Do nothing he's old and fat
- ▶ Pain pump or SCS trial
- ▶ Posterior add on fusion
- ▶ OLIF and PSIF
- ▶ Interspinous process device

## WHAT ARE OUR OPTIONS?

---

---

---

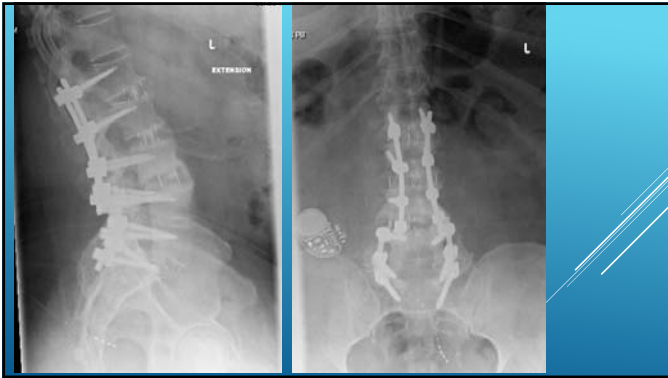
---

---

---

---

---



---

---

---

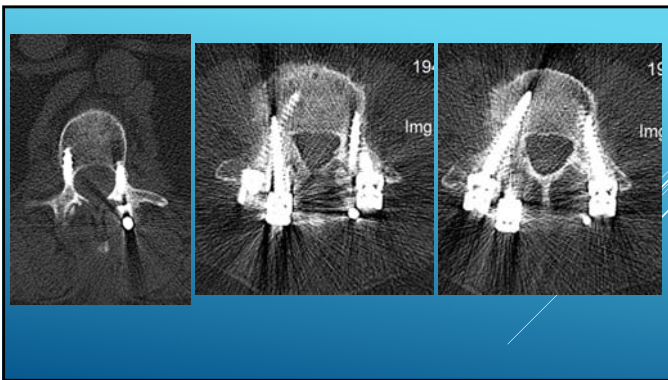
---

---

---

---

---



---

---

---

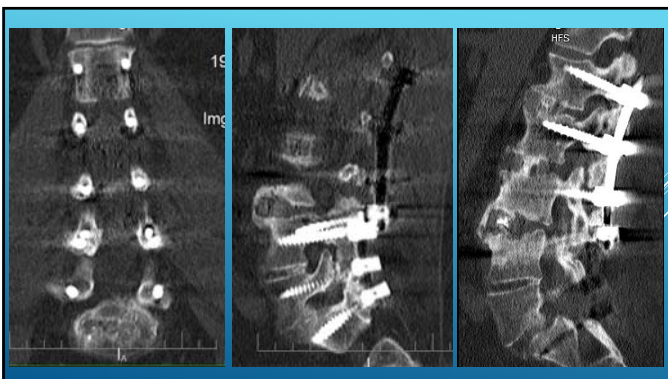
---

---

---

---

---



---

---

---

---

---

---

---

---

- ▶ 63 y/o lady with osteoporosis
- ▶ Fall and L2 fx treated with kyphoplasty
- ▶ Transferred in for severe back and leg pain post op
- ▶ Question of infectious process- labs mildly elevated
- ▶ Cant get out of bed due to intractable pain
- ▶ "You've got to do something"

**CASE DP**

---

---

---

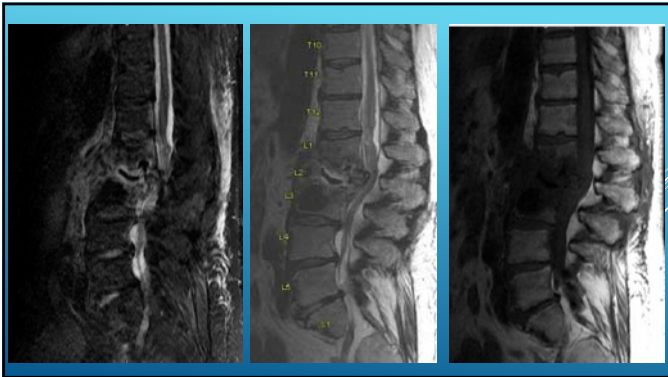
---

---

---

---

---



---

---

---

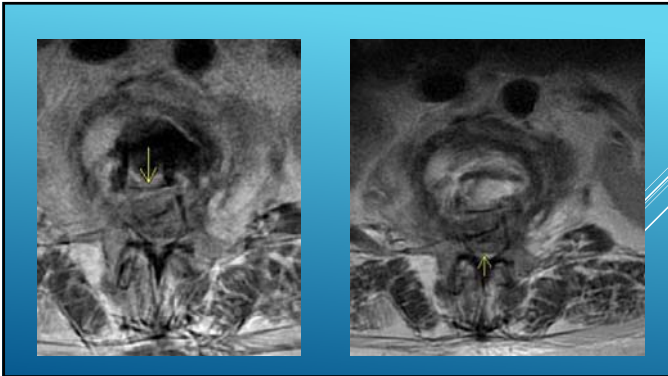
---

---

---

---

---



---

---

---

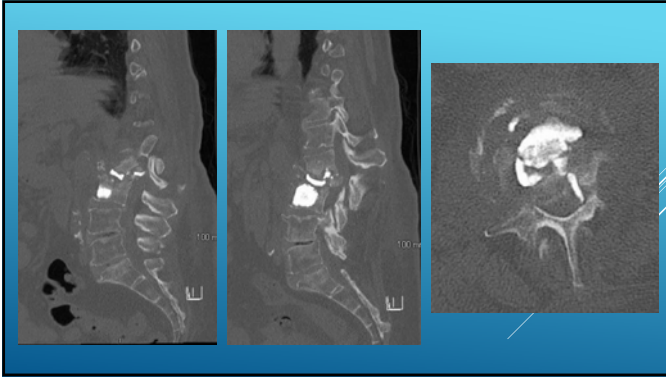
---

---

---

---

---



---

---

---

---

---

---

---

---

- ▶ We are doomed to fail- hospice
- ▶ Call the Obamacare hotline
- ▶ TLSO brace
- ▶ Posterior fusion and osteotomy
- ▶ Anterior corpectomy and posterior fusion
- ▶ T10 to pelvis
- ▶ Other

**WHAT ARE OUR OPTIONS?**

---

---

---

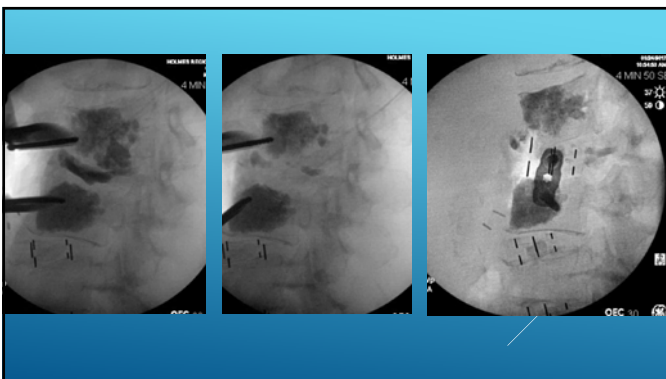
---

---

---

---

---



---

---

---

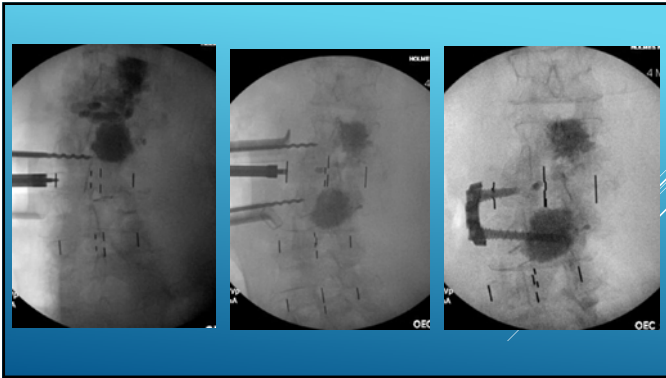
---

---

---

---

---



---

---

---

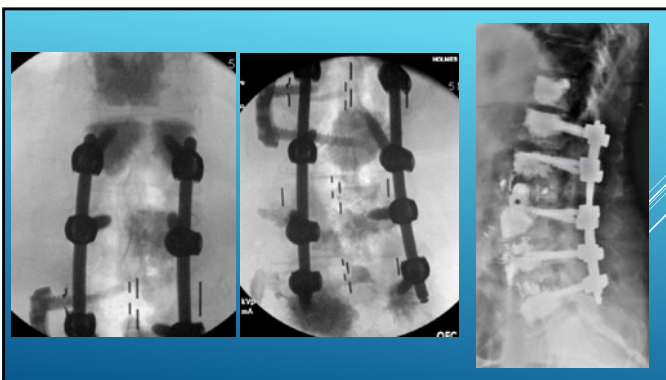
---

---

---

---

---



---

---

---

---

---

---

---

---

- ▶ 81 y/o healthy lady
- ▶ Back pain with LE pain
- ▶ History of multilevel laminectomy
- ▶ Failed all conservative treatment
- ▶ "Do something, I'm not going to live this way"
- ▶ Failed SCS

**CASE MS**

---

---

---

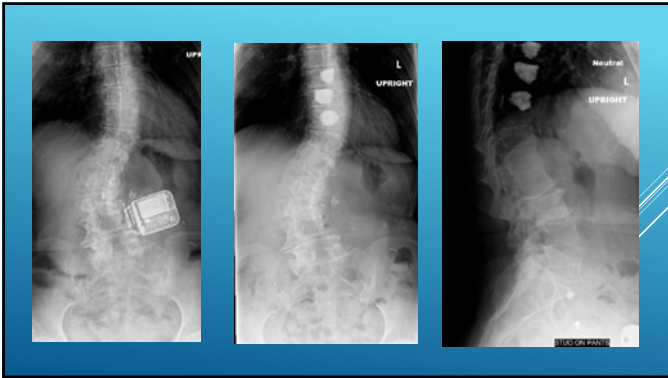
---

---

---

---

---



---

---

---

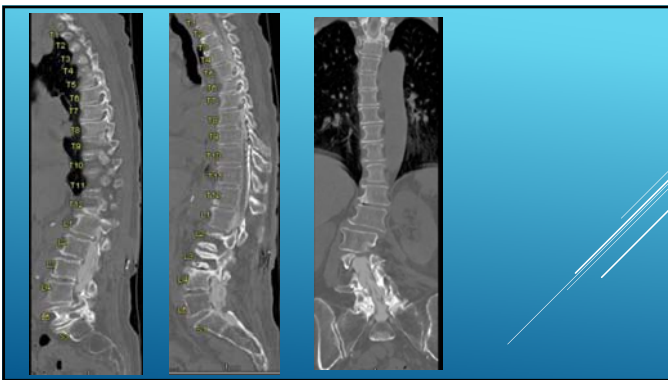
---

---

---

---

---



---

---

---

---

---

---

---

---

- ▶ She 80- give her more pain meds till she dies it will save money for medicare
- ▶ Intrathecal pain pump
- ▶ Limited or multilevel posterior reconstruction
- ▶ OLIF plus posterior percutaneous fixation
- ▶ OLIF plus posterior medialized pedicle screws

**WHAT ARE OUR OPTIONS?**

---

---

---

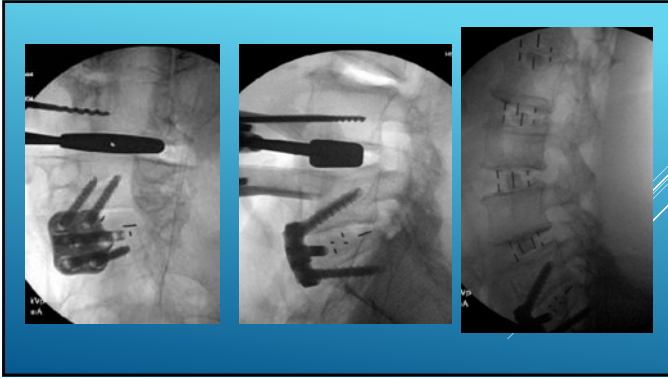
---

---

---

---

---



---

---

---

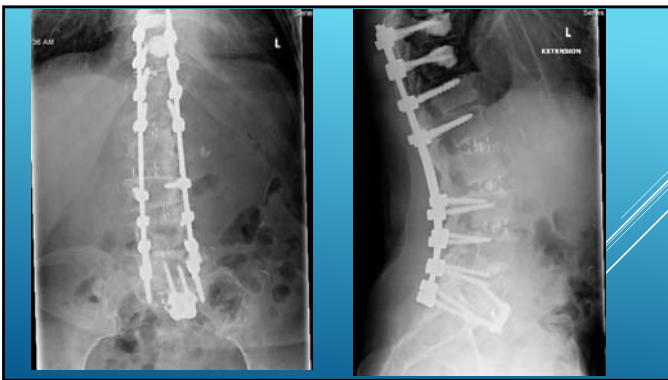---

---

---

---

---



---

---

---

---

---

---

---

---



---

---

---

---

---

---

---

---