

**fore**

## New Stuff: Soft Tissue Injuries

Atlanta Trauma Symposium  
April 20<sup>th</sup> – 22<sup>nd</sup> 2017

William M. Reisman, M.D.  
Chief of Orthopaedics  
Grady Memorial Hospital



---

---

---

---

---


---

---

---

## Acute Wound Dressing

- Negative Pressure Wound Therapy
- Antibiotic Bead Pouch



---

---

---

---

---

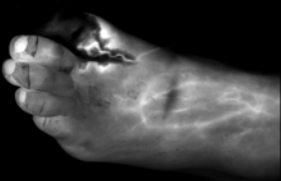

---

---

---

## Tissue Evaluation

- SPY Intraoperative Perfusion Assessment System



---

---

---

---

---

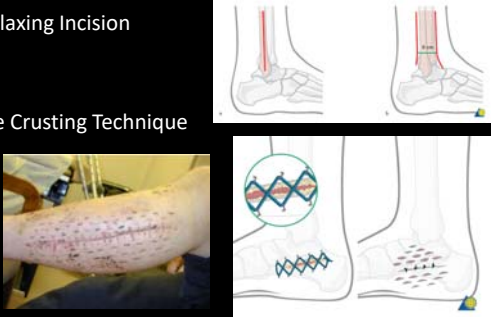
---

---

---

### Wound Closure Techniques

- Relaxing Incision
- Pie Crusting Technique



The image contains two diagrams and one photograph. The top diagram shows a relaxing incision on a heel, with a vertical incision and a Z-plasty to reduce tension. The bottom diagram shows a pie crusting technique, where the wound edges are folded back like pie crust to close the wound. The photograph shows a patient's leg with a long, healed surgical scar.

---

---

---

---

---

---

---

---

### Delayed Wound Closure Methods

- Split Thickness Skin Graft
- Allograft Dermis
- Amnionic Membrane



The image contains three photographs. The first shows a split thickness skin graft on a patient's arm. The second shows a hand with a white, mesh-like allograft dermis covering a wound. The third shows a hand with a translucent amnionic membrane covering a wound.

---

---

---

---

---


---

---

---

### Flap Coverage

- Local Flaps



Peroneal artery perforator propeller flap

*Courtesy of Ray Pensy, MD*

---

---

---

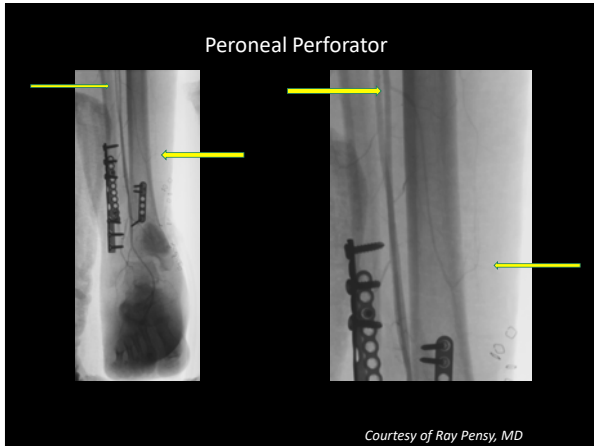
---

---

---

---

---



---

---

---

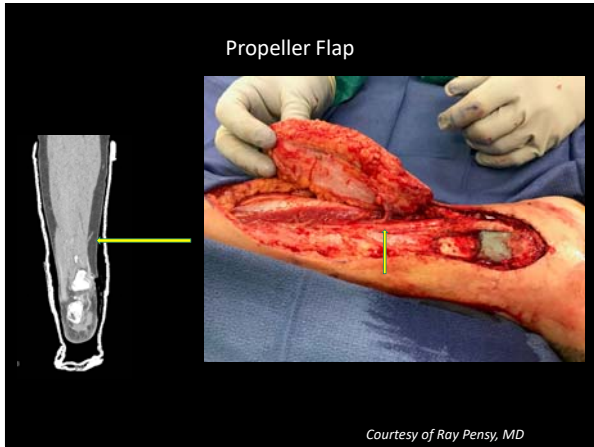
---

---

---

---

---



---

---

---

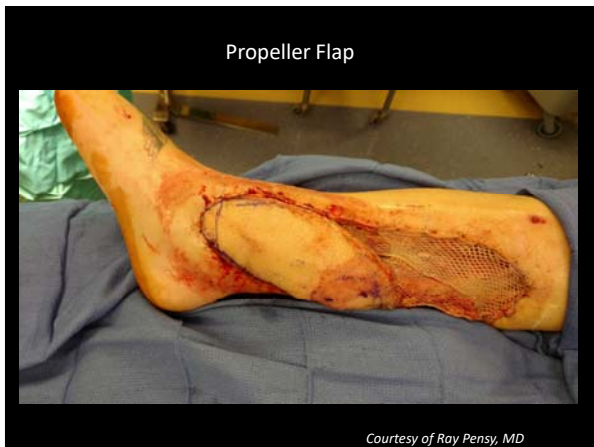
---

---

---

---

---



---

---

---

---

---

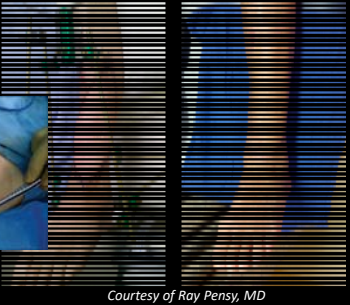

---

---

---

## Flap Coverage

- Free Flaps
  - Anterior Lateral Thigh Flap
  - Fasciocutaneous



*Courtesy of Roy Pensy, MD*

---

---

---

---

---

---

---

---

## Review

- Negative Pressure Wound Therapy
- Antibiotic Bead Pouch
  
- Allograft Dermis
- Embryonic Membrane
  
- Relaxing Incision
- Pie Crusting
  
- SPY
  
- Local Flaps
- Free Flaps

---

---

---

---

---

---

---

---