

### L4-5 Nonisthmic Spondylolisthesis

- 68 yo female worsening symptoms past 5 years
- CC- low back that radiates into buttock area with prolonged standing and walking relieved by sitting
- Rx- Physical Therapy , medication, and epidural steroid injection
- PE- LE. Motor 5/5, sens. Intact, DTRs 2, pedal pulses 2+

FLORIDA ORTHOPAEDIC INSTITUTE  
Castellvi Spine 2016  
fore

---

---

---

---

---

---

---

---

### Case L4-5

FLORIDA ORTHOPAEDIC INSTITUTE  
Castellvi Spine 2016  
fore

---

---

---

---

---

---

---

---

### Case L4-5

FLORIDA ORTHOPAEDIC INSTITUTE  
Castellvi Spine 2016  
fore

---

---

---

---

---

---

---

---



---

---

---

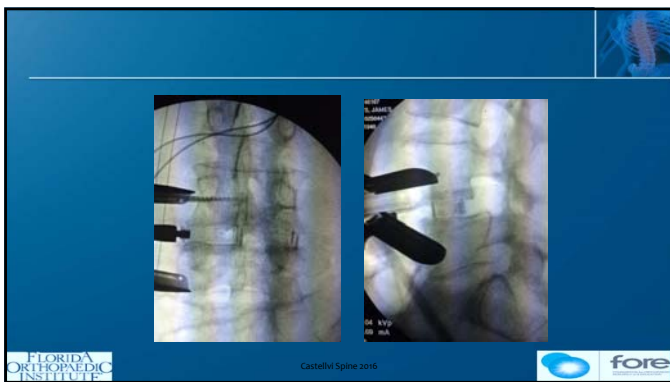---

---

---

---

---



---

---

---


---

---

---

---

---



---

---

---

---

---

---

---

---