

## Five Tips in Fasciotomies

R. Bruce Simpson MD FACS  
Hughston Trauma at Ft Walton Beach

---

---

---

---

---

---

---

---

## Objectives

- Review five select tips for safe/successful management of compartment syndromes
  - Length of incision: how long is long enough?
  - Partial closure: Not the same as incomplete release
  - Early decisions mean more sleep
  - NPД (negative pressure dressings) are your friends
  - Plan for the future: shift incisions to accommodate future surgeries

---

---

---

---

---

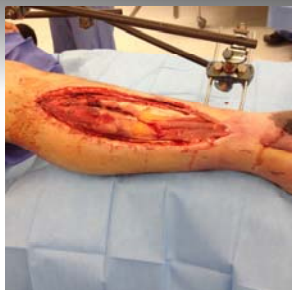---

---

---

## Compartment Syndrome

- Definition
- Etiology
- Natural History
- Treatment:
  - RAPID reduction in oncotic pressure
  - Fasciotomies:
    - Extensile skin and fascial incisions
    - Immediate reduction in tissue oncotic pressures



---

---

---

---

---

---

---

---

### Tissue Oncotic Pressure

- Perfusion pressure exceeded
- Increasing tissue hypoxia
- Tissue and cell necrosis
- Rhabdomyolysis +/- ATN
- Loss of function

---

---

---

---

---

---

---

---

### Tip 1: Nice, Long Incisions

- Incision length:
- Brumback 1989
  - Open fx did not prevent compartment syndrome
- Cohen et al 1992
  - Skin incision should be no less than 16 cm
  - Smaller dermatomy failed to reduce pressure

One parafibular incision vs 2 (medial/lateral)

---

---

---

---

---

---

---

---

### Tip 2: Partial Closures

- Mattress sutures
- 1 inch residual opening
- Simultaneous closure
- Minimizes differential gapping
- Minimizes need for subsequent skin grafting

---

---

---

---

---


---

---

---

**Tip 3:**  
**Early Decisions Mean More Sleep**

- Compartment syndrome is an evolving process
- Deferring a decision:
  - Late-night decision making
  - Late night operating
  - Partially ischemic tissue
  - Difficulty in subsequent closures



---

---

---

---

---


---

---

---

**Tip 4:**  
**Negative Pressure Dressings are Your Friends**

- Assist in resolution of tissue edema
  - Diminish time to closure?
  - Reduce need for Skin Grafting?
- Promote tissue decontamination
- Nice, tidy dressings



---

---

---

---

---


---

---

---

**Tip 5:**  
**Plan for the Future:**  
**Adjust Skin Incision Location**

- Need for access in definitive surgery
- Move incisions:
  - Distally
  - Posteriorly
  - Incorporate traumatic lacerations
- Think ultimate surgery and coverage



---

---

---

---

---

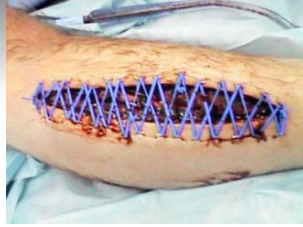---

---

---

### Summary

- Operate early
- Nice long incisions
- Partially close wounds
  - Simultaneous, if possible
- Negative pressure dressings
  - Preop request
- Adjust location to suit definitive fix/coverage



---

---

---

---

---

---

---

---

### Thank You

---

---

---

---

---

---

---

---