

### Case JB

- 66 y/o male 74" 235 lbs
- Retired police officer
- C/O low back pain, bilateral leg pain with weakness, numbness and tingling.
- S/P fusion L2-S1 in 2004
  - History of smoking 3 ppd (stopped 10 years ago)

FLORIDA ORTHOPAEDIC INSTITUTE  
Castellvi Spine 2016  
fore

---

---

---

---

---

---

---

---

### Pre-op JB

FLORIDA ORTHOPAEDIC INSTITUTE  
Castellvi Spine 2016  
fore

---

---

---

---

---

---

---

---

### Case JB

FLORIDA ORTHOPAEDIC INSTITUTE  
Castellvi Spine 2016  
fore

---

---

---

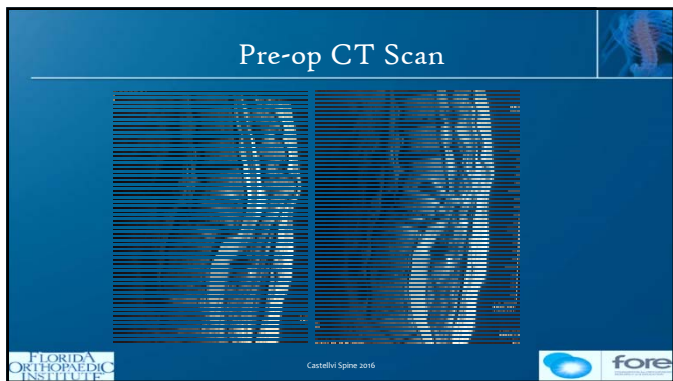
---

---

---

---

---



---

---

---


---

---

---

---

---



---

---

---


---

---

---

---

---



---

---

---


---

---

---

---

---



---

---

---


---

---

---

---

---



---

---

---


---

---

---

---

---



---

---

---

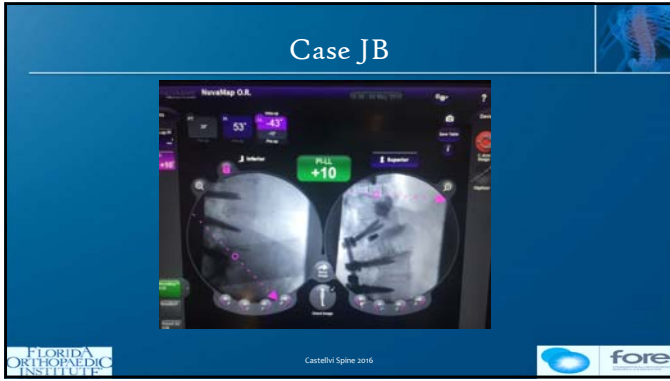---

---

---

---

---



---

---

---

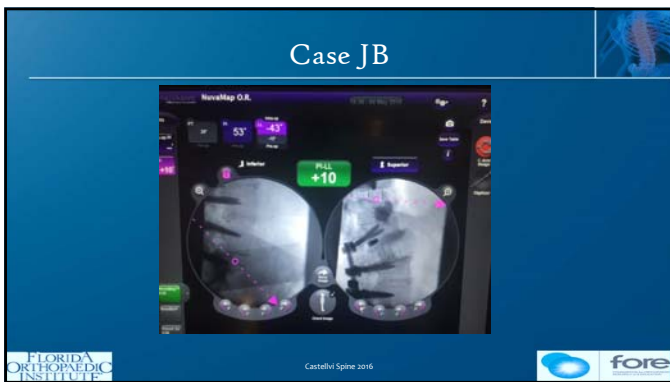
---

---

---

---

---



---

---

---


---

---

---

---

---



---

---

---


---

---

---

---

---



---

---

---

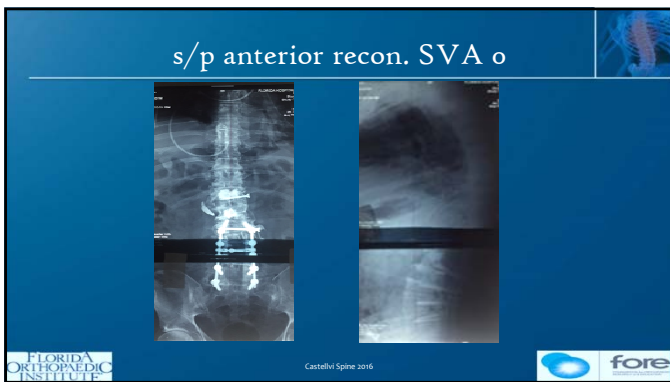
---

---

---

---

---



---

---

---

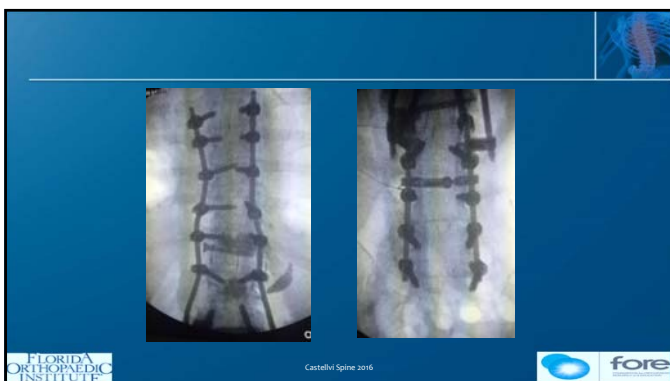---

---

---

---

---



---

---

---


---

---

---

---

---



---

---

---

---

---

---

---

---