

fore **ORIF** 

Proximal Humerus Fractures

Atlanta Trauma Symposium
April 20th – 22nd 2017

William M. Reisman, M.D.
Chief of Orthopaedics
Grady Memorial Hospital



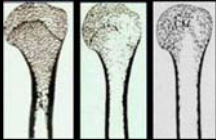
Take Home Points

- Bone quality primary factor in treatment decisions
- Understand and counteract deforming forces
- Step by step approach to exposure, reduction and fixation

Two Types of Fractures

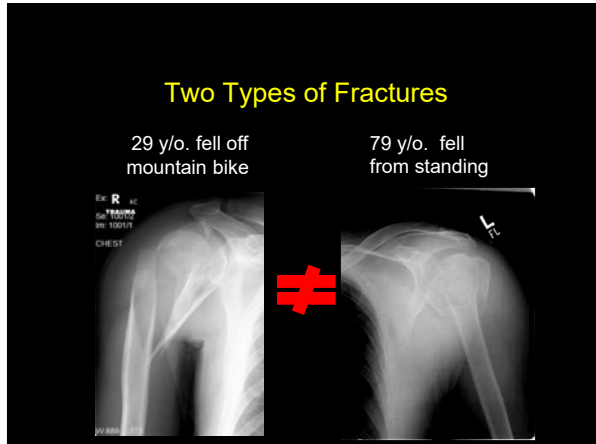
Young, active patients (25%)

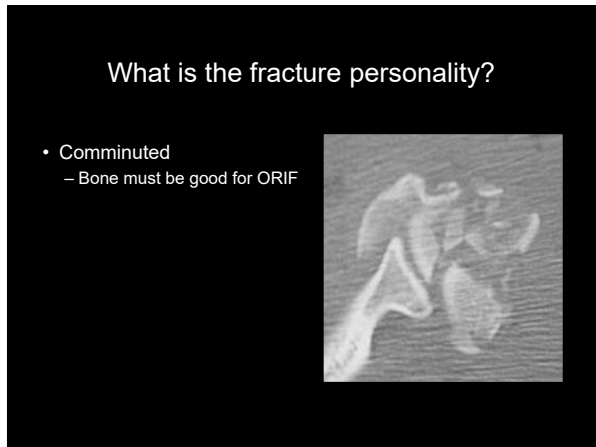- High energy injuries
 - Polytrauma
- Good bone quality but.....
 - Complex patterns
 - Soft tissue injury

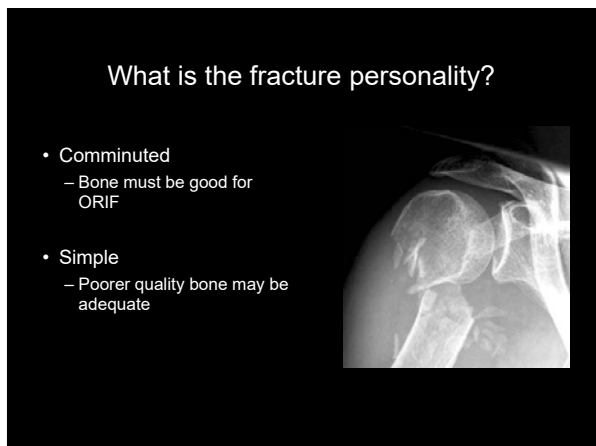

Elderly (75%)

- Low energy falls
- Poor bone quality
- Females 3 times more than Males









What is the fracture personality?

- Head viable?
 - Medial hinge intact



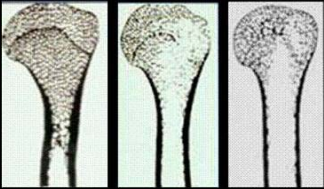
What is the fracture personality?

- Head viable?
 - Medial calcar



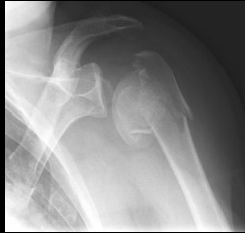What will the bone tolerate?

- Osteopenic bone pronounced in the humeral head
- Implant anchorage compromised



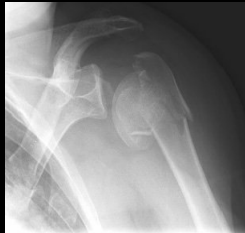Identify Factors That Determine Outcome

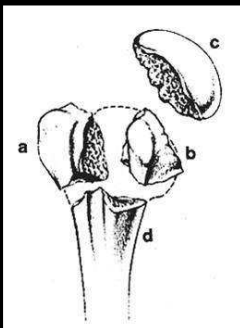
- Vascularity (AVN risk)
- Malreduction
 - Tuberosity displacement
 - Varus angulation



Identify Factors That Determine Outcome

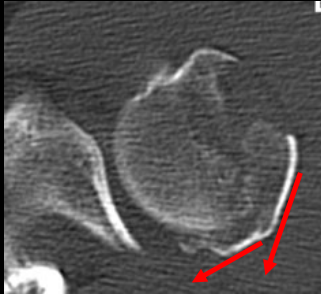
- Vascularity (AVN risk)
- Malreduction
 - Tuberosity displacement
 - Varus angulation
- Fixation failure
- Poor function



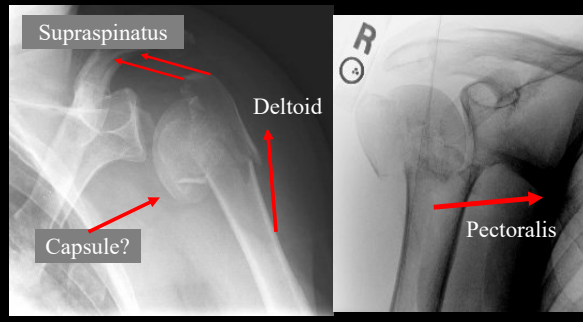


Fracture Morphology

Deforming Forces

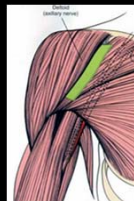


Deforming Forces

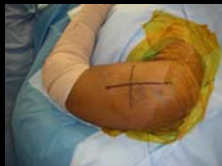

Surgical Approaches

- Deltopectoral
 - Traditional
 - Familiar

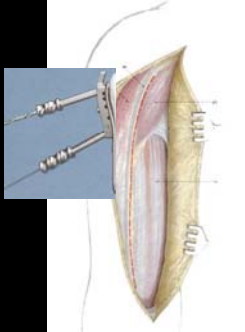


- Anterolateral acromial
 - Incision from anterolateral corner of acromion distally down shaft



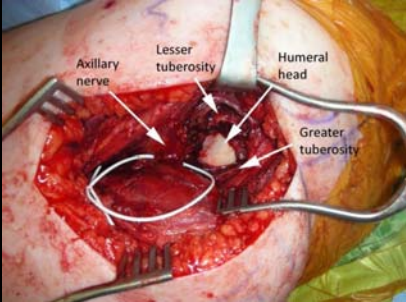
Deltopectoral

- Extensile
- Rotator Interval
- Head reduction and visualization



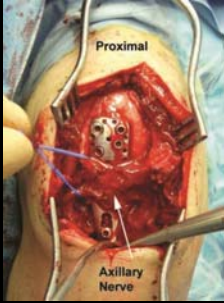
- Anterior approach for lateral plate
- Poor GT access

Anterolateral Acromial Approach



Anterolateral: issues

- Non extensile
- Axillary nerve
- Articular visualization

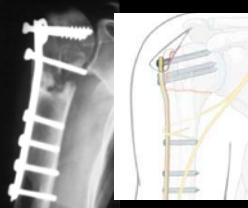


ORIF Indications

- Displaced GT fx (> 5 mm)
- Lesser tuberosity fragment with articular involvement
- Unstable or significant displacement of the surgical neck
- Displaced anatomic neck fx in young pt.
- Displaced, **reconstructible** 3- and 4-part fractures
- Open fracture

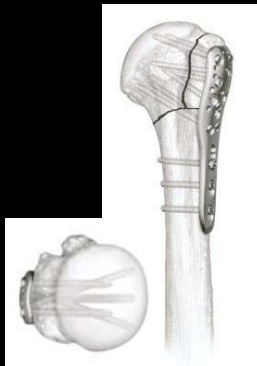Plate Fixation Non-Locking plates

- Poor results in osteopenic bone
- Proximal humerus is cancellous bone
- Still an option in selected fractures
 - Medial Stability
 - Used as a buttress



Locked Proximal Humerus Plate


- Locked internal fixator
- Angular stability
- Bi-directional screws
- Increased pullout strength
- Osteoporotic bone
- Suture attachment of Cuff



ORIF Steps

ORIF Step 1


- Mobilize/ control tuberosities
– Sutures in cuff



Courtesy of M Gardner

ORIF Step 1


- Mobilize/ control tuberosities
– Sutures in cuff



Courtesy of M Gardner

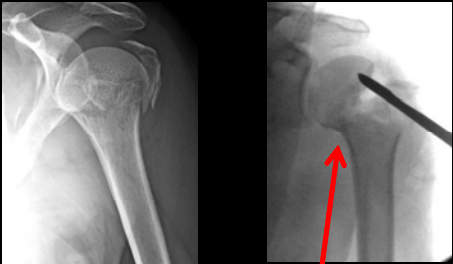
ORIF Step 1

- Mobilize/ control tuberosities
 - Sutures in cuff
 - Reduction
 - Fixation



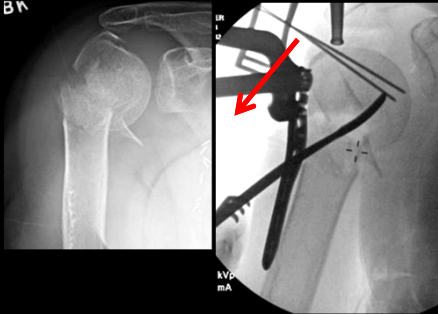
Courtesy of M Gardner

Step 2: Reduction - valgus



Adduct Arm Hinge

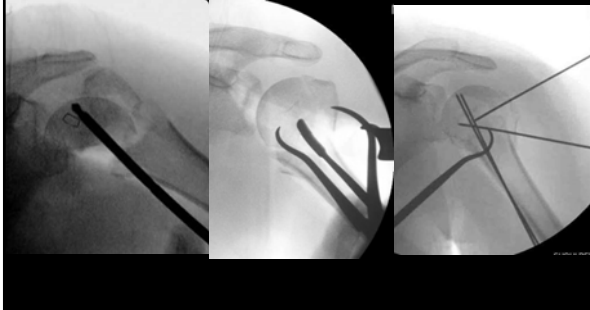Step 2: Reduction - varus



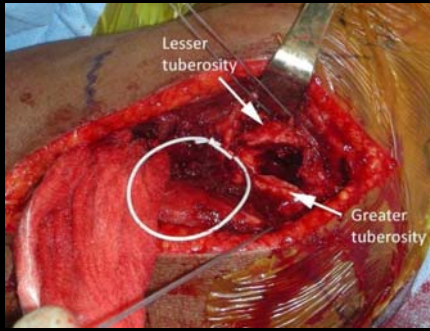
B N

1. K-wire joysticks
2. Cuff sutures
3. Elevator
4. Arm abduction

Step 2: Restore articular surface

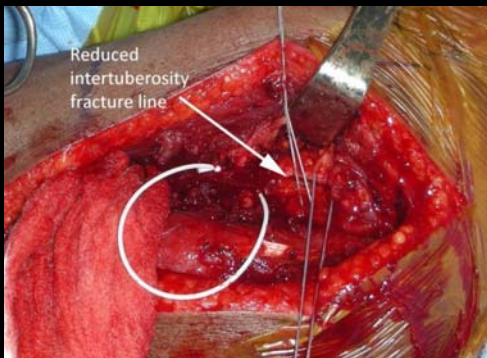


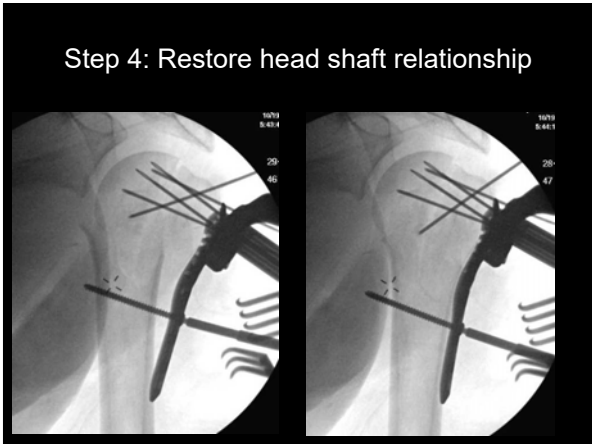
Step 3: Reduce tuberosities



Courtesy of M Gardner

Step 3: Reduce tuberosities





Medial calcar support

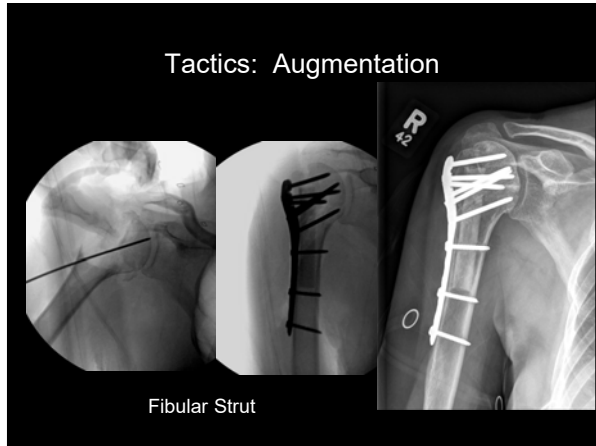
- Reduction of medial cortex (competent) **OR**
- Shaft medialized w/ impacted head **OR**
- Locking screws inferomedially in the humeral head fragment

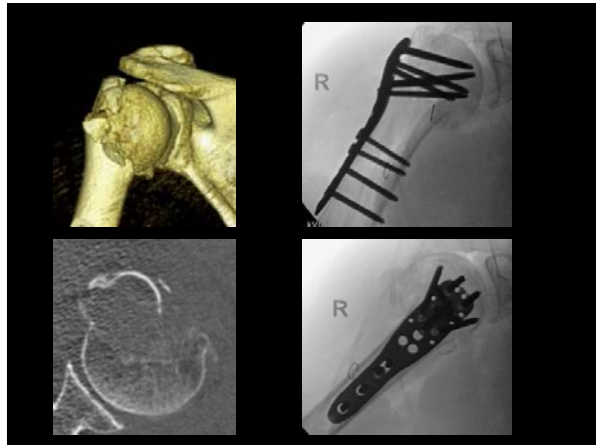
Significantly less reduction loss

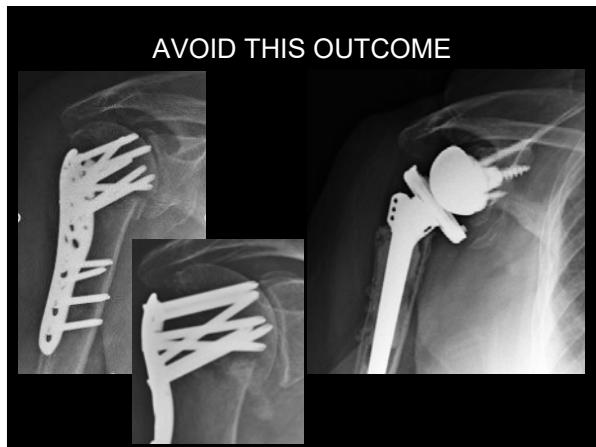Gardner MJ, et al, JOT 2007

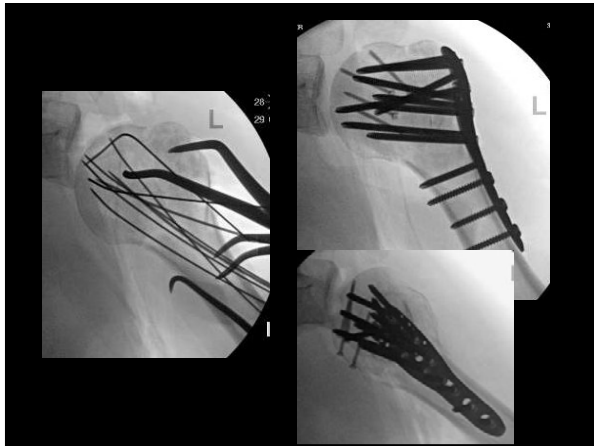
Tactics: Augmentation

- Soft tissue reinforcement
- Soft tissue preservation
- Pass sutures through plate











Take Home Points

- Bone quality primary factor in treatment decisions
- Understand and counteract deforming forces
- Step by step approach to exposure, reduction and fixation
